SAUNDERS'

MEDICAL HAND-ATLASES.

THE series of books included under this title are authorized translations into English of the world-famous

Lehmann, Medicinische Handatlanten

[illegible] translation and reproduction, including international distribution, the publishers have been enabled to secure for these atlases the **best artistic and professional talent,** to produce them in the **most elegant style,** and yet to offer them at a **price heretofore unapproached in cheapness.** The great success of the undertaking is demonstrated by the fact that the volumes have already appeared in **nine different languages**—German, English, French, Italian, Russian, Spanish, Danish, Swedish, and Hungarian.

The same careful and competent **editorial supervision** has been secured in the English edition as in the originals. The translations have been edited by the **leading American specialists** in the different subjects. The volumes are of a uniform and convenient size (5 × 7½ inches), and are substantially bound in cloth.

(For L[illegible] cover.)

Pamphlet [illegible]lored Plates

W. OPHULS.

ATLAS AND EPITOME

OF

SPECIAL PATHOLOGIC HISTOLOGY

BY

DOCENT DR. HERMANN DÜRCK

ASSISTANT IN THE PATHOLOGIC INSTITUTE; PROSECTOR TO THE MUNICIPAL HOSPITAL L. I. IN MUNICH

AUTHORIZED TRANSLATION FROM THE GERMAN

EDITED BY

LUDVIG HEKTOEN, M.D.

PROFESSOR OF PATHOLOGY IN RUSH MEDICAL COLLEGE, CHICAGO

CIRCULATORY ORGANS; RESPIRATORY ORGANS GASTRO-INTESTINAL TRACT

WITH 62 COLORED PLATES

PHILADELPHIA
W. B. SAUNDERS
925 WALNUT STREET
1900

PRESS OF
W. B. SAUNDERS, PHILADA.

EDITOR'S PREFACE.

THE objects of this book are well set forth in the author's preface, and it has been a pleasure to aid in placing the work within the easy reach of the vast army of medical students in America. Two more volumes follow shortly, one completing special pathologic histology, the other dealing with general pathologic histology. The few notes I have added are inclosed in brackets.

LUDVIG HEKTOEN.

AUTHOR'S PREFACE.

SINCE Virchow showed that what we call "disease" depends on disturbances of cell-life, our conception of the nature of pathologic processes has come to rest on the knowledge of the changes that occur in the elementary constituents of the organism.

Pathologic histology alone can make it clear to us why the morbid changes in a given case necessarily assume the appearances presented at the postmortem table; and in many instances pathologic histology is the first to reveal the reasons for the suspension or alteration of the functions of an organ.

As pathologic anatomy has become the teacher of clinical medicine in general, so it also has become inseparable from the study of the microscopic tissue changes or pathologic histology.

It is no easy task for the beginner to select among the many changes those that are typical of a certain process, and to determine the causal relations between the microscopic and macroscopic, but, having mastered the essence of a disease as shown in its characteristic changes in the elementary constituents of the body, it no longer becomes

difficult to understand the changes visible to the naked eye.

To further the knowledge of the microscopic changes produced by disease is the object of the present "Atlas and Epitome." This statement at once makes it clear that its use will yield good results only when combined with the study of preparations under the microscope. Never will he who shuns the postmortem room acquire a conception of pathologic anatomy; and it is no less impossible to master pathologic histology without direct microscopic study.

If the work, whose first volume this is, proves a trusty guide in this study, as an adjunct to other instruction, stimulating and leading the beginner to personal and exact microscopic observations, then its object will be attained.

All the illustrations have been drawn by C. Krapf from my own preparations. The magnification has been calculated by means of the stage micrometer, due regard being paid to the level of projection.

Naturally, I have attempted to secure the most typical pictures of the various processes, but in no case has it been sought to do this by a schematic representation; even the "combination" of various areas in one or more preparations has been avoided in the interests of absolute exactness.

HERMANN DÜRCK.

LIST OF ILLUSTRATIONS.

CONTENTS.

PATHOLOGIC HISTOLOGY.

I. THE ORGANS OF CIRCULATION.

HEART.

The heart-wall consists of three layers: the epicardium, myocardium, and endocardium. The epicardium (visceral portion of the pericardium) is composed of connective-tissue fibers, and is covered on its outer surface by flat, irregular, polygonal epithelium. [Throughout this book the word epithelium is used in the morphologic sense.] Underneath the epicardium lies, normally, at various places a distinct layer of fat-cells. The elastic fibers of the auricular epicardium are lost in the adventitia of the larger venous trunks.

The myocardium is made up of short, cylindric, transversely striated muscle-cells. As in the voluntary muscles, they consist of isotropic and anisotropic transverse bands, which alternate. The protoplasm is divided into a peripheral, longitudinally striated, fibrillar substance and a central portion—the sarcoplasm. In the latter lies the oval, vesicular nucleus, around which is usually seen a small deposit of fine, granular, brownish pigment. A cell-membrane—the so-called sarcolemma—is absent in the heart-muscle of man. Many muscle-cells are united with one another through oblique and transverse branches.

The endocardium is composed, like the epicardium, of

an avascular connective-tissue membrane, containing, especially in the auricles, a great number of elastic elements with a few smooth muscle-fibers. It is lined on its inner surface by a layer of polygonal, flattened epithelium. The heart-valves are reduplications of the endocardium with strongly developed elastic fibers. Blood-vessels are not found normally in the valves of the full grown; in the case of the auriculoventricular valves, blood-vessels reach to the bases.

In the fetus, however, as well as in the new-born, the leaflets are richly supplied with blood-vessels up to their free borders. Along the lines of closure the connective tissue is soft and myxomatous, and is composed of numerous stellate cells which anastomose with one another. Here are formed the fetal, gelatinous nodules which sometimes are mistaken for endocardial inflammatory processes. Later, the blood-vessels disappear, and the gelatinous nodules are transformed into fibrous nodules, which are never missed at the borders of the tricuspid and mitral leaflets. (Plate 5, Fig. I.)

Diseases of the Heart-muscle.

In the course of the acute general infectious diseases (sepsis, typhoid, diphtheria, scarlatina, variola, etc.) there occurs quite frequently in the myocardium an albuminous degeneration, or so-called cloudy swelling, as is the case in the large parenchymatous organs. Microscopically, the fresh preparations show enlargement of the individual muscle-cells. The cement lines appear more distinctly and are broader than normal, while the nuclei and the transverse striæ are indistinct or entirely obscured. The protoplasm contains an enormous number of very fine granules, of a dust-like, opaque, grayish appearance. On the addition of weak solution of acetic acid this cloudiness immediately clears up, owing to the transformation

of the albuminous granules into acid albumin, which becomes dissolved in the residual acid. The striations and nuclei now become distinctly visible. In stained preparations this cloudy swelling is not seen.

Cloudy swelling is frequently a forerunner, or intermediate stage, of a more deep-seated degenerative process of the heart-muscle—namely, fatty degeneration. This may occur independently of cloudy swelling. It may be either circumscribed or diffuse. Usually, it is found in patches in the form of wavy lines, parallel with the longitudinal axis of the muscle-bundles, giving the muscle an appearance similar to that of a tiger's skin, the degenerated areas appearing light in color. Fatty degeneration may result from local disturbance of nutrition, such as may follow narrowing or occlusion of the coronary vessels, or from the pressure of pericardial exudate. It may occur from acute intoxications: the most important toxic agents in this respect are phosphorus and arsenic; less frequently, chloroform, ether, and alcohol; and it is found quite frequently also in the course of the acute infectious diseases, through the action of bacterial toxins; furthermore, in all diseases that lead to a diminution or destruction of the blood, such as pernicious anemia and the severer forms of leukemia. Microscopic examination of fresh preparations will show that the muscle-cells are filled with fine, round, highly refractile globules, which are arranged parallel with the longitudinal fibrils, and which may completely cover the nuclei as well as the transverse striæ. On the addition of acetic acid or potassium hydrate the granules do not become dissolved, showing that they are fat-globules. In long-standing and severe cases the individual droplets run together, forming large drops. The fat-globules are easily pressed out of the cells, after which are seen only their shadows or outlines in the cell. In the latter the transverse striæ are completely lost; the longitudinal striations, however, may still be present.

PLATE 1.

FIG. I.—**Fatty Degeneration of the Heart-muscle in Acute Pernicious Anemia.** Fresh teased preparation. × 340. In the center are seen muscle-fibers totally filled with fat-globules; the fibers are partly ruptured. Transverse striations are not discernible. Above and to the left a fiber is seen, out of which the fat-globules are partly extruded; here the longitudinal striation is still noticed. Free, large fat drops are seen; below and to the right, several slightly degenerated fibers still containing transverse striæ.

FIG. II.—**From the Same Case.** Frozen sections of a papillary muscle of the mitral valve. Stained with sudan III. × 340. The fat-droplets are stained orange-red. Here and there are seen the degenerated areas; above and to the right, almost normal muscle-fibers.

In frozen preparations stained with sudan III the degenerated areas are well differentiated from the normal striated muscle-fibers.

Fatty degeneration must not be confounded with increase of fat in the normal subepicardial fat-layer—adipositas cordis or obesitas, also known as lipomatosis cordis; here the fat does not appear in globules, but as distinct fat-cells and as an independent tissue. It infiltrates the heart-wall in clusters, extending toward the endocardium. In severe cases it appears especially over the right ventricle and below the endocardium. The musculature becomes compressed, pushed aside, is frequently atrophied, and substituted by fat. The muscle-fibers may decrease to one-half or two-thirds their normal size; the striations, however, being well preserved. At times, especially in corpulent individuals, it is very hard to distinguish between physiologic and pathologic infiltration or deposition of fat. Usually, the finding of atrophied muscle-bundles between rows of fat-cells will differentiate these conditions.

A quite common, almost physiologic, condition, found in advanced age, is brown atrophy of the heart-muscle.

Tab. 1.

Fig. 1.

Fig. 2.

Lith. Anst. F. Reichhold., Mü

It also occurs in young individuals suffering from exhaustive diseases with general marasmus. The muscle-fibers appear more or less diminished in size, oftentimes to a considerable degree, and their striations are indistinct or have entirely disappeared, while the nuclei may have become flattened. Around the latter are found masses of amorphous, finely granular, yellowish-brown pigment. In severe cases the cells are completely filled with this pigment, or the pigment may be found free between the fibers, owing to the destruction of the cells. In cases not so far advanced transverse sections will not always show pigment in each individual cell, for the reason that the groups of pigment particles, like the nuclei, are found only at certain planes; fat-vacuoles are sometimes seen in the sarcoplasm at the same time. The pigment gives no iron reaction, and it is undoubtedly related to the pigment normally found in the heart-muscle.

In severe cases of general amyloid disease there is sometimes found in the myocardium amyloid degeneration of the blood-vessels of the intermuscular connective tissue. Hyaline degeneration may also be observed in the intermuscular connective tissue.

[Among the degenerative changes of the myocardium should be mentioned segmentation, or separation of the muscle-fibers along the cement lines into the individual cells that compose the fibers; and fragmentation, or the breaking of the fibers into fragments irrespective of the cement lines. These changes are terminal or agonal events in diseases of various kinds, and are found to a greater or less degree in about two-thirds of all hearts examined.]

Circulatory Disturbances of the Myocardium.

Embolism, Infarction.—Embolism of the coronary arteries of the heart occurs but infrequently, as the result

PLATE 2.

FIG. I.—**Adipositas Cordis.** Frozen section. Stained with hematoxylin and sudan III. ×80. 1, Transversely striated muscle-fibers, pressed together, diminished in size, and continuity interrupted; 2, fat-cells in rows between the muscle-fibers.

FIG. II.—**Brown Atrophy of the Heart-muscle in Longitudinal Section.**

FIG. III.—**The Same in Transverse Section.** ×340. In the muscle-cells are seen masses of brownish, amorphous pigment. In the transverse section are seen round vacuoles in the sarcoplasm.

---

of detached pieces of thrombi or endocardial vegetations being swept into those vessels. Provided sudden death by obstruction of a larger stem does not occur, the results are anemic infarct; since the coronary arteries are, in the sense of Cohnheim, end arteries—in other words, do not form collaterals. The whole infarcted area undergoes anemic necrosis. Through coagulation of the albuminous substances, the area presents a homogeneous, dry, firm consistency, while the contours of the cells and transverse striæ of the muscle-fibers disappear, and the nuclei do not stain. Later, the musculature breaks up into a granular substance. The infarct, like necrotic tissue in general, acts upon the neighboring tissue as an inflammatory irritant, which causes the accumulation of numerous round cells, lymphocytes, and leukocytes around the periphery of the infarct, forming a compact wall. At this stage softening may take place in the infarct as the result of an infiltration of serous fluid throughout the area, the fluid being transuded from the surrounding blood-vessels that are in a state of stasis (Neelsen). This condition is designated as myomalacia cordis. The softened tissue can not, when extensive, withstand the blood pressure, a local bulging occurs, and an aneurysm of the heart develops.

It is much more common to observe that shoots of new

Tab. 2.

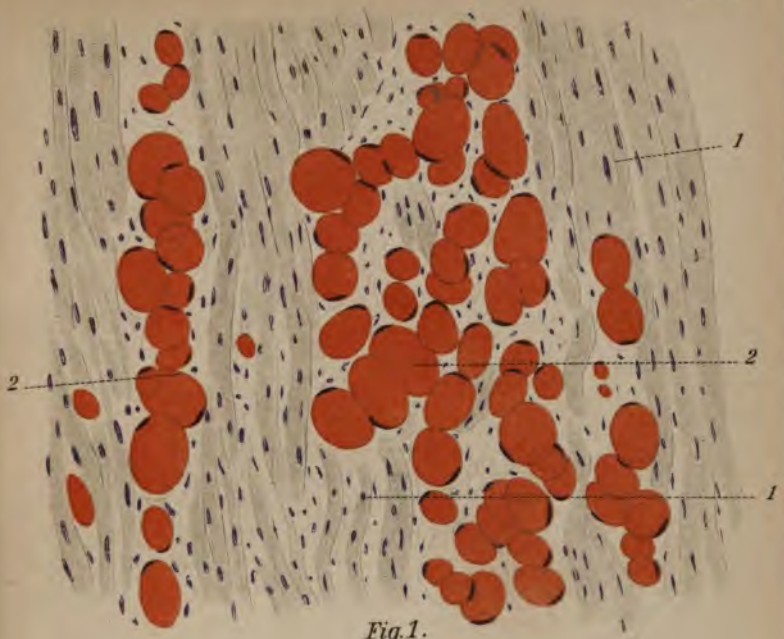

Fig. 1.

Fig. 2.

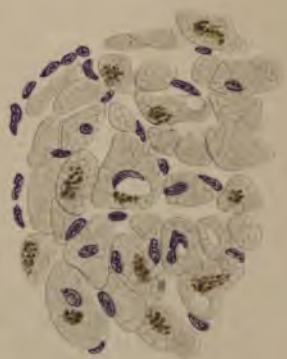

Fig. 3.

Lith. Anst. F. Reichhold., Mi

blood-vessels and proliferative connective-tissue cells grow into the periphery of the infarct, which becomes gradually infiltrated with granulation tissue—that is to say, the infarct becomes organized, the necrotic muscle-tissue is substituted by a connective tissue at first richly cellular and vascular. (Plate 3, Fig. I.) Later, the blood-vessels disappear through obliteration, and the large, plasmatic, "epithelioid" fibroblasts give way to small spindle-shaped cells and long connective-tissue fibers. Minute extravasations of blood lead frequently to a deposit of brownish pigment. In this way the infarcted area is gradually replaced by a connective-tissue scar, which is outlined from the surrounding muscle-tissue by an irregular line. Myocardial scars may also develop in another way, which will be described later.

Embolism takes the course previously described when the embolus acts in a purely mechanical way. Should, however, the embolus contain micro-organisms, as in the case of pyemia or mycotic ulcerative endocarditis, then acute inflammatory changes ensue, and there results an embolic abscess. (Plate 3, Fig. II.) Microscopically, we find in the center of the latter staphylococcal or streptococcal masses, as well as fragments of necrotic muscle-tissue, the nuclei and striæ of which have disappeared. In the early stages the coccal emboli are still seen inclosed within the blood-vessels. Naturally, the walls soon break down, and the bacteria then lie free in the tissue. They are usually surrounded with numerous leukocytes with lobulated and fragmented nuclei. The muscle-tissue at this area has entirely disappeared. Around the margin of the abscess the leukocytes may be seen as irregular shoots into the intermuscular connective tissue. Sometimes the abscess undergoes healing; this takes place when the bacteria do not flourish, but undergo destruction. The pus-cells break down through fatty degeneration, and the contents of the abscess are then entirely absorbed, while from the per-

PLATE 3.

FIG. I.—**Infarction of the Heart-muscle, Organizing.** ×70. 1, Heart-muscle still containing nuclei; 2, young connective-tissue cells growing into the infarcted area, and infiltrated with numerous small flakes of brownish pigment; 3, new shoots of blood-vessels; 4, necrotic heart-muscle.

FIG. II.—**Embolic Abscess in a Papillary Muscle of the Mitral Valve in Septicopyemia.** Stained by Gram's method. 1, Heart-muscle infiltrated with small round cells; 2, abscess cavity filled with leukocytes; 3, colonies of cocci in the center of the neighboring abscesses; 4, remains of necrotic muscle-cells.

---

iphery granulation tissue grows into the cavity, which is finally replaced by scar tissue, as described in simple infarction. In this way also myocardial scars are formed.

Besides the previously described form of myocarditis which leads to such rapid softening of larger or smaller areas of muscle-tissue, there occurs another form, the real interstitial myocarditis. The latter is not circumscribed, but more diffuse in character, and is not accompanied by direct necrosis. Apart from the processes in the endocardium which may extend directly to the heart-muscle, this form is principally observed in connection with the acute general infectious diseases. Through the action of bacterial products or toxins, there is produced first nutritional disturbances and later inflammatory changes. Primarily, we find in these forms quite frequently such degenerative changes of the muscle-fibers as cloudy swelling, areas of fatty degeneration, vacuolations, and transverse tears of the cement lines—the so-called "myocardite segmentaire" of Renaut. [Segmentation and fragmentation of the heart muscle-fibers are of common occurrence. The existence of a distinct form of segmentary myocarditis, as claimed by Renaut, has not been established. Segmenta-

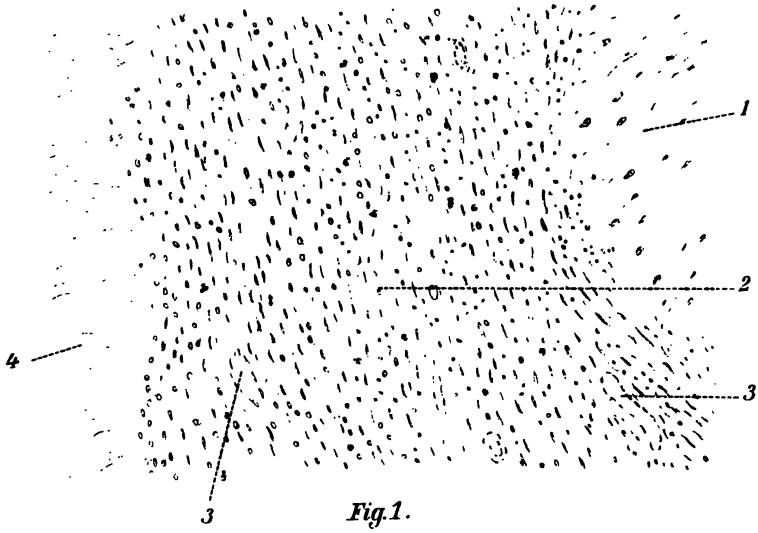

Fig. 1.

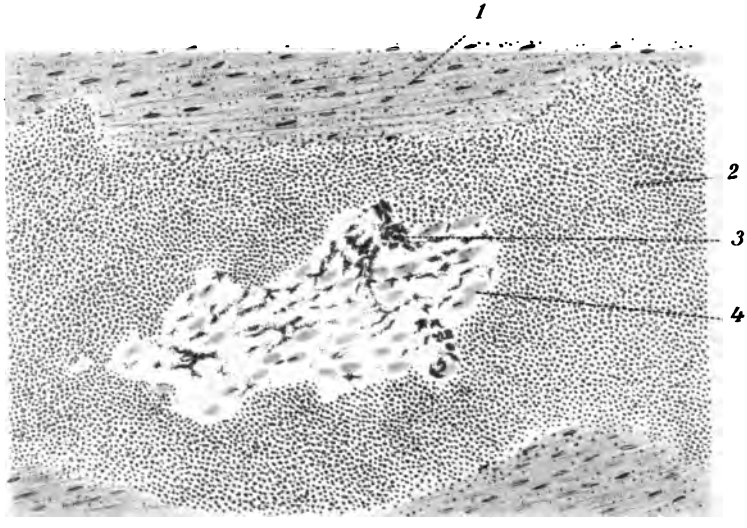

Fig. 2.

Lith. Anst. F. Reichhold, München

tion appears as a terminal or agonal event in various diseases not necessarily involving the myocardium primarily.] The transverse striations may be absent over large areas, while the nuclei also show changes. (Plate 4, Fig. I.) Here and there the nuclei are found increased in numbers, so that in a single muscle-cell several nuclei occur in rows; or they are found enlarged, ballooned, with a loose chromatin network. Through disintegration of the cells part of these nuclei become free. The most striking changes, however, are observed in the intermuscular connective tissue. The fixed connective-tissue cells proliferate and produce fibroblasts—large spindle-shaped or round, plasmatic cells with vesicular nuclei. These accumulate especially around the blood-vessels, forming numerous foci, while the surrounding muscle-tissue disintegrates more and more.

Gradually, these areas are transformed into fibrous scars, which remain after the inflammatory processes have subsided. In this manner various sized scars are developed without necessarily being preceded by infarction or necrosis of muscle-tissue, which, as it degenerates, is substituted by fibrous tissue. Myocardial scars, therefore, may develop in three ways: After infarction, after healing of an abscess, and as a termination of acute interstitial myocarditis (Plate 4, Fig. II); but their genesis is not yet exhausted, inasmuch as focal disappearance of muscle-substance, accompanied with chronic proliferative changes of the interstitial connective tissue, occurs in all cases of narrowing of the coronary arteries in endarteritis and arteriosclerosis—chronic fibrous myocarditis or arteriosclerotic myocarditis.

Infectious new growths, as syphilis and tuberculosis, are rare in the heart-muscle, but occasionally are observed. They do not present any special histologic peculiarities.

PLATE 4.

FIG. I.—**Acute Interstitial Myocarditis.** ×300. The transverse striæ of the muscle-fibers are obliterated in places, their nuclei increased and swollen, and partly rounded in shape.

Between the muscle-fibers are seen (1) small round cells, lymphocytes and leukocytes, (2) also young connective-tissue cells (fibroblasts).

FIG. II.—**Chronic Fibrous Myocarditis.** ×80. 1, Heart musculature; 2, long connective-tissue fibers between the muscle-bundles, containing but very few nuclei and blood-vessels.

Endocardium.

Inflammation of the endocardium is usually localized upon the valves of the heart, and especially upon those of the left side, because their exposed position and peculiarity of function render them liable to the primary and most intense action of the infectious agents. It has, therefore, become customary to apply the term endocarditis to an inflammation of the valves of the heart, while the much rarer inflammation of the mural endocardium is generally designated as mural endocarditis. According to the views now current, all forms of acute valvular endocarditis are considered as infectious diseases—that is to say, as due to the action of micro-organisms—while the slow, chronic, and sclerotic forms are due to atheromatous and arteriosclerotic changes in the intima of the larger vessels that spread to the valves, especially to the aortic valve and the aortic curtain of the mitral valve.

It is customary to distinguish two varieties of acute endocarditis—the verrucose or rheumatic (sometimes designated as benign) and the ulcerative or diphtheric (also malignant) form. This classification may be retained, provided gradual and quantitative, and not essential and qualitative, differences are thereby understood. Quite frequently, wart-like vegetations and ulcerative changes

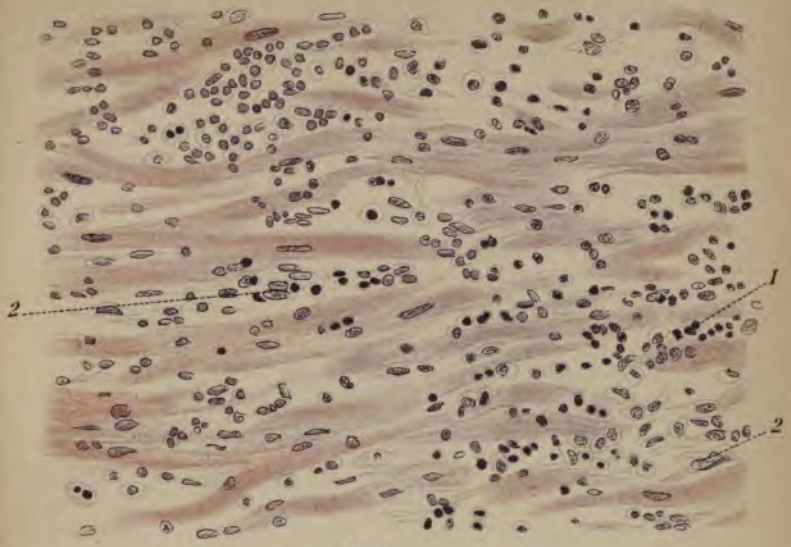

Fig. I.

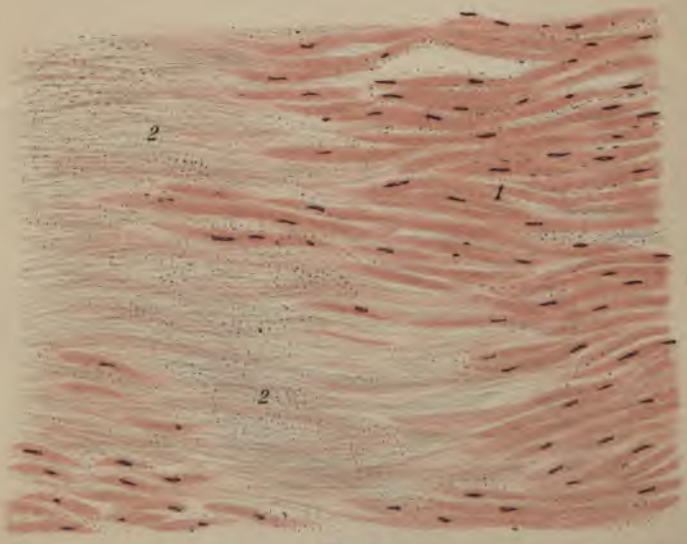

Fig. II.

Lith. Anst. F. Reichhold., Mü

occur at the same time; they either develop simultaneously, or ulceration is established in a valve the seat of warty outgrowths. Both forms occur primarily as the result of minute lesions of the endocardium, which, in turn, are due to the action of micro-organisms. The organisms either accumulate directly on the valves from the blood, or act on the endothelial lining by their toxins, causing minute necrosis on the basis of which other inflammatory changes develop.

In all cases of endocarditis two groups of processes occur — namely, inflammatory and thrombotic; at first distinct, they later cooperate in producing the so-called endocardial vegetations or efflorescences. The inflammatory process runs its course in the substance of the valve, and the thrombi are deposited from the blood upon the diseased valve.

Verrucose endocarditis is characterized by the formation upon the valves, at their lines of closure, of either single or rows of wart-like excrescences, which later in their course usually become organized—that is to say, are transformed into connective tissue. (Plate 5, Fig. II; Plate 6, Fig. I.) At first there are small defects of the endothelium, followed by proliferation and hyperplasia of the fixed cells of the underlying connective tissue of the valve. From the latter develop strings and groups of spindle-shaped, polygonal, and round cells,—so-called fibroblasts,—among which lie single small round cells. Occasionally, micro-organisms accumulate upon the surface of these cellular nodules, either singly or in small masses. At the border of the proliferating zone are seen, embedded in the normal connective tissue, single, large, star-shaped, richly protoplasmic cells with oval and vesicular nuclei, evidently formed by mitosis from small, spindle-shaped, connective-tissue cells. Before long there is deposited upon the surface of these cellular nodules constituents of the blood, because of the endothe-

PLATE 5.

FIG. I.—**A Normal So-called "Fetal Gelatinous Nodule" at the Line of Closure of the Mitral Valve of the New-born.** × 70. The connective tissue is very cellular; ground substance partly myxomatous in character; in it are seen (1) a number of thin-walled blood-vessels.

FIG. II.—**A Section of an Acutely Inflamed Mitral Leaflet in Mycotic Endocarditis.** × 80. 1, Necrotic tissue of the leaflet; 2, new formed blood-vessels growing into the connective tissue. Between the spindle-shaped, connective-tissue cells are seen many large protoplasmic epithelioid cells.

---

lial defects which incite thrombotic precipitation. Usually, a clear, finely granular mass of closely packed conglutinated blood-plates is deposited directly on the cells; over this layer there forms a fibrinous network or clumpy masses appear, which inclose leukocytes. Upon the surface of this irregularly shaped vegetation a thin cluster of leukocytes and bacteria in various numbers also accumulate.

In the subsequent course of verrucose endocarditis organization of the thrombotic deposit, which leads to healing, takes place. From the attachment of the valves blood-vessels grow between the connective-tissue lamellæ toward the excrescences; they send numerous shoots between the fibroblasts toward the thrombotic mass. (Plate 6, Fig. I.) These consist at first of extraordinarily fine, solid processes, which later become hollow and filled with red blood-corpuscles. Gradually, the thrombotic mass becomes completely infiltrated with granulation tissue, which is made up of fibroblasts, small round cells, and blood-vessels. Later, this richly cellular and vascular granulation tissue is transformed into fibrous scar tissue, in which single blood-vessels may remain present for some time. In this manner are produced nodular and diffuse thickenings of the valves. Sometimes these processes of

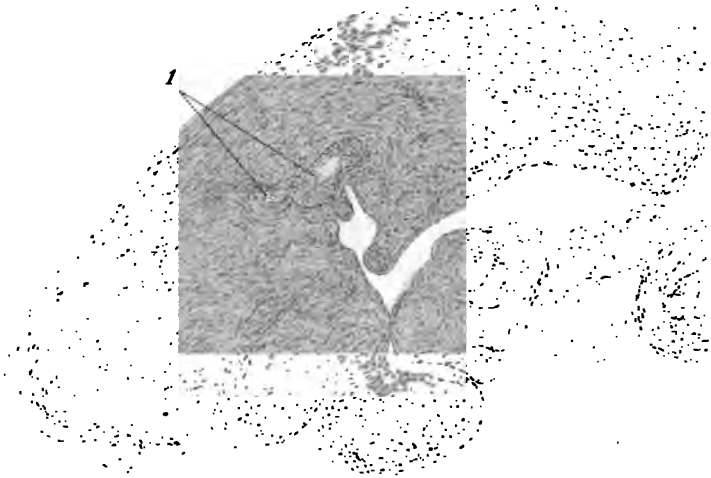

Fig. 1.



Fig. 2.

Lith. Anst. F. Reichhold, Münc

healing lead to various changes in the form of the valves, which produce valvular insufficiency; or the new tissue may cause the valves to become adherent to each other and thus produce narrowing or stenosis of the orifice. Subsequently, lime salts may be deposited upon the sclerosed tissue in the form of irregular and ridge-like projections.

Ulcerative endocarditis in the early stages can not be distinguished from the verrucose, except that almost from the very first micro-organisms are present in much greater numbers and are demonstrable in the form of dense, dark balls or masses of micrococci. The further differences of the course depend upon the specific action of the microbes, which, on the one hand, is essentially chemotactic, and, on the other, necrotic. We find the connective-tissue lamellæ of the valves infiltrated to a considerable extent with leukocytes, which in places are so dense that there result minute abscesses in the valvular tissue with softening of the fibers. In the neighborhood of the masses of cocci the tissue does not stain nor does it contain nuclei —it is necrotic. This zone is marked off from the surrounding tissue by intense aggregations of leukocytes.

Suppuration and necrosis lead to more or less extensive destruction, to ulceration, and to loss of continuity in the inflamed valve. The latter may become perforated, and after complete necrosis and suppurative softening whole fragments may be detached and swept into the blood-stream. Hence, this malignant type of endocarditis usually leads to a fatal end, because metastatic abscesses develop in various organs of the body through the process of embolism; and, moreover, the individual becomes profoundly affected by the toxic action of the ever multiplying bacteria.

The micro-organisms observed in verrucose and ulcerative endocarditis are the staphylococci, streptococci, diplococci pneumoniæ, and, in rare cases, the gonococci.

PLATE 6.

FIG. I.—**Acute Verrucose Mycotic Endocarditis of the Mitral Valve.** Section through the valve and vegetation. Stained by Gram's method. ×16. Bird's-eye view. 1, Connective tissue of the valve; 2, a vegetation composed of conglutinated blood-cells, fibrin, and, at the periphery, aggregations of staphylococcal colonies, 3, around which leukocytes have accumulated; 4, disintegrated and partly necrotic valve tissue with infiltrated leukocytes.

FIG. II.—**Verrucose Endocarditis of the Mitral Valve, Organizing.** ×40. 1, Connective tissue of the mitral valve with increased number of cells; 2, endocardial efflorescence; 3, blood-vessels growing through the valve and penetrating into the excrescence; 4, leukocytic accumulations.

Diseases of the Pericardium.

Both layers of the pericardium are frequently the seat of inflammatory processes, which are accompanied by an outpouring of a fluid exudate into the pericardial cavity and with a deposit of fibrin upon the opposing serous surfaces. Most frequently, pericarditis results from extension of the inflammation from the pleura, the lung, the mediastinum, or also from the heart; or from metastases (embolic) in certain infectious diseases (articular rheumatism, septicopyemia), and from chemic irritants, as in uremia. In the last case micro-organisms are not met with.

Microscopically, we find in the early stages intense congestion of the pericardial blood-vessels. Sometimes the lumen of the vessel is filled with a network of fibrin or with leukocytic thrombi. At the same time, there are seen cloudiness and loosening of the endothelium, which, later, is rapidly destroyed, so that in advanced cases only fragments of endothelial cells are found in areas, mostly detached from the underlying membrane. Upon the endothelial lining, as well as below it, appear, at first, single

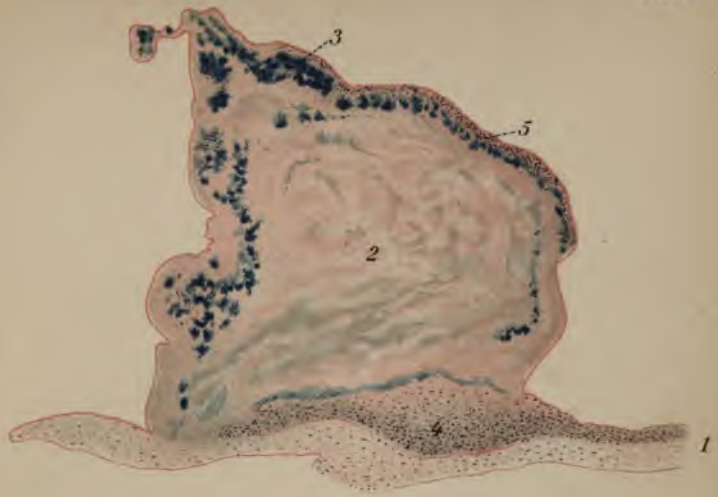

Fig. I.

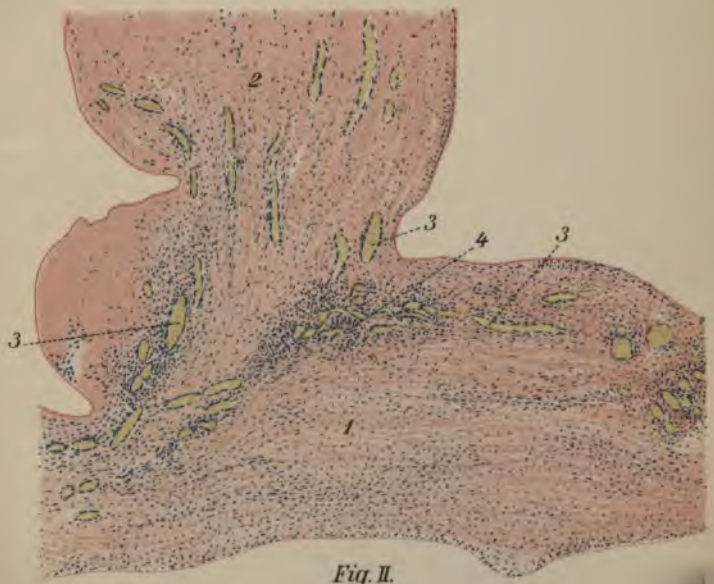

Fig. II.

Lith. Anst. F. Reichhold., Mün

threads of fibrin; later, more as an interwoven network forming a thick layer in which are inclosed varying numbers of leukocytes. The deposition of fibrin, which is the result of the exudation of plasmatic fluid from the dilated vessels followed by coagulation, may attain a considerable degree, forming a thick, reticular membrane or long, hairy-like projections upon the surface (cor villosum). (Plate 7, Figs. I and II. Compare also Plate 60, Fig. I.) In the underlying connective-tissue layer of the pericardium various cellular processes also run their course. The connective-tissue cells produce, through mitosis, short spindle-shaped or polygonal cell-elements with large vesicular nuclei (epithelioid cells, fibroblasts), while the endothelial cells of the lymph and blood-vessels also undergo proliferation. Between these appear a great number of lymphocytes and leukocytes.

Later, the blood-vessels give off sprouts, which, at first solid, become hollow and pass into the loosened and cellular layer of connective tissue and out toward the fibrin, which is gradually infiltrated with new cells and eventually completely substituted by granulation tissue. And now the new vessels gradually disappear, the cells diminish, and the granulation tissue changes into connective tissue which is at first rich in spindle-shaped cells, but later becomes more and more fibrillated at the expense of the cells.

In this way the fibrinous deposit is gradually changed into cicatricial tissue, which produces either flat, glistening, opaque thickenings in the epicardium (so-called tendinous spots, "soldier-spots"), or more or less extensive adhesions of the pericardial layers up to a complete fibrous obliteration of the pericardial cavity.

In tuberculous pericarditis the processes described—of exudation, proliferation, and organization—run their course in the same manner; but, in addition, there appear in the granulation tissue, under the fibrinous layer, typical tubercles, generally composed of radially arranged epi-

PLATE 7.

FIG. I.—**Acute Fibrinous Pericarditis (Cor Villosum).** Fibrin stain. ×64. 1, Myocardium; 2, subepicardial fat-tissue; 3, thickened and richly cellular epicardium; 4, fibrin deposit, in the meshes of which leukocytes are seen; 5, blood-vessels growing toward the fibrin and filled with leukocytes.

FIG. II.—**Fibrinous Pericarditis, Organizing.** ×127. 1, Pericardial connective tissue; 2, young, connective-tissue layer with numerous, thin-walled blood-vessels, epithelioid (fibroblasts) and round cells; 3, fibrin layer (stained red with eosin); 4, the fibrin penetrated by new blood-vessels and fibroblasts.

---

thelioid cells, giant cells, and round cells, the center early becoming the seat of caseous necrosis.

The confluence of nodules and caseous areas leads to the formation of extensive necrotic layers, which are surrounded by granulation tissue or fibrous tissue. New tubercles spring up in the young connective tissue externally, undergo the same degeneration, and become covered by a new layer of fibrin and of granulation tissue; in this way thick masses are formed, which consist of, at times, numerous alternating layers of granulation tissue and caseous and necrotic material. Usually, this process goes on in the same way in both the pericardial layers, which become firmly adherent and thus obliterate the pericardial cavity.

PLATE 8.

FIG. I.—**Subacute Tuberculous Pericarditis.** ×50. 1, Heart-muscle; 2, subepicardial fat-tissue greatly infiltrated with small round cells; 3, thickened pericardium; 4, tubercle with cheesy center and epithelioid cells arranged in a radiating manner; 5, giant cells; 6, fibrin deposit.

FIG. II.—**Sclerotic or Milk Spots of the Epicardium.** ×65. 1, Transverse section of the heart-muscle; 2, normal epicardial connective tissue; 3, layer of greatly thickened sclerotic connective-tissue fibers.

Tab. 7.



Fig. I.

Fig. II.

Lith. Anst. F. Reichhold., München.

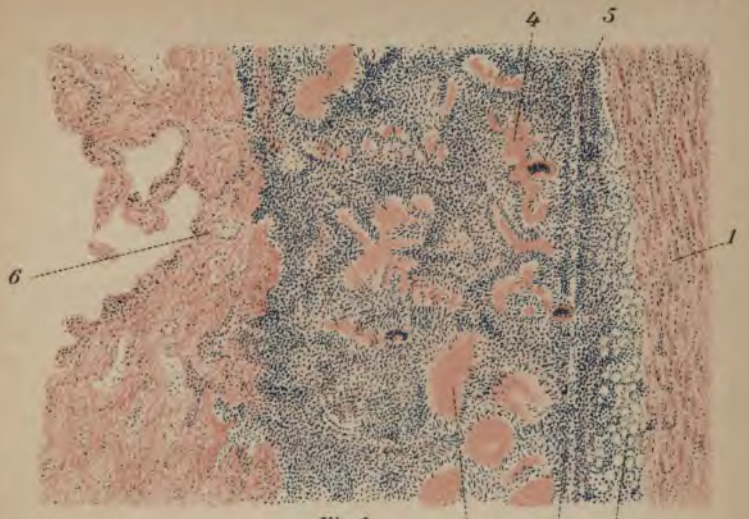

Fig. 1.

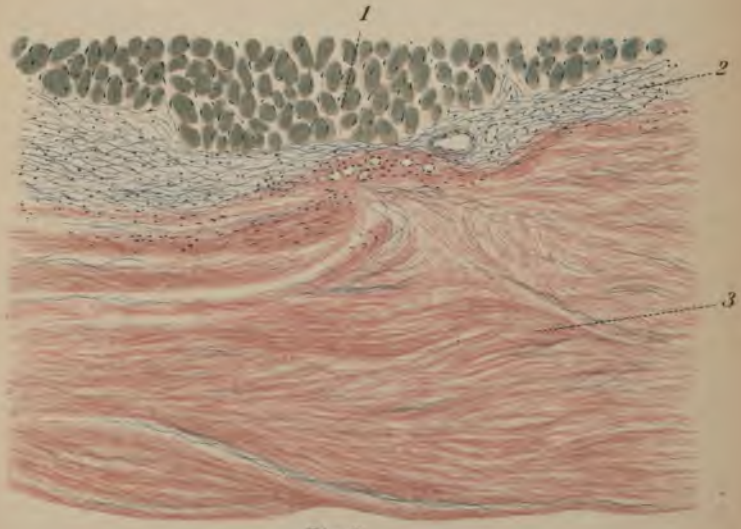

Fig. 2.

Lith. Anst. F. Reichhold, Mün

VESSELS.

The arteries present a wall in which three layers are recognizable: the internal, middle, and external coats. In all arteries the internal coat, or intima, is covered with flat, polygonal or four-sided, epithelial cells. The other layers are composed of fibrous, elastic, and muscular tissues, which reach varying thicknesses and are variously disposed according as the caliber of arteries varies. Three general groups may be distinguished: In the smallest, so-called precapillary, arteries the epithelial lining is situated upon a thin, elastic membrane, outside of which lies the media, which is composed of a single layer of circularly arranged smooth muscle-fibers. The external coat is formed of a few longitudinally disposed, connective-tissue, and elastic fibers.

In the middle-sized arteries there occurs, outside the epithelium, a layer of connective tissue made up of fine fibers, scattered among which lie flat, triangular, or stellate cells. This reinforced intima is bordered externally by the inner elastic layer, or fenestrated membrane, which is perforated by numerous round openings. The media consists of several layers of circular, muscular fibers, between which are distributed fine elastic fibers in varying numbers. Externally, also, the media is bordered by a thicker elastic membrane, the external elastic. The adventitia consists of partly circular, partly longitudinal, connective-tissue fibers, between which run occasional elastic fibers. In some arteries isolated bundles of longitudinally arranged muscular fibers are found in the adventitia. Furthermore, the adventitia supports the minute vasa vasorum.

In the large arteries (aorta, pulmonary, carotid, subclavian) all the three layers receive additional reinforcements. In the intima several layers of connective-tissue fibers, with polygonal, flat cells, and also circular elastic

fibers occur outside the epithelial lining. The internal elastic coat consists generally of several layers. In the middle coat the elastic elements are especially well developed, and consist of thick, fenestrated, elastic plates that are connected with one another by bands of fibers. In the interspaces lie the muscular fibers, which here also have a circular arrangement. The elastic membrane is not so sharply demarcated as in the arteries of medium caliber. The adventitia shows the same structure as in these, but does not contain any muscular bundles. The two inner layers of the walls of arteries consequently never contain vessels when normal; whenever such a condition exists, it is pathologic.

The veins differ from the arteries especially in the marked reduction that takes place in the middle coat. External to the epithelial lining there are, in the largest and medium-sized veins, some fibrillated connective-tissue and also, occasionally, longitudinal, muscular bundles. The internal elastic coat is distinctly marked, and consists often of several layers. The middle coat contains usually only a few circular, muscular bundles, but more elastic and connective-tissue elements, which often cross one another obliquely; in some veins—*e. g.*, the meningeal and osseous veins—the media may be entirely absent. The external tunic contains also much connective tissue, as well as many longitudinal bundles of smooth muscle-fibers, which in some veins form a continuous muscular coat. The valves in veins are formed by a duplicature of the intima.

The walls of capillaries consist only of a single layer of flat, many sided, epithelial cells.

Arteries.

Atheroma and Arteriosclerosis.—Atheroma is a disease of the vessel wall produced by a combination of processes, in part inflammatory, in part degenerative. It

nearly always begins in the intima, and leads to diffuse or circumscribed, often quite marked, thickening of this coat; eventually, the outer tunics also become involved. According to the vascular tunic affected, the process may be called endarteritis, mesarteritis, or periarteritis.

By the word atheroma, or atheromatosis, special stress is laid upon the retrogressive changes. It should, therefore, be reserved for those cases in which softening gives rise to curdy material; while arteriosclerosis is the more appropriate designation for the remaining forms. [Inasmuch as there is no distinction of fundamental import between atheroma and arteriosclerosis, and as arteriosclerosis in its broadest significance includes atheroma, there is no good reason why the term atheroma should not be discarded in the interests of simplicity and clearness.

When the process involves a medium-sized or smaller vessel of about the caliber of the basilar artery, the examination of transverse sections of the diseased vessel will show, under low magnification, that the lumen is narrow and distorted; it no longer has the normal circular form, and is not central, but eccentric; at one point, or several, the wall appears thinner; at others, considerably thicker, due to nodular or oftener to semilunar protuberances, which encroach upon the lumen. Closer examination will show that the section is surrounded by an intact adventitia of uniform thickness, and also that the media is continuous and of uniform width. Contrariwise, the intima presents marked changes, inasmuch as the halfmoon-shaped bulgings are found to be due to a large increase in its volume at these points. The internal elastic layer and the epithelium are retained only over the thin or normal portions of the wall. Where the intima begins to be thickened, it is seen that a layer of new tissue arises in the subepithelial connective tissue between the elastic membrane and the epithelial lining. The two points of the crescent

PLATE 9.

FIG. I.—**Arteriosclerosis of a Cerebral Artery (Sylvian Artery); Transverse Section.** ×75. The lumen is eccentric in outline, as a result of irregular thickening of the wall: 1, Adventitia; 2, media; 3, the internal elastic coat; at 4 the elastic layer becomes lost; 5, slightly thickened side of the intima; 6, newly formed, richly cellular connective tissue from the inner layer of the intima; 7, outer layer of the same, noncellular, containing several slit-like and rounded spaces filled with fat.

FIG. II.—**Arteriosclerosis of a Coronary Artery of the Heart; Transverse Section.** Weigert's elastic fiber stain. ×70. 1, Adventitia; 2, media; 3, internal elastic coat, at 4 becoming fibrillar and sending shoots into the newly formed connective tissue (5).

---

start here. (Compare Fig. I, Plate 9.) The new formation consists principally of connective tissue. The elastic layer may be traced for a distance into the new tissue, where it is soon lost; often the ends become distinctly split up into fibrils. The inner layers of the thickened area are relatively cellular, and contain numerous, short, dense, spindle-shaped, and also some round, nuclei. The external layers are less cellular and densely fibrillated, at times almost homogeneous; in places there are small, round, and oval openings, which in the fresh state contain fat; in the latter stages this part of the tissue generally undergoes retrogressive changes. The fibers coalesce to form uniformly glistening, thick beams, and assume a hyaline appearance, not unlike the ground substance of cartilage; small areas may become necrotic and break up into a granular detritus in which are free fat, crystals of fatty acids, and, quite generally, cholesterin tablets. Calcification frequently takes place; small, round, and irregular calcareous granules are deposited, or there arise larger calcareous scales or concentrically lamellated, roundish masses, which may so press upon the muscular coat as to *cause it to* atrophy in places.

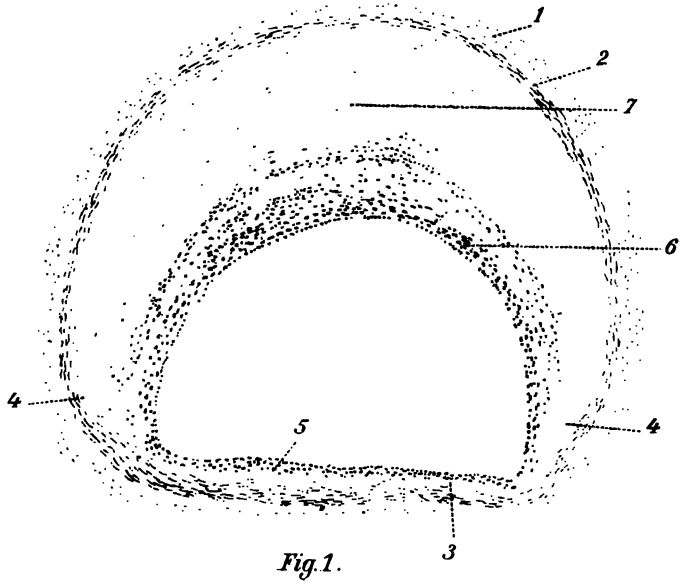

Fig. 1.

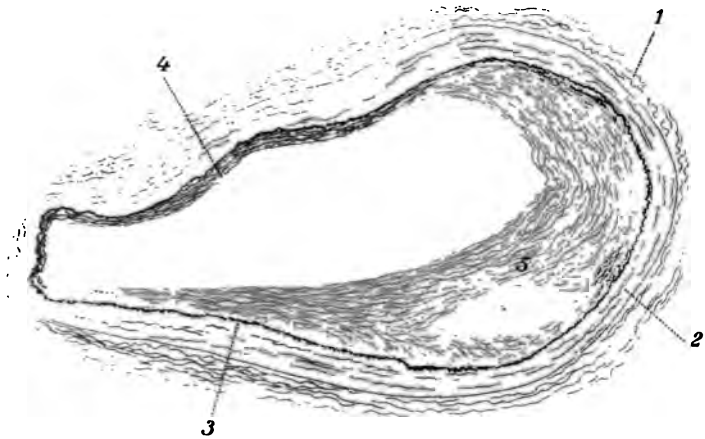

Fig. 2.

Lith. Anst. F. Reichhold, Mü

Rupture of degenerated areas into the lumen rarely occurs in the smaller arteries. The processes of connective-tissue growth and of calcification may gradually spread so as to encircle the entire lumen, and then the wall of the artery becomes changed, over a greater or less extent, into a rigid calcareous cylinder.

In the larger arteries the process differs, in so far as here the degeneration in the intima frequently appears in the foreground, while the other walls present changes of an essentially inflammatory nature. Here, also, proliferation and thickening of the normally well-developed tissue of the intima constitute the primary changes; circumscribed fibrous areas are formed, which may extend into the media and project into the lumen as nodular elevations. Over such districts the epithelium is lost early; the elastic elements are separated and split up; frequently they disintegrate throughout large areas, forming small, irregular pieces; and in the midst of the fibrous areas single fragments may be demonstrable by means of special staining methods. The part of the fibrous tissue adjacent to the lumen frequently presents a yellowish appearance. In such places thin, continuous lamellæ can be peeled off, which, if examined when fresh, distinctly show fatty degeneration of the large, flat cells they contain. Elongated, triangular, and stellate groups of closely aggregated, fine, glistening fat-drops are seen, as well as large connective-tissue cells, which become especially distinct on account of the fat in their interior. (Plate 10, Fig. III.)

Areas of necrosis are common in the fibrous and cicatricial tissue; at first oval, or round, inclosed on all sides by connective tissue, they may in time break through into the lumen and thus produce sinuous ulcers with undermined edges, the floor being covered with a curdy material composed of detritus and crystals of fatty acids, and frequently large accumulations of cholesterin tablets are also found. (Plate 10, Fig. II.)

PLATE 10.

FIG. I.—**Atheroma of the Aorta (Arteriosclerosis).** ×20. 1, Intima, greatly thickened through sclerotic, slightly cellular, connective tissue; 2, media, also thickened with patches of new connective tissue (at 3); 3, shoots of new blood-vessels, surrounded by small, round cells, growing from the adventitia toward the intima.

FIG. II.—**Cholesterin Plates and Free Fat-droplets from an Atheromatous Patch of Wall of Aorta.** ×130. A fresh preparation.

FIG. III.—**Fatty Degeneration of the Cells of the Intima in Artheroma of the Aorta.** ×300. Fresh preparation, which was obtained by stripping a fine lamella from the thickened and yellow intima of the aorta.

The star-shaped cells normally present in the intimal connective tissue are clearly shown, since they are filled with a large number of variously sized fat-droplets.

The frequent occurrence of very extensive calcification in such cases is well known. The calcareous deposits may be situated at various levels; they occur either in the innermost layers of the connective tissue, while the necrosis progresses underneath; or they may reach down into the media in the form of broad and thick plates and scales with irregular projections toward the lumen.

The external layers of the arterial wall may also show abnormal conditions. Cellular accumulations in the adventitia pass in between the muscular bundles and elastic plates of the media. These generally correspond to the newly formed vessels, originating from the vasa vasorum, and running in various directions, sometimes reaching into the intima. In their course are seen large, polygonal, and spindle-shaped cells, as well as lymphocytes. The elastic elements of the media may be separated by the cell accumulations, and their continuity interrupted. Often evidences of degeneration are noticed. In the adventitia groups of leukocytes resembling lymph-*follicles may occur.*

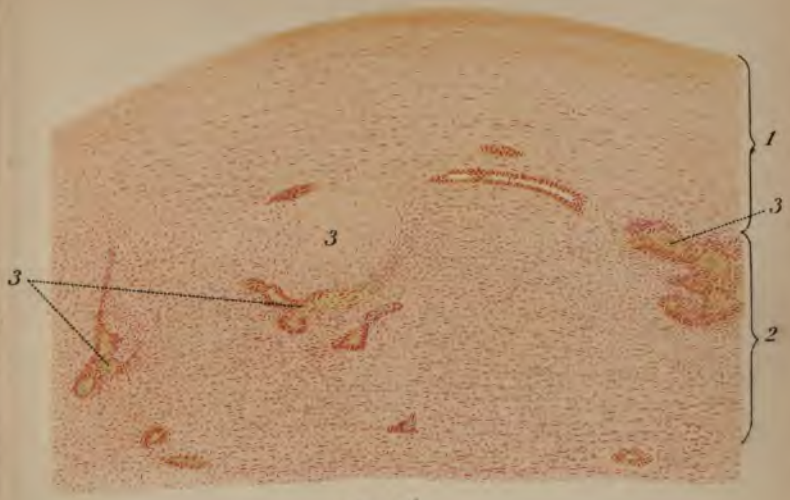

Fig. 1.

Fig. 2.

Fig. 3.

Lith. Anst. F. Reichhold, München.

Arteritis.—Inflammations occur in the walls of all arteries that lie in tissue the seat of inflammatory processes; involvement of the arterial walls is especially marked in tuberculous and syphilitic granulation tissue, but the arterial changes do not, of necessity, present specific characteristics. The acute stages of these processes are seen especially well in tuberculous leptomeningitis. In the beginning the adventitia is richly infiltrated with leukocytes, which form broad, deeply stained, cellular circles about the innermost arterial walls. Gradually, wandering cells pass into the muscular layers of the media. Under high magnification the cells are seen plainly making their way between the circularly arranged muscular cells; the wandering cells assume long-drawn-out forms; the nucleus, at first shaped like a pear, becomes long and filamentous, so that narrow passages are traversed; frequently, the ends of the nucleus are swollen while the connecting central piece is creeping through a tight place. The cells also seem to pass through the preformed spaces in the internal elastic coat, and accumulate in small heaps under the epithelium, which is raised up from its normal substratum; later, the epithelium is broken through in places, and leukocytes reach the lumen of the vessel, where they aggregate in the form of small, parietal, cellular masses.

In this process exactly the reverse occurs of the leukocytic emigration as is seen in Cohnheim's well-known experiment. (See General Part, Inflammation.) Here it concerns immigration. In the further course the internal elastic layer becomes more and more separated from the endothelium, which is lifted up; usually, this condition is not uniformly present at the entire periphery of the arterial lumen, one side of which generally shows the normal relations of the elastica and the epithelium.

Commonly, the continuity of the elastic coat becomes destroyed at the point of the greatest accumulation of

PLATE 10 a.

FIG. I.—**Arteriosclerosis of the Crural Artery.** × 55. Staining of the elastic fibers according to Weigert: 1, Adventitia; 2, compressed and atrophied media; 3, greatly thickened intima; at 4 sclerotic, fibrous tissue, noncellular; at 5 scales of lime salts containing spaces filled with a fatty detritus.

FIG. II.—**Wall of a Small Aneurysm of the Aorta.** × 20. Weigert's elastic fiber stain. The intima is somewhat diffusely thickened, and surrounds the lumen of the aneurysm completely (1); the media (with numerous elastic fibers) is greatly atrophied and nearly torn (2); 3, thickened adventitia, infiltrated with spindle-shaped and round-cell accumulations.

---

leukocytes, among which are now found other cells, such as large, spindle-shaped cells with much protoplasm and a vesicular nucleus; these cells are plainly fibroblasts and descendants of the normal, subepithelial connective tissue.

[In tuberculous leptomeningitis and probably also in tuberculous processes elsewhere, there quite constantly occurs a subepithelial proliferation of connective-tissue

---

PLATE 10 b.

FIG. I.—**Acute Arteritis in Tuberculous Leptomeningitis.** (From the wall of a small meningeal artery.) × 745. 1, Adventitia; 2, media; 3, elastica interna; 4, detached epithelium; 5, in the muscularis, emigrating leukocytes, showing various stages of deformity; 6, leukocytes which have passed through the internal elastic coat and reached the epithelium.

FIG. II.—**Gummatous Arteritis of the Subclavian Artery.** × 16. Weigert's elastic fiber stain. The lumen is almost occluded as the result of the proliferation of the intima, the elastic fibers of which are greatly increased. In the media numerous gummata with cheesy centers (1) and giant cells (2) reaching to the intima. Vasa vasorum of the adventitia infiltrated with small, round cells.

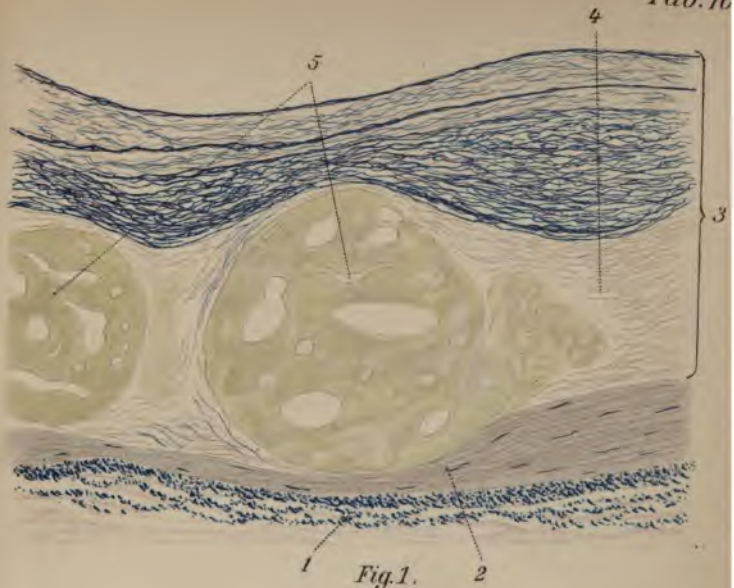

Fig. 1.

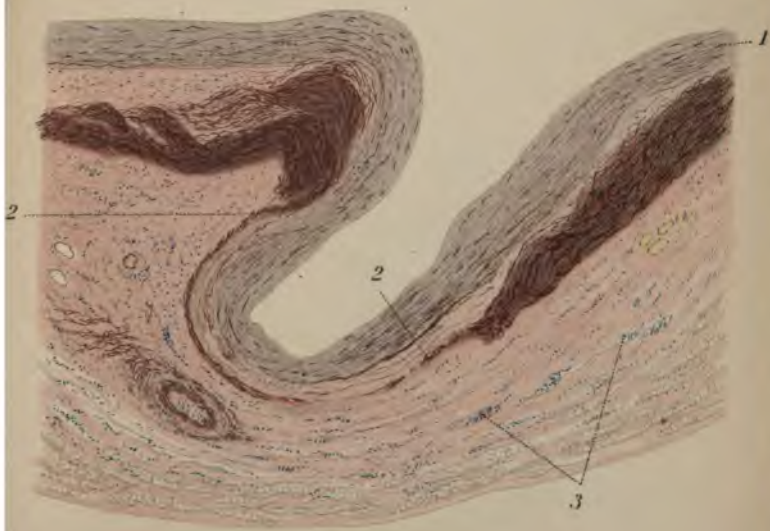

Fig. 2.

Lith. Anst. F. Reichhold, München.

Tab. 10, b.

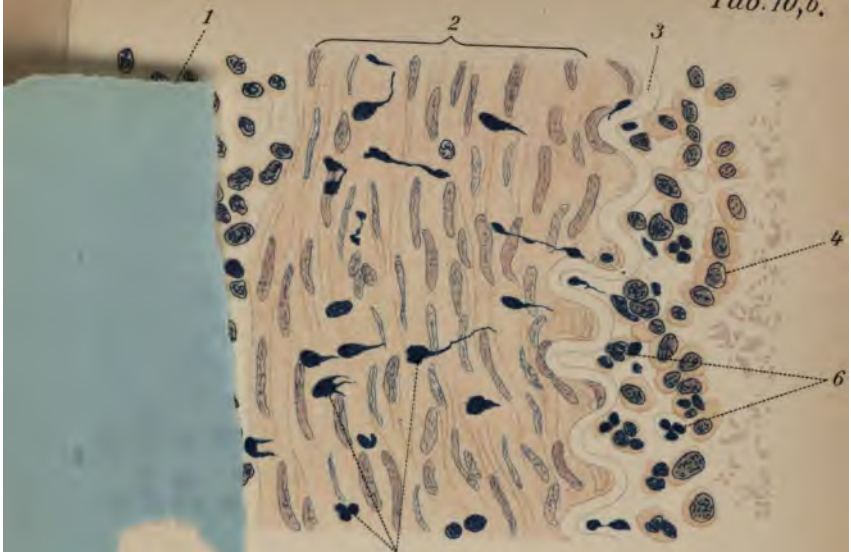

Fig. 1.

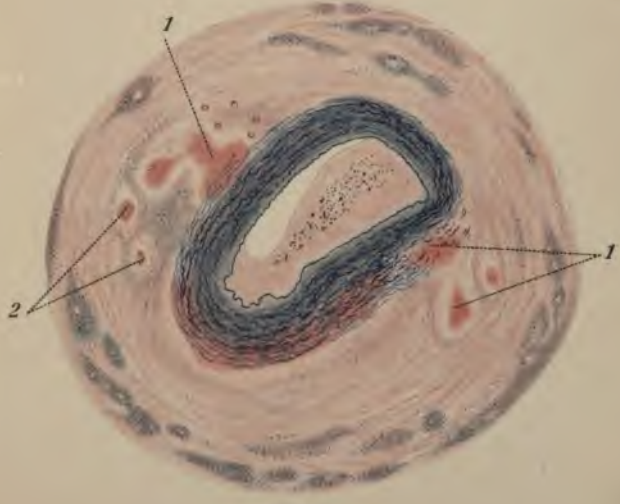

Fig. 2.

Lith. Anst. F. Reichhold, München

cells, resulting in the formation of a layer of epithelioid cells among which giant cells are sometimes found ; this form of tuberculous endoarteritis is not due to extension from without.]

Similar changes are observed in tuberculous areas in the lungs, especially in the vessels which pass like bands through the caverns. In such the increase in the thickness of the walls leads to great narrowing and even closure of the lumen, whereby the entrance into the blood of the infectious agent is prevented. Later, the small, round cells and leukocytes disappear, and a fibrillated connective tissue forms in the former vascular channel. Occasionally, in the midst of this connective tissue a new elastic membrane appears, thinner than the original elastic membrane whose general course it imitates ; it forms the inner bounds of the new, greatly narrowed, lumen. But the process is not necessarily at a standstill as yet. Inside of the new elastic layer connective tissue may again form, which then leads to complete obliteration of the lumen and occludes the vessels permanently (endarteritis obliterans). Obliterating endarteritis of this kind must not be confounded with the process of organization which occurs in occluding thrombi and which also eventually may obliterate the lumen by new fibrous tissue. This process is described in the General Part in connection with the consideration of Thrombosis.

In addition to this indifferent form of arteritis, which, it is true, is observed principally in tuberculous and syphilitic granulation tissue, there are also true, specific forms, in which syphilitic or tuberculous nodules arise in the arterial walls. In gummous arteritis the adventitia especially is the seat of the nodules that more rarely develop in the media or reach to the intima, which becomes thick on account of newly formed fibrous and elastic tissue. At first, the areas are rounded aggregations of lymphocytes and epithelioid cells ; soon a caseous necrosis

PLATE 11.

FIG. I.—**Arteritis Obliterans (Orcein Stain).** × 37. 1, Adventitia; 2, media; 3, internal elastic coat, which at some places is fibrillated; 4, newly formed connective tissue, nearly filling the lumen; at 5 it contains several blood-vessels; 6, part of lumen limited by a fine, new-formed elastica.

FIG. II.—**Arteritis Obliterans (Sylvian Artery) in Syphilis.** × 80. 1, Adventitia; 2, muscularis; 3, normally preserved old elastica interna; 4, proliferated connective tissue; 5, newly formed tunica elastica, imitating the course of the old; 6, newly proliferated connective tissue growing into the lumen, which it has fully occluded.

---

occurs in the center, while at the periphery there is a tendency to fibrous encapsulation. Occasionally, a single cross-section of large vessels may show in the wall a series of such nodules. (Compare Fig. I, Plate 10 b.)

Tubercle usually extends to the walls of vessels from the neighborhood. The thin walls of veins are not rarely infiltrated by tuberculous foci, from the rupture of which into the lumen the circulating blood may become contaminated with infectious material, leading to a multiple embolic tuberculosis in the corresponding capillary territory. In case of invasion through a pulmonary vein the general circulation becomes involved; in case of a vein elsewhere, a miliary distribution in the lungs would follow, and in an artery in its capillaries.

Aneurysm.—Only those aneurysms are of histologic value in which the arterial walls remain intact. In the dissecting aneurysms there occurs a simple rupture of the intima, and also of the media, through the base of a defect of arteriosclerotic or other nature. The entering blood stretches the adventitia and forces it outward.

In the true aneurysm the intima is retained and clothes the inner surface of the aneurysm throughout its whole extent. The usual changes of the intima are those of arteriosclerosis; the elastic fibers are replaced over exten-

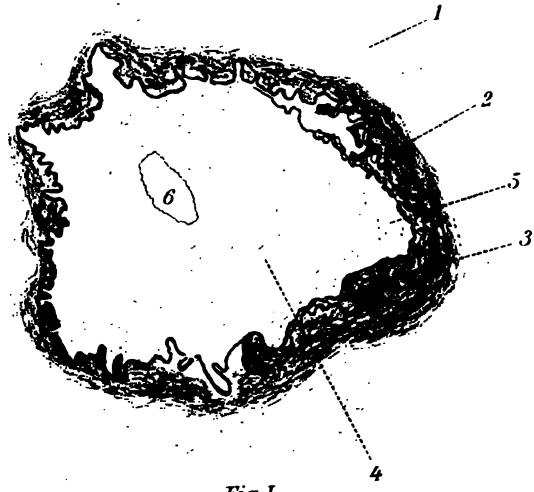

Fig. I.

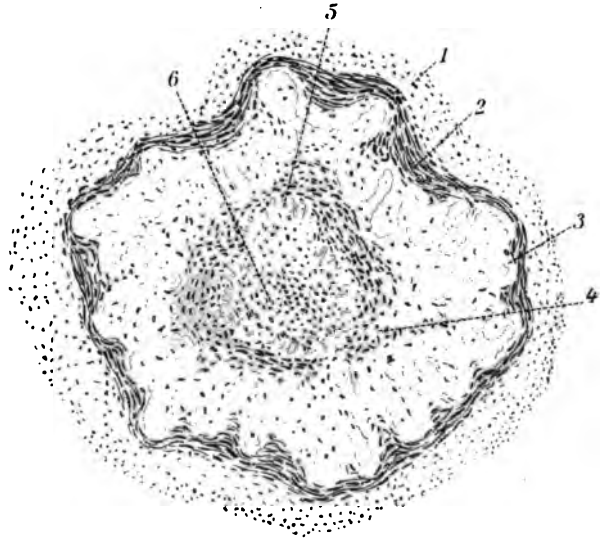

Fig. II.

Lith. Anst F. Reichhold, M

sive areas by a sclerotic fibrous tissue; often the intima shows recent vascular foci of infiltration, and its thickness is increased. The media presents constant and characteristic changes, which must be regarded as essential and of fundamental import in the development of the aneurysm. Its muscular and elastic layers are greatly reduced in thickness, amounting to complete absence at the point of greatest dilatation. This is especially well shown in aneurysms of the aorta, where the media consists mostly of elastic fibers, which are now seen to end abruptly in the margin of the dilatation, or to become greatly attenuated.

Frequently, there are seen interruptions in the continuity of the muscular and elastic fibers, the fragments having been pushed aside irregularly so that they have lost their originally circular arrangement. At the bottom of large aneurysms the media is often wholly absent, the intima being in direct contact with the adventitia; frequently, granular blood pigment is found in such places. The adventitia also is nearly always altered, especially in the way of excessive thickness, on account of increase in the connective-tissue fibers; there are also areas of cell infiltration, most marked about the vasa vasorum, which commonly show more or less narrowing and often complete endarteritis obliterans.

Amyloid degeneration of arteries is considered in the General Part in connection with Amyloidosis.

Veins.

Inflammations of the walls of veins are either due to extension from the neighborhood, as in erysipelas of the skin and in phlegmons, and successively attack the adventitia, media, and intima (periphlebitis, mesophlebitis, endophlebitis—Virchow), or they arise from infectious thrombi,—that is, from within,—in which case the intima is first involved. The second form is designated as thrombo-

PLATE 12.

FIG. I.—**Tuberculous Arteritis from a Subacute Tuberculous Meningitis.** × 280. 1, Lumen eccentric in outline and greatly narrowed ; 2, internal elastic coat, which is torn at 3 ; 3, between it and the endothelial lining a number of cells have proliferated, consisting of leukocytes, lymphocytes, and epithelioid cells ; the muscular coat is present only to a slight extent above and to the left ; 4, large sized tubercle with caseous center at 5.

FIG. II.—**Tubercle in the Wall of a Larger Branch of the Portal Vein.** Rupture into the lumen ; subacute disseminated tuberculosis of the liver. × 40. 1, 1, Liver tissue ; 2, centrally caseated tubercle ; 3, lumen of branch of the portal vein ; at 4 the vessel wall is ruptured on account of the richly cellular infiltrations of the periphery of the tubercle, which is projecting into the lumen of the vein.

---

phlebitis, and is more fully considered under Thrombosis, as are also the processes in the walls of the veins associated with the organization of thrombi.

Pure phlebitic processes run a course similar to acute arteritis. The vasa vasorum of the adventitia are congested, leukocytes migrate into the inner layer of the vein walls and reach the lumen, into which they occasionally penetrate and induce a secondary thrombosis, so that here also a thrombophlebitis is established. In phlegmonous processes a formal suppuration of the venous walls may occur. In addition to the pus-cells there are found, however, also large polygonal and spindle-shaped cells with vesicular nuclei—derivatives of the connective-tissue cells normally present in the wall. The muscular coat is pressed asunder, its fibers are disarranged, and often the muscle nuclei can not be found throughout large areas. Severe purulent forms of phlebitis are caused mostly by streptococci, and lead, in the majority of cases, to multiple, purulent metastases and death, under the clinical picture *of pyemia.* *Chronic* inflammations of the walls of veins

Tab. 12.

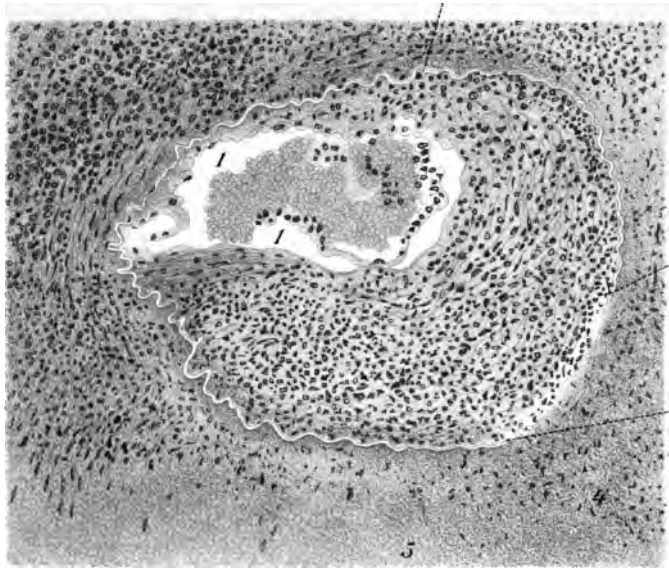

Fig. I.



Fig. II.

Lith. Anst. F. Reichhold, München

cause a diminution of their elasticity, followed by dilatation of the lumen, which assumes a markedly irregular form (varix, phlebectasia). In old varices the intima consists mostly of a coarse connective tissue of varying thickness in different places, often producing nodular projections into the lumen. The muscular elements of the media are generally wholly destroyed, while the elastic fibers usually do not suffer in such marked degree. The adventitia is usually much thickened, and passes without any distinct boundary into the surrounding connective tissue, which, especially in the case of subcutaneous varices, generally shows a diffuse hyperplasia.

Occasionally, calcification of the walls of veins occurs; large, calcareous masses of this kind are called phleboliths, especially those which result from infiltration of thrombi.

The extension to the venous wall of tuberculous and syphilitic areas in the adjacent tissue has been referred to.

LYMPHATIC GLANDS.

The lymphatic glands are organs in which lymphocytes develop, intercalated in the system of lymphatic vessels. They consist of a framework of connective tissue in which lymphatic cells are accumulated into regular groups. The glands, which are more or less reniform, are surrounded by a capsule of several layers of connective-tissue fibrillæ, among which lie a few smooth muscle-fibers. The inner surface of the capsule sends off connective-tissue septa, or trabeculæ, which converge toward the hilus, and are connected with an extremely fine reticular tissue, which is stretched across the spaces between the septa. At the intersection of the fine fibrillæ lie flat cells with small, round, dense nuclei. The reticulum contains accumulations of lymphoid cells arranged in the form of rounded nodules situated at the periphery of the convexity of the

PLATE 13.

FIG. I.—**Acute Suppurative Phlebitis in Phlegmonous Inflammation of the Cellular Tissues of the Skin.** × 40. The lumen of the vein has become narrowed to a slit-like opening (1), in which are seen cloudy coccal masses; the wall is hardly recognizable, due to the great infiltration of leukocytes; the vessels of the adventitia are greatly dilated and filled with blood (2); some of their shoots have proliferated toward the lumen (3); at 4, remains of tunica media.

FIG. II.—**Varix from the Leg.** × 26. Elastic stain. 1, Epidermis; 2, cutis; 3, sweat-glands; the adventitia of the dilated vein with the numerous elastic fibers can not be separated from the surrounding connective tissue; the media has disappeared; 4, thickened intima; the lumen is more or less affected as the result of the great irregularity and tortuosity of the vessel.

---

glands. These are called secondary nodules or follicles; they lie between the trabeculæ, and present a dense and dark outer zone of concentric layers, and a lighter center —the germinal center—in which the lymphocytes are produced and in which numerous mitoses are normally found. The zone in which the follicles lie is called the cortex of the lymph-glands. The follicles send off into the central parts cord-like, lymphocytic accumulations, which anastomose freely. These form the medullary substance or follicular cords. Between the follicles themselves, between the follicles and the capsule and the trabeculæ, and between the follicular cords run cleft-like spaces traversed by reticulum. These spaces are called lymph-sinuses; they are in direct communication with the lymph-vessels, which enter the convexity of the glands as vasa afferentia, and emerge at the hilus as vasa efferentia. The sinuses that lie between the capsule and the cortex are called marginal, those near the hilus and in continuity with the efferent vessels are called terminal sinuses. All sinuses are lined with flat, polygonal, epithelial cells, as are also the fibers of the reticulum which pass through the sinuses.

Tab. 13.

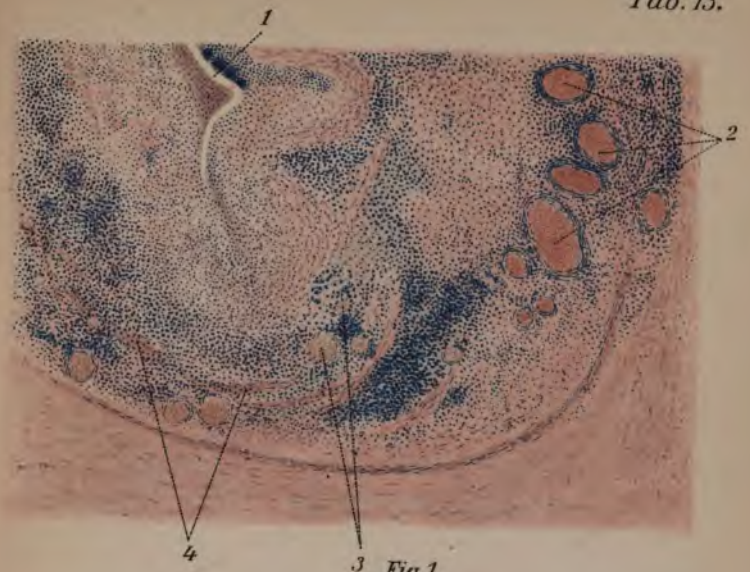

Fig. 1.

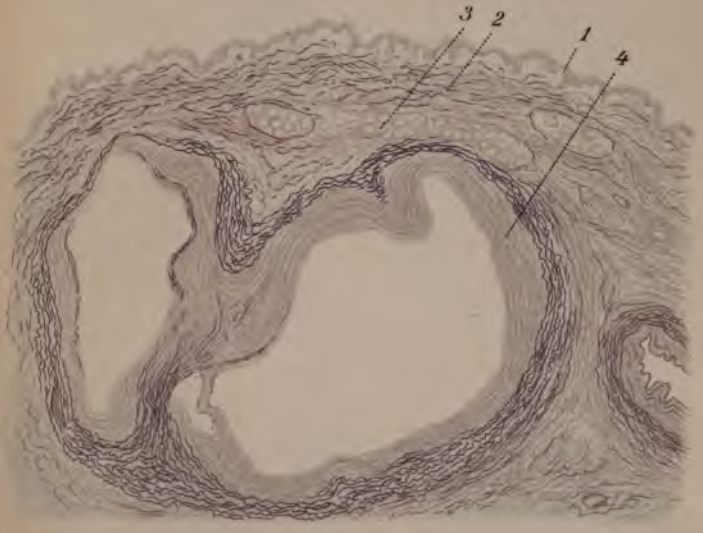

Fig. 2.

Lith. Anst. F. Reichhold, München.

The lymph flows through the sinuses and receives cells from the germinal centers. The larger blood-vessels run, for the most part, within the trabeculæ.

By virtue of their peculiar structure and of their situation as way-stations in the lymph-stream, the lymph-glands are capable of retaining chemic substances and formed elements of all kinds which reach them from the periphery. Hence, they nearly always are involved by inflammatory processes which run their course in the territory drained by their respective radicles. Not only irritating substances, but also substances of indifferent nature are brought to and deposited in the lymph-glands—as, for instance, blood from hemorrhagic extravasations accompanied with rupture or opening of the lymph-channels. The red corpuscles reach the glands, either free or inclosed in cells, and are here changed to pigment masses. Granular and flaky blood pigment may later be carried to the sinuses by lymphocytes.

The peribronchial and other intrathoracic glands are extensively involved in the various forms of pneumoconiosis; and after tattooing, exogenous pigments of various kinds may reach the regional lymph-glands.

The distribution of corpuscular elements in the lymph-glands follows a certain regularity, depending on the physical peculiarities. The fine particles are carried by the lymph-stream through the vasa efferentia into the lymph-sinuses, and are deposited in the perifollicular lymph-spaces, either free or inclosed in large, round cells. The circumstance that in the early stages the granules usually are found free, but later intracellular, indicates that they are taken up by the cells after they have reached the lymph-glands. From the perifollicular lymph-spaces the fine masses pass into the follicles and the follicular cords. In the earlier periods they are found only at the periphery of the follicles, the germinal centers remaining free; at first the granules are found mostly in small, round cells;

PLATE 14.

FIG. I.—**Deposition of Pigment in an Axillary Lymph-gland as a Result of Tattooing on the Forearm.** × 300. The lymph-sinuses and peripheral portions of the follicle are filled with large, dark masses of pigment which is partly intracellular.

FIG. II.—**Mesenteric Lymph-gland in Typhoid Fever.** × 360. 1, Small artery with partly detached epithelium; in the adjacent lymph-sinus are numerous large, round cells, some containing two nuclei. Their protoplasmic bodies are infiltrated with fat-droplets [digestive vacuoles?] (2); furthermore, lymphocytes (3), red blood-corpuscles, and a granular detritus; 4, clumps of typhoid bacilli.

---

later, also in spindle- and star-shaped cells, which undoubtedly belong to the reticulum, as well as in the flat cells, which cover the trabeculæ. The nuclei of the cells are sometimes recognizable among the granules, but often the granules cover them, in which case the occurrence of masses with regular outlines indicates the intracellular situation of the foreign particles. Up to this stage it concerns a simple deposition of particles in the glands; later, the follicles and follicular cords may atrophy at the same time as the connective tissue undergoes hyperplasia, and thus obliterate the lymph-spaces. The capsule becomes materially thicker than when it is normal; from its inner surface arise the broadened trabeculæ, which pass as massive connective-tissue bands into the gland, and at the same time the reticulum is increased by the proliferation of spindle-shaped and stellate cells, while the lymphoid cells disappear; the reticular tissue becomes more and more fibrous, and eventually it presents a wavy, fibrillated structure. In time the connective-tissue bands which are formed in this way change into broad, glistening, anuclear, hyaline beams, similar to those seen in other chronic inflammatory conditions of the lymph-glands.

Occasionally, the particles in an overladen lymph-gland



Fig. 1.

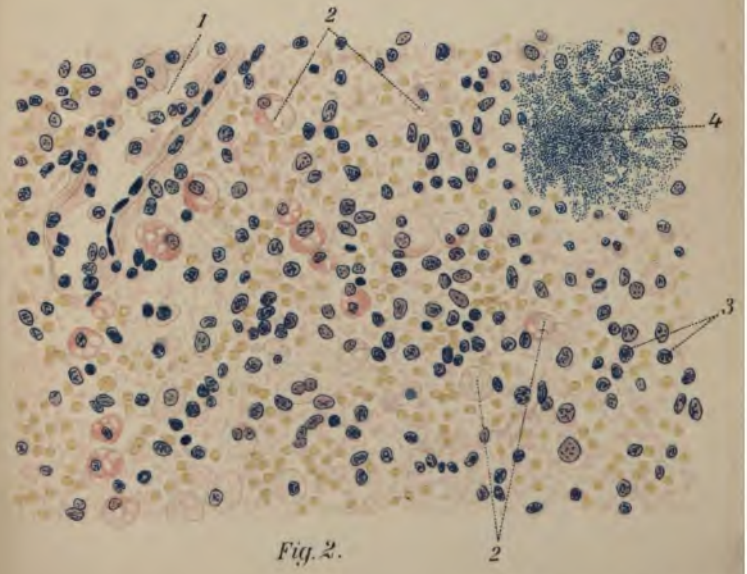

Fig. 2.

Lith. Anst. F. Reichhold, München.

are transferred to the blood ; this is especially due to erosion of the walls of adjacent blood-vessels by the indurated and enlarged glands.

Pathologic pigments originating in the skin and elsewhere may be carried to the lymph-glands, and, under certain circumstances, the normal cutaneous pigment may likewise be taken to the glands—as, for instance, in syphilitic leukoderma.

When phlogistic substances, especially bacteria, are brought to the lymph-glands from the territory drained by these, then secondary inflammatory foci are produced. The course of these processes varies, depending on the kind and specific mode of action of the micro-organisms in question. Thus, in suppurative inflammations in the peripheral parts, in erysipelas, and in pneumonic processes, the corresponding regional lymph-glands severally present inflammations of the suppurative type. The capsule is loosened and richly cellular, and its lymph-vessels are distended with leukocytes ; the trabeculæ may also be infiltrated with cells ; the vessels are congested ; and it is especially noticeable that the lymph-sinuses are widened at the expense of the follicles and follicular cords. The sinuses also contain masses of leukocytes with fragmented nuclei, as well as red corpuscles in varying numbers, and a finely granular, molecular mass, which consists of detritus imported from the periphery. The cells of the reticulum and also the epithelial cells of the glands always undergo marked proliferation in processes of this kind. When the pyogenic microbes are present in great numbers, purulent disintegration and abscess formation may take place in the glands, in which cases the follicles and the medullary parts become infiltrated with leukocytes which crowd out the lymphocytes. In croupous and diphtheric inflammations of the mucous membranes the regional lymph-glands are also the seat of exudative processes ; in the sinuses and at the peripheries of the follicles

PLATE 15.

FIG. I.—**Acute Lymphadenitis.** Peripheral sinus of a peribronchial lymph-gland in croupous pneumonia. × 386. 1, Capsule of the lymph-gland, the fibers loosened and spread apart; 2, marginal sinus, containing 3, lymphocytes, 4, leukocytes, 5, enlarged and proliferating epithelium, 6, shadows of red blood-corpuscles, 7, granular detritus.

FIG. II.—**Large Cellular Hyperplasia of a Lymph-gland in Acute Pernicious Anemia.** × 745. The lymph-sinuses are filled with large, elongated, fusiform, and round cells, which are looked upon as springing from the reticular epithelium. Among them are single (1) lymphocytes.

---

fibrin is deposited; the blood-vessels of the glands may be occluded by fibrinous plugs.

Characteristic changes occur in the mesenteric and retroperitoneal lymph-glands in typhoidal disease of the intestines: Typhoid bacilli are found in large, close, aggregated heaps in the greatly swollen and softened glands (medullary infiltration); the blood-vessels are greatly dilated and filled with red and white corpuscles; the lymph-sinuses are many times wider than normally, the follicles correspondingly small and compressed, and at times almost unrecognizable; in the sinuses are found numerous, large, protoplasmic cells that often are somewhat flattened by mutual pressure; their nuclei are deeply stained and granular, resembling those of the lymphocytes; frequently a cell contains two or three or more nuclei; in the protoplasm are numerous fat-vacuoles. [As shown by Mallory, these cells have marked phagocytic properties, and the vacuoles may be digestive vacuoles. The large cells are often seen to contain red blood-corpuscles, lymphocytes, etc.] These cells appear to originate not from the fixed cells, but from the lymphocytes whose cytoplasm has greatly enlarged under the influence of the infection. [Undoubtedly the epithelium of the blood- and

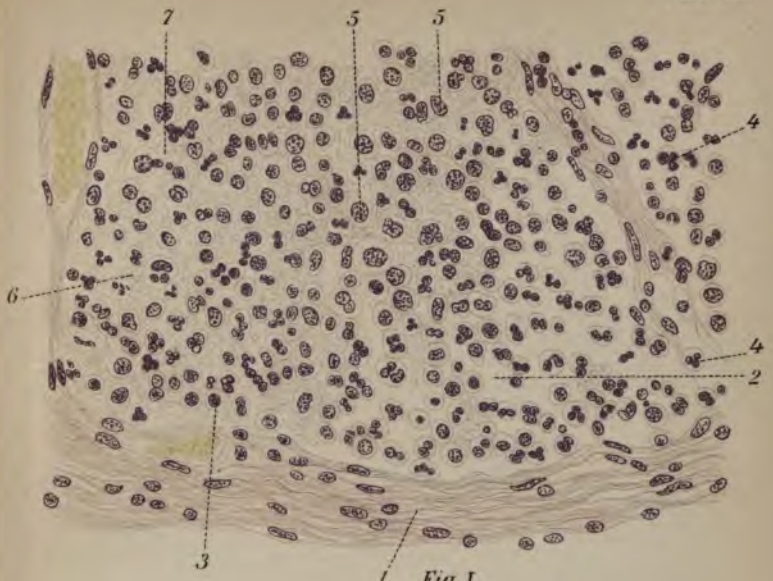

Fig. I.

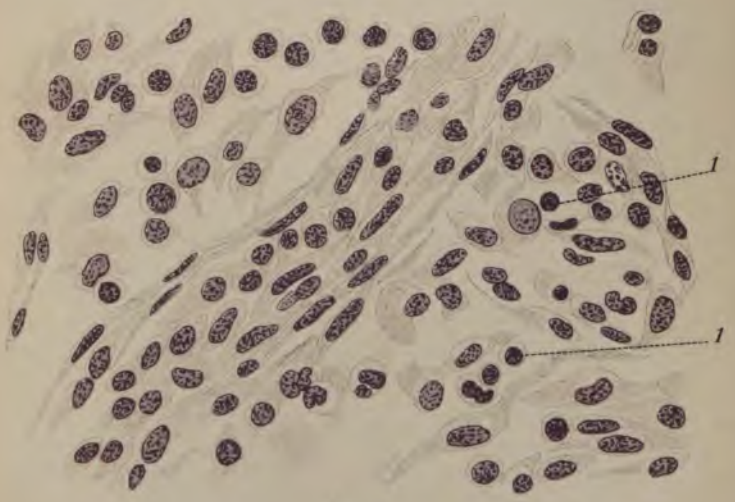

Fig. II.

Lith. Anst F. Reichhold, München

PLATE 16.

FIG. I.—**Hyaline Degeneration of the Reticulum of a Lymph-gland in Tuberculosis.** × 280. Among the lymphocytes are seen single reticular fibers, which are greatly thickened and transformed into shining, homogeneous, nonnucleated bars (1).

FIG. II.—**Chronic Indurative Lymphadenitis with Destruction of the Lymph-sinuses and Follicles in Leukemia.** × 180. 1, Thickened capsule; 2, Lymphadenoid tissue compressed as a result of the new growth of wavy bundles of short fibers of connective tissue.

---

connective-tissue elements of the reticulum. At the periphery there is a massing of leukocytes (Baumgarten). The center of the nodules undergoes caseation, and the confluence of several caseous areas may give rise to caseation involving whole glands or gland packets—"scrofula," because so often observed in swine (*skropha*). In the vicinity of the nodules proliferation of the sinus epithelium occurs and dilatation of the spaces; occasionally, caseation takes place in such districts of proliferation without there having first formed distinct nodules or tubercles. The caseous necrosis may extend to the capsule, whence it may extend to the neighborhood, and lead, perchance, to perforation of adjacent hollow organs, such as the trachea, bronchi, and vessels.

PLATE 17.

FIG. I.—**Chronic Indurative Lymphadenitis with Destruction as a Result of Increase of the Reticulum in Leukemia.** × 460. (A part of the preceding section.) The lymphocytes (1) as well as the epithelium are greatly diminished on account of the enormously thickened reticulum.

FIG. II.—**Subacute Tuberculosis of a Lymph-gland.** × 70. 1, Thickened capsule; 2, caseous centers of the tubercles. At the periphery of the gland the tubercles are still discrete, and between them lies lymphadenoid tissue. In the center of the gland the nodules have formed larger confluent areas. Numerous giant cells.

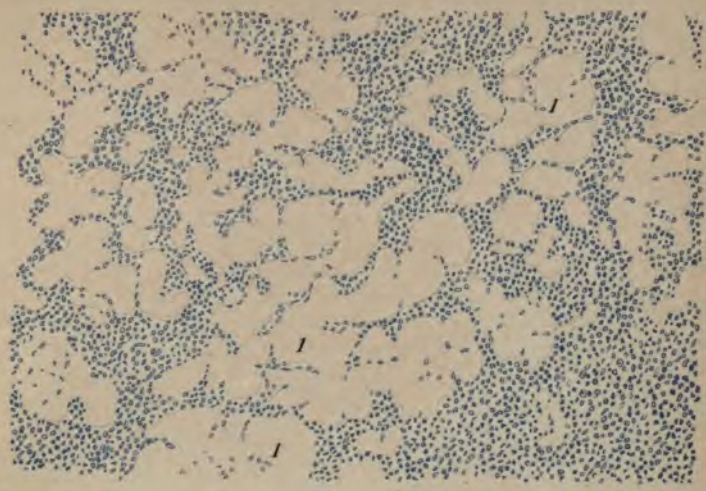

Fig. I.

Fig. II.

Lith. Anst. F. Reichhold, München.

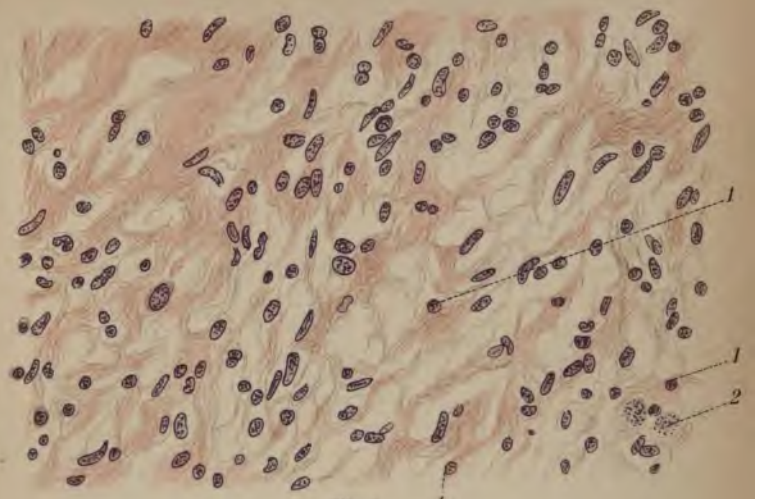

Fig. I.

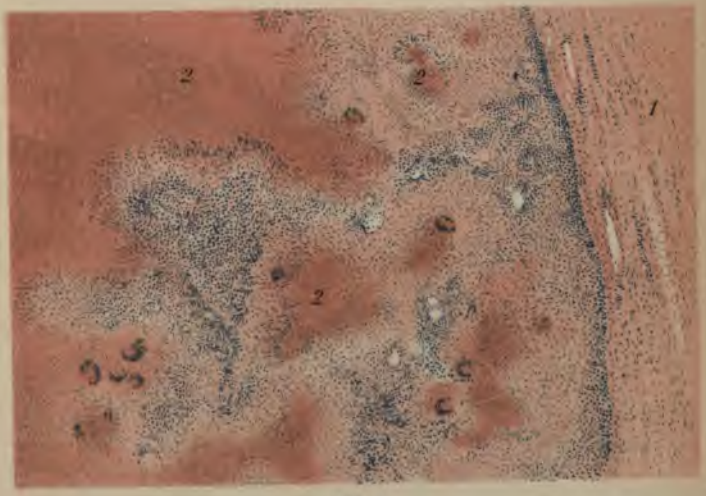

Fig. II.

Lith. Anst. F. Reichhold, München

THE SPLEEN.

The histologic structure of the spleen presents certain similarities to that of the lymph-glands. The capsule, coalesced with the external peritoneal covering, is composed of rigid, connective-tissue fibers, among which are scattered muscular and elastic elements. In the spleen, also, the trabeculæ give rise to an exceedingly delicate, sieve-like, reticular, connective tissue, which is stretched across the intertrabecular spaces, and constitutes the framework of the splenic parenchyma. The trabeculæ and the reticulum are clothed with large, flat, and peculiar crescent-shaped epithelial cells. The splenic artery enters the organ at the hilus, and divides into branches whose adventitial sheaths at regular intervals are surrounded by oval, nodular accumulations of lymphocytes, called splenic follicles or Malpighian bodies. The splenic follicles are built up exactly according to the plan of the lymphatic follicle, like which they also contain germinal centers in which lymphocytes are continuously produced.

The arteries rapidly break up into arterial capillaries, which, contrary to those of other organs, do not go over into venous capillaries but end in the so-called intermediate lacunæ, which are wide, vascular spaces, bounded by perforated, sieve-like walls, which coalesce to form veins.

The remaining space in the spleen is occupied by the so-called pulp. This is a place of origin as well as destruction of red blood-corpuscles. In addition to normal erythrocytes the pulp contains also nucleated or embryonal red corpuscles, lymphocytes, and other cells inclosing red blood-discs, and the various stages of transformation of the blood coloring-matter, and also a varying amount of free, granular blood-pigment as well as lymphocytes, leukocytes, and the epithelial cells situated upon the stroma.

PLATE 18.

FIG. I.—**Passive Hyperemia of the Spleen.** × 360. Pulp-spaces overfilled with red blood-corpuscles (1); the capillaries also greatly dilated (2), their walls traceable for a short distance only.

FIG. II.—**Senile Atrophy of the Spleen.** × 80. The splenic pulp is infiltrated with numerous brownish masses of blood-pigment and occasional lines of spindle-shaped cells. The trabeculæ are considerably thinned.

Variations in the blood contents of the spleen are exceedingly common and, up to a certain degree, physiologic. Permanent delay of the outflow of the blood from the spleen on account of obstruction in the portal circulation gives rise to passive congestion of the spleen.

The peculiar structure of the intermediate lacunæ of the spleen and their close relation to the spaces in the pulp make it evident that in all congestions of the splenic vessels cellular elements from the blood pass out into the pulp tissue. In acute passive congestion not only are the capillaries dilated and filled with red corpuscles, but the red cells pass into the pulp and press its cells apart, so that they appear to have undergone diminution; the trabeculæ are also pressed together, and the outer layers of the follicles infiltrated with red cells. Generally, it is extremely difficult, if not impossible, to recognize the walls of the smaller blood-vessels. Macroscopically, a spleen in this condition is enlarged and of soft consistency, the cut surface of the pulp is deep red and swollen, so that the follicles and trabeculæ are covered over. In passive hyperemia of longer duration reactive changes occur on part of the walls of the vessels and of the stromal framework. The trabeculæ and the adventitia of the arterial vessels are thickened, and the walls of the smaller vessels also become more distinct; frequently, the endothelial cells are swollen, rounded, or nearly cubic, and project

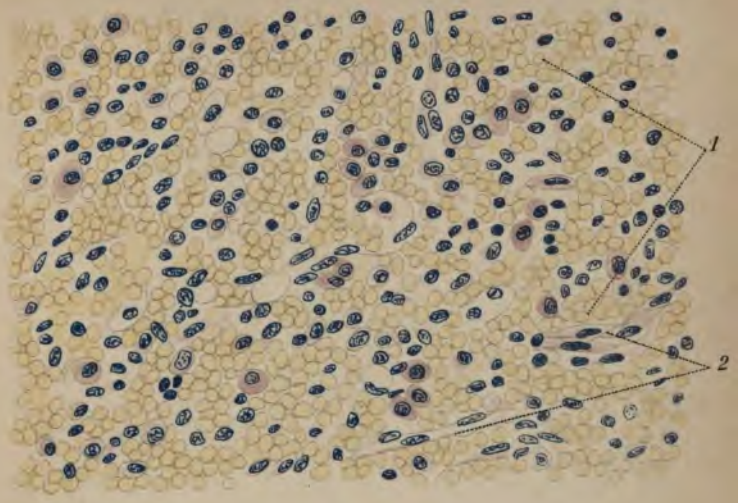

Fig. 1.

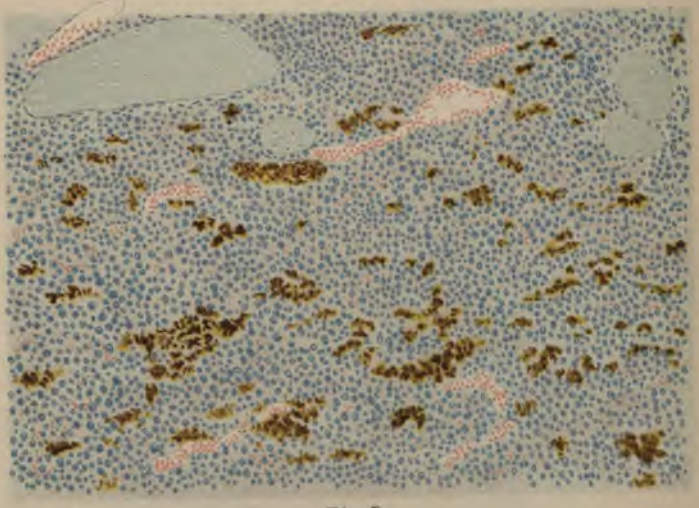

Fig. 2.

Lith. Anst. F. Reichhold, München

into the lumen. The reticulum appears increased on account of the presence of fibrillated tissue. There occurs constantly a deposition of blood-pigment in the form of brownish-red, scaly heaps between the connective-tissue fibers, and the large, rounded pulp-cells also contain pigment granules.

Pigmentation occurs, further, in old age and also in the course of severe cachectic diseases, especially carcinoma, when the spleen is usually atrophied. The reticulum is increased and thickened, and connective-tissue elements predominate. In the adventitial sheath of the vessels and in the pulp abundant, brownish, and granular pigment occurs in large and small masses, at first intracellular; later, almost entirely free. In chronic malaria there is marked pigmentation of the spleen due to the extensive disintegration of the red blood-corpuscles and the transformation of the hemoglobin into a black pigment, sometimes called melanin. In this condition the spleen is often thickly beset with black masses, at the same time showing the usual changes due to chronic inflammation.

Exogenous pigments also occur in the spleen; a genuine anthracosis is observed, especially in coal-miners, due either to the slow entrance into the blood of pigment-laden cells or to the rupture of enlarged, anthracotic lymph-glands into the lumen of a vein.

Infarcts.

Infarcts in the spleen are frequent, and result from the embolic occlusion of arterial branches by fragments of thrombi, endocardial excrescences, etc. The splenic arteries are end-arteries in Cohnheim's sense—that is, do not anastomose with each other—and consequently the white or anemic infarct is the most frequent. Retrograde currents in the veins and extravasations from the capillaries may, however, lead to a fairly uniform and early infiltration

PLATE 19.

FIG. I.—**Anemic Infarction of the Spleen.** ×22. 1, Capsule of the spleen; 2, completely necrotic and anuclear center of the wedge-shaped infarct; 3, dark peripheral zone, which, under the high power, shows numerous small nuclear fragments; the infarct has receded somewhat from the surrounding tissue, and is being encapsulated by fibrous tissue (4).

FIG. II.—**Hemorrhagic Infarct of the Spleen.** 1, Normal zone; 2, the infarcted area; the spleen-tissue is here necrotic, and the nuclei do not take the stain. The area is filled throughout with red blood-corpuscles; 3, transverse sections of blood-vessels; their walls are necrotic.

---

with red blood-corpuscles of the infarct, which then becomes red or hemorrhagic. In the subsequent stages the anemic infarcts nearly always present a hemorrhagic border, due to hemorrhages into the vicinity.

Splenic infarcts constantly have a wedge-shaped or pyramidal form, the base corresponding to the capsule and the apex pointing toward the hilus. A fresh anemic infarct is a yellowish-white area that projects above the level of the healthy tissue, than which it is of greater consistency. Microscopically, the necrosis, as shown by the absence of nuclear stain, is sharply defined from the healthy tissue. The follicles are still recognizable in the infarct, being somewhat darker in color, without, however, presenting any nuclear structure. These appearances are soon changed. On account of the loss of fluids the anemic and necrotic area shrinks and appears more or less collapsed; simultaneously, numerous leukocytes accumulate about the necrotic area, into which they gradually wander; in stained preparations the leukocytic accumulation appears as a dark ring. In the mean time proliferation of the preexisting connective tissue about the infarct gives rise to a capsule, which surrounds the dead tissue on all sides and cuts into it. The connective-tissue fibers are

Fig. I.

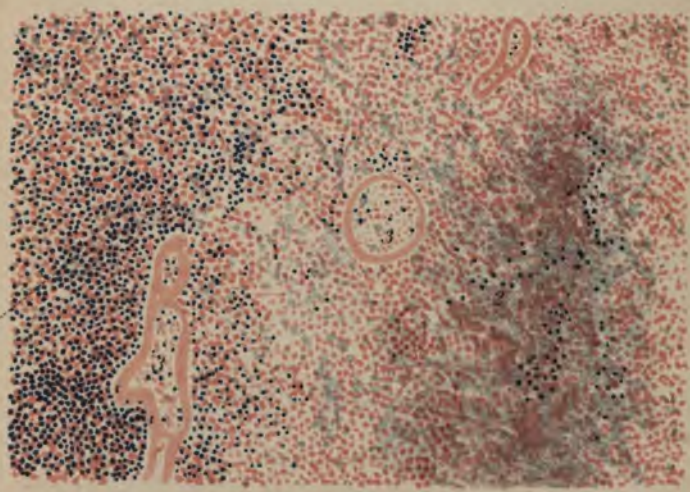

Fig. II.

Lith. Anst F. Reichhold, München.

at first short, mixed with large, spindle-shaped, and rounded cells, and they run parallel with the margins of the necrotic zone; for a long time they inclose in their meshes long rows of lymphocytes; frequently, pigment is present as a result of the hemorrhage about the margin of the infarct. While the connective-tissue capsule increases in thickness, becoming more and more fibrous, the inclosed necrotic area dwindles and shrinks and connective-tissue processes pass into its substance. Ultimately, there remains a hard, contracted scar, in the center of which there may be found a caseocalcareous or calcareous remnant of the infarct.

Multiple embolic scars are frequently observed. In the case of the hemorrhagic infarct it is to be noted, in addition, that the red corpuscles on disintegration give rise to pigment masses, remains of which are long to be seen in the scar.

Micro-organisms, when present in the blood in large numbers, as may be the case in malignant endocarditis, are filtered especially out by the spleen, whose vessels are not rarely closed up by heaps or emboli of microbes. The effects of such emboli are mechanical and inflammatory: the arterial closure produces an anemic necrosis, while the bacteria rapidly swarm through the arterial wall and induce a circumscribed, purulent inflammation, which may end in an embolic abscess. Occasionally, purulent foci reach the capsule of the spleen and the peritoneum, and acute purulent peritonitis may develop in consequence of the rupture of an abscess into the peritoneal cavity.

Acute Splenic Tumor.

By virtue of its peculiarly constructed, wide blood-spaces, the spleen constitutes a sponge-like filter, and in consequence it becomes extensively involved in all inflammatory processes in which microbes, or their pro-

PLATE 20.

FIG. I.—**Acute Hyperplastic Splenic Tumor.** A teased, fresh preparation. × 300. There are many crescent- and sickle-shaped cells (epithelial), some containing two nuclei (1); also lymphocytes (2), leukocytes (3), and red blood-corpuscles (4).

FIG. II.—**Acute Hyperplastic Splenic Tumor in Sepsis (Infectious Splenic Tumor).** Embedded section. × 300. The same elements are seen as in the previous section. The epithelium appears now as long, spindle-shaped cells (1), or shorter when cut obliquely (2).

FIG. III.—**Chronic Splenic Tumor Ending in Induration; from Leukemic Spleen in Chronic Leukemia.** × 250. Reticulum greatly thickened; poorly cellular, fibrillar connective tissue is taking the place of the richly cellular pulp. In the connective tissue the remains of the pulp, epithelial cells, lymphocytes, and red blood-corpuscles are present. At 1 there is a deposit of amorphous masses of blood-pigment.

---

ducts, enter the circulating blood, just as the lymphatic glands constitute a filtering apparatus for the lymph-stream. The enlargement of the spleen under such circumstances depends on an increased amount of blood in the capillaries,—especially the venous,—the exit of red blood-discs into the spaces of the pulp, the swelling and increase of the cells of the pulp, and on an importation of new cells (acute hyperplastic splenic tumor or swelling). General septic processes are usually accompanied with a marked increase in the volume of the spleen. A fresh smear preparation of the soft, swollen pulp of a splenic tumor of this kind will be found to contain numerous red corpuscles; large, round, granular, mononuclear cells, which often contain whole erythrocytes or fragments of such; also leukocytes with peculiar and horseshoe-shaped nuclei; and especially noteworthy are numerous large, sickle- and crescent-shaped cells drawn out into two fine processes. Corresponding to the site of the nucleus the protoplasmic body is swollen, and often such cells

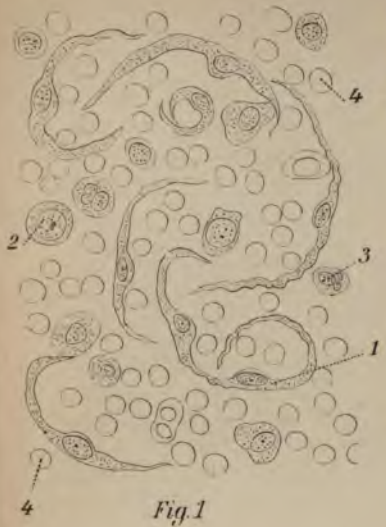

Fig. 1

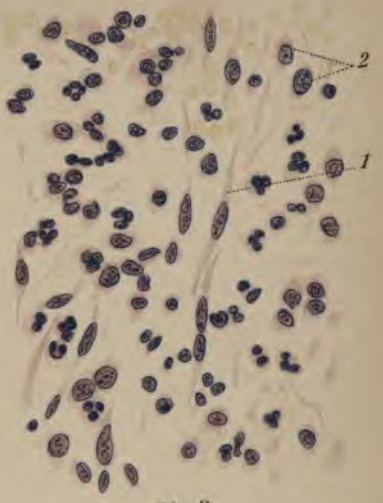

Fig. 2.

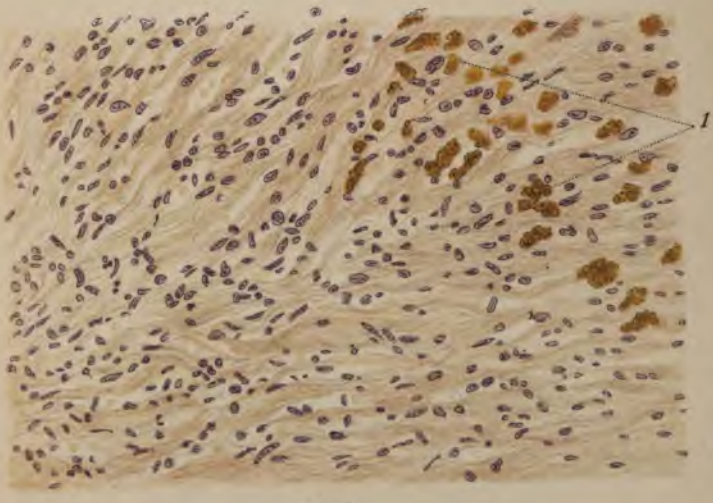

Fig. 3.

Lith. Anst. F. Reichhold, München

PLATE 21.

FIG. I.—**Diffuse Amyloid Degeneration of the Spleen (Bacon Spleen).** × 250. The process has as yet not advanced very far. The walls of all the blood-vessels are uniformly thickened, and the capillary and pulp-spaces narrowed. 1, Transverse section of a small artery with a greatly thickened and amyloid wall; at the periphery are still seen a few muscle nuclei; 2, oblique section of a similar vessel; 3, longitudinal section of a small artery; 4, capillaries.

FIG. II.—**Advanced Diffuse Amyloid Degeneration of the Spleen (Bacon Spleen).** Spontaneous amyloidosis in a woman, age eighty. × 70. Almost complete destruction of the pulp. The amyloid bands (1) are not confined to the blood-vessels, but the reticulum is also uniformly affected. The pulp-cells are largely destroyed. The remaining cells are the epithelium of the capillaries and a small number of lymphocytes. At 2 there are remains of an atrophied Malpighian corpuscle.

---

changed into a densely fibrillated tissue, which is distinguished with difficulty from the trabeculæ. The lymphatic cells are crowded out, and the capillary spaces are narrowed and contain but few blood-corpuscles. The follicles are small and widely separated, containing but few lymphocytes. Brownish blood-pigment is found quite constantly between the connective-tissue fibers. A spleen like this is naturally hard, firm, pale in color, and dry; often the pigment gives the tissue a distinctly brownish tinge.

PLATE 22.

FIG. I.—**Amyloid Degeneration of the Spleen (Sago Spleen).** × 24. 1, An amyloid follicle, in which are seen only a few nuclei; the blood-vessels, in transverse section, have also undergone amyloid degeneration; 2, compressed pulp-spaces; 3, trabeculæ.

FIG. II. — **Amyloid Degeneration of the Spleen (Sago Spleen).** × 260. 1, Follicle that has undergone amyloid degeneration, only few islands of cells remaining; 2, transverse sections of *blood-vessels with broad*, glistening (amyloid) walls; 3, normal pulp.

Tab. 21.

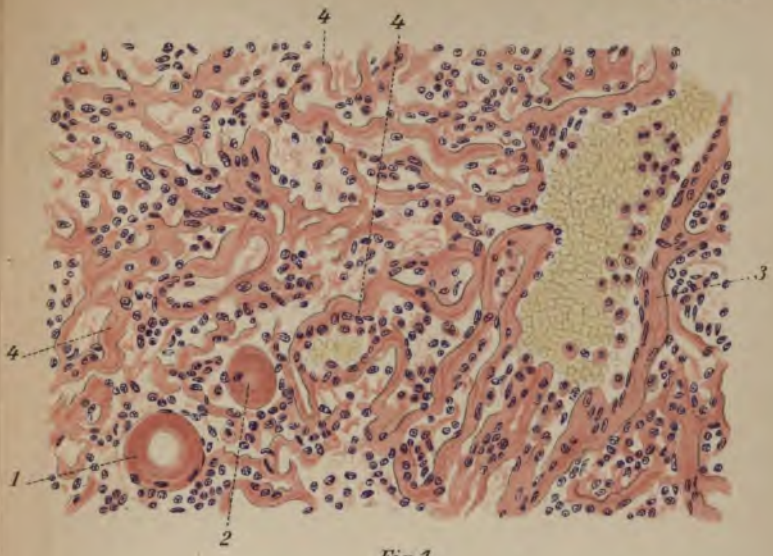

Fig. 1.

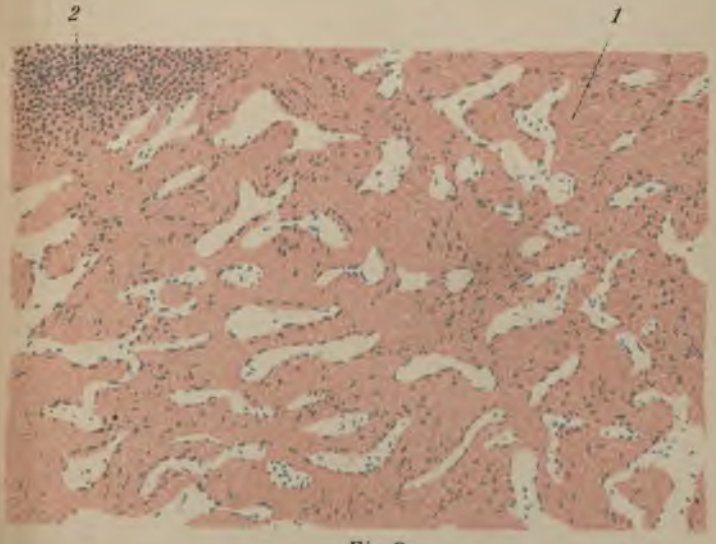

Fig. 2.

Lith. Anst. F. Reichhold, München.

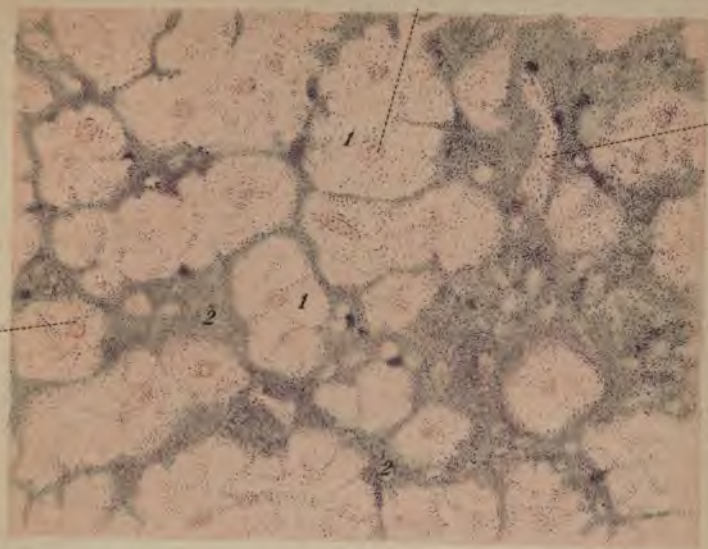

Fig. 1.

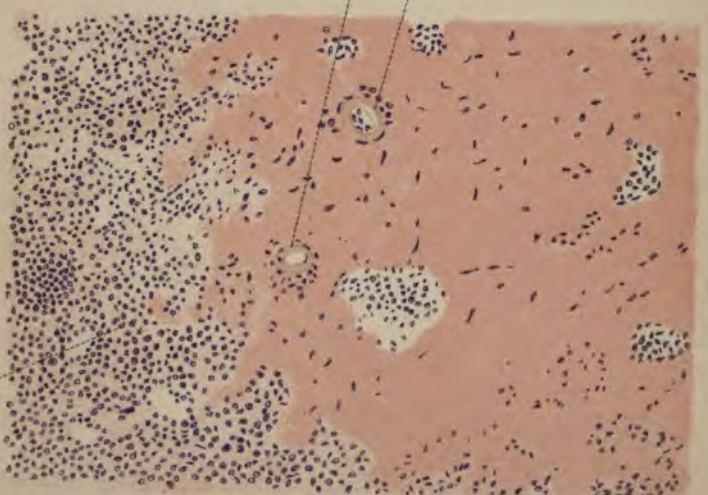

Fig. 2.

Lith. Anst. F. Reichhold., München

Degeneration.

Amyloid degeneration of the spleen is frequent; usually, it occurs in connection with amyloidosis of other organs, such as the kidney, liver, and intestine; rarely, the change is confined to the spleen. As elsewhere, the change begins in the walls of the smaller arteries; later, the capillary walls are involved, and then the other structures. It is quite peculiar that in the spleen amyloid degeneration occurs in two macroscopically different forms, according to the localization of the process. The degeneration is either diffuse, when it leads to a uniform increase in the size and the consistence of the spleen, which has a characteristic, lardaceous, and glistening appearance, or it is confined to the Malpighian bodies, which are greatly enlarged, glistening, and prominent, appearing on the cut surface as swollen grains of sago (sago spleen). In the former instance the early stages show characteristic changes: the arterial walls are greatly thickened and appear as homogeneous, glistening rings surrounded by the cells of the adventitia. Oblique sections of such vessels appear as solid pieces of amyloid substance. The capillaries are unusually plain and sharply outlined, forming uniformly colored bands, or ribbons, when stained with diffusely staining anilin dyes. In the early stages the epithelium is still present, but this is soon lost here and there. The spaces of the pulp become smaller, and the number of cells is reduced; soon the degeneration spreads to the reticulum, whose fibers become broader and finally coalesce in places; the reticular spaces become lined with flat and spindle-shaped cells, and the amount of blood present is reduced; the follicles also become smaller, but remnants persist into the latest stages.

Sago spleen is different; in this case the degeneration begins in the arteries, which bore their way through the follicles (the so-called arteriæ penicillatæ); their wall

PLATE 23.

FIG. I.—**Spleen in Acute Leukemia.** × 300. The pulp is loaded with mononuclear, small round cells (lymphocytes), and larger cells (myelocytes). 1, Capillary epithelium.

FIG. II.—**Staphylococcal Embolism of the Spleen in Pyemia.** × 70. Two follicles are seen in the field with their arteries in transverse section, filled with colonies or clumps of cocci (stained by Gram's method) (1); between the follicles is the pulp (4); at 2 a clear zone is seen surrounding blood-vessels in transverse section. The follicular tissue consists largely of lymphocytes. The thickened, darker, outer zone is due to the presence of large numbers of leukocytes (pus-cells) —early stages of the embolic abscess.

---

becomes broadened, and the media is changed into a broad, glistening band. The degeneration next extends to the adjacent structures, being at first limited to the follicles, the lymphoid cells of which rapidly disappear, their place being taken by a homogeneous material, which evidently arises from the follicular reticulum. Viewed under higher magnification, the follicles show coalescing cords, which still inclose small groups of lymphoid cells, while the degenerated vascular walls remain clearly defined. Gradually, the follicles become larger and larger, and crowd out the intervening pulp and capillaries, but in pure forms of sago spleen the generally homogeneous and glistening appearance of the pulp is not produced. Occasionally, however, the two forms are combined, the amyloid change taking place in the follicles as well as in the pulp.

The histologic changes in the spleen in leukemia and pseudoleukemia are quite characteristic. These two diseases differ in this respect, that in acute leukemia the proportion between the red and white blood-corpuscles changes greatly in favor of the leukocytes, while in pseudoleukemia there is no such marked increase of the leukocytes, the swelling of the lymphatic organs being, however,

Fig. I.

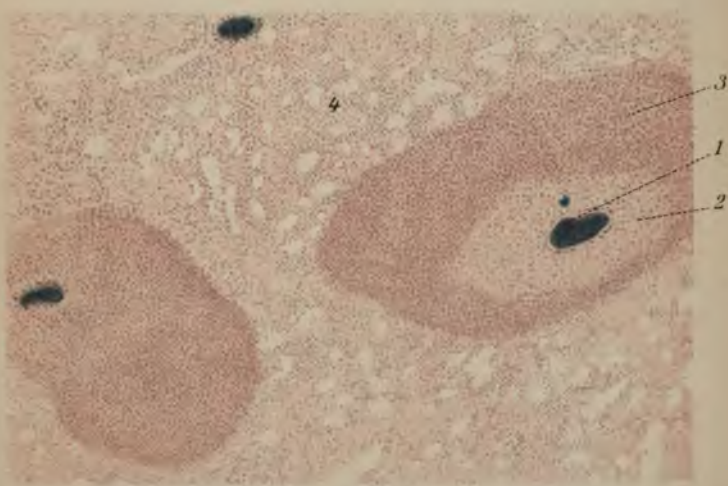

Fig. II.

Lith. Anst. F. Reichhold, München

similar to that in leukemia. In both diseases the volume of the spleen increases to many times above the normal. Acute and chronic changes are recognizable. In the first the spaces in the pulp and the capillaries are widened and filled with mononuclear cells, while the red corpuscles fall into the background and the epithelial cells are only occasionally visible. The Malpighian bodies are greatly hyperplastic, and their limits from the surrounding tissue indistinct. At times the follicles only are enlarged, being readily distinguishable from the darker pulp as grayish-white nodules. In the pure, splenic form of leukemia the small, mononuclear lymphocytes principally predominate. In addition may occur large colorless cells with oval or round nuclei and a granular, eosinophilic protoplasm; such cells are found especially in the so-called myelogenic leukemia.

Later, the lymphatic hyperplasia of the spleen disappears; frequently, larger areas undergo a uniform necrosis, such as is seen in infarcts. There develops a thickened stroma, the reticulum becomes fibrillated, as in the chronic infectious swellings of the spleen, and brownish blood-pigment accumulates about the follicles; finally, the spaces in the pulp become obliterated on account of the increasing amount of connective-tissue formation; only the narrowed capillaries persist. The consistency of the spleen is greatly increased, being often almost wooden.

Tubercles in the spleen are frequently encountered in general miliary tuberculosis. The nodules occur thickly in the pulp underneath the capsule, the follicles generally remaining intact. Larger, conglomerate tubercles in the spleen are observed frequently in children, as well as in many animals, especially swine, guinea-pigs, and monkeys. The histologic structure of the tubercles is the same as that of other organs.

PLATE 24.

FIG. I.—**Tuberculosis of the Spleen.** × 92. Two tubercles are seen situated beneath the capsule: 1, Thickened fibrous capsule; 2, trabeculæ; 3, caseated centers of the tubercles; 4, giant cells.

FIG. II.—**Central Portion of a Spleen-follicle in Diphtheria.** × 745. There are seen numerous, large, polygonal cells with vesicular, swollen nuclei (1), some are filled with small, dark, nuclear fragments (2), also free chromatin granules (3).

THE BONE-MARROW.

In the adult the bone-marrow is the principal seat of production of red corpuscles. The shafts and the distal epiphyses of the long bones contain the yellow, fatty marrow; all other bones, the red marrow. The red marrow consists of an extremely fine reticulum, in which the cellular elements and the vessels are suspended. Here are found, first of all, the so-called myelocytes, or marrow-cells, which are ameboid cells of the type of lymphocytes, but with larger, though less chromatic, nuclei; lymphocytes, such as are found in the blood; large protoplasmic cells with regularly fragmented, lobulated nuclei, or many nuclei,—the giant cells of the marrow, or mye-

---

PLATE 25.

FIG. I.—**Bone-marrow from the Diaphysis of the Humerus in Pernicious Anemia.** × 520. The normal fat of the marrow has almost disappeared. At 1 only a few fat-cells or fat-vacuoles are seen; the number of cells in the marrow is greatly increased; 2, white marrow-cells, myelocytes; 3, the same with several nuclei; 4, nucleated, red blood-corpuscles; 5, cells containing red blood-corpuscles; 6, eosinophilic cells; between the cells a fine fibrillar reticulum.

FIG. II.—**Bone-marrow in Acute Leukemia from the Diaphysis of the Femur.** × 640. The fat of the marrow has disappeared here also. 1, Erythrocytes; 2, myelocytes, greatly increased in number; 3, lymphocytes; between the cells is the reticulum.

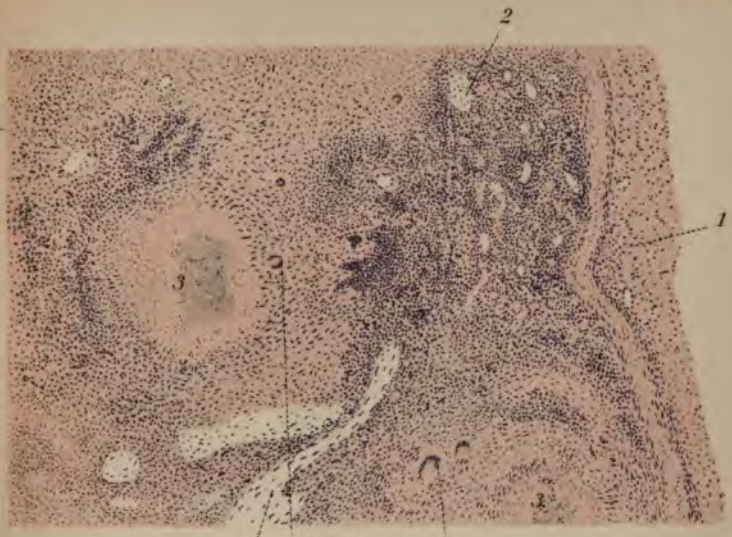

Fig. 1.

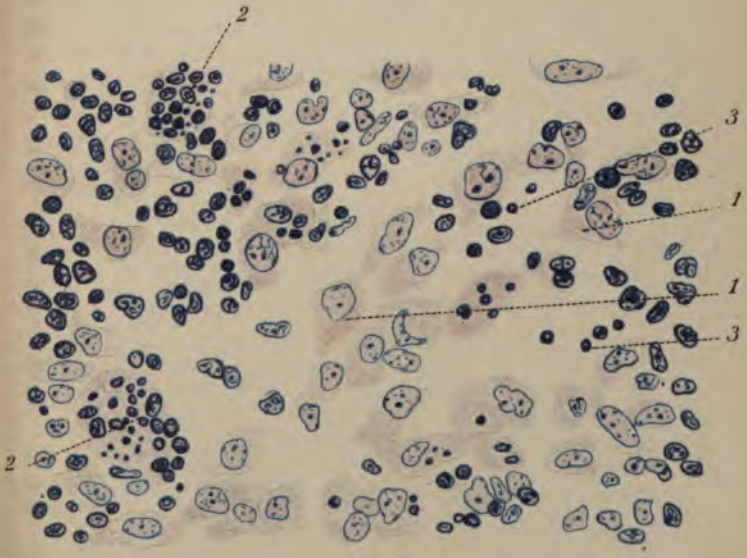

Fig. 2.

Lith. Anst F. Reichhold, München

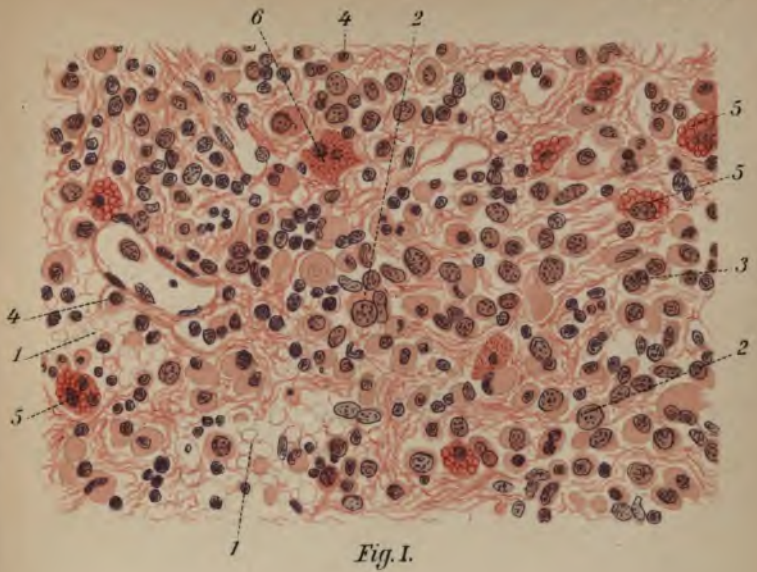

Fig. I.

Fig. II.

Lith. Anst F. Reichhold, München.

loplaxes; nucleated red blood-cells, the forerunners of the erythrocytes; rounded cells, whose protoplasm contains hemoglobin, the nuclei being small and dense; eosinophile cells and red blood-corpuscles.

The venous capillaries of the bone-marrow are wide, and have sieve-like openings in the walls, like the splenic lacunæ.

The yellow marrow consists only of connective tissue and fat; it develops by fatty changes in the red marrow in postfetal life.

The so-called gelatinous marrow is found in emaciated and cachectic individuals, and is the result of fat atrophy in the yellow marrow.

Focal necrosis of the bone-marrow occurs in certain infectious diseases, especially in variola, typhus, and typhoid fever.

The bone-marrow presents quite a characteristic appearance in those diseases that produce changes in the serum and the cells of the blood, such as pernicious anemia and leukemia. In pernicious anemia the yellow marrow of the long bones changes to red marrow, which contains all the elements normally found in this sort of marrow, such as marrow-cells, giant cells, eosinophilous cells, and nucleated red corpuscles. The last, as well as nonnucleated, red corpuscles, may assume a remarkably large size (macroerythrocytes, Ehrlich); some may contain two or more small, dense nuclei. In addition, there are usually found numerous cells containing blood-corpuscles; these cells are presumably marrow-cells, filled with red blood-corpuscles, which have undergone disintegration and have been taken up by the phagocytic cells. The fat-tissue is usually reduced to a minimum.

In leukemia yellow marrow is also commonly changed to grayish-red or red; in the most advanced stages it becomes soft and puriform, as in the myelogenic form of leukemia, in which this change in the marrow is regarded

as a primary condition. The reticulum contains marrow-cells in large numbers—that is, large, round cells with a narrow, protoplasmic ring and large, lightly stained, round or oval nuclei, from which the smaller and dark nuclei of the lymphocytes are sharply differentiated. In this form the blood is also loaded with myelocytes. The fat-tissue may be crowded out completely.

The infectious processes in the bone-marrow, as suppurative and tuberculous osteomyelitis, are considered in connection with diseases of the bones.

II. RESPIRATORY ORGANS.

THE NOSE.

The mucous membrane of the nose is lined with a single layer of ciliated epithelium, except in that part of its cavity known as the auricle, which is covered by stratified, flat epithelium. Under the epithelial covering is a stratum proprium, richly infiltrated with leukocytes. The epithelium of the olfactory region carries the special olfactory cells,—peculiarly transformed ganglion cells,—which communicate with the olfactory lobes by means of nerve-fibers that originate at the base of the cells. The stratum proprium also contains alveolar glands. The loose submucous tissue supports a well-developed plexus of veins.

One of the most frequent pathologic processes in the nasal mucous membrane is the so-called nasal catarrh, or coryza. Histologically, this is characterized by great hyperemia, edema, and increased secretion of the glands, so that many of their cells are converted into goblet cells. Goblet cells also appear among the ciliated surface cells. The leukocytes of the stratum proprium are increased; they penetrate the epithelium and become mixed with the secretion, which, in proportion to the number of cells, assumes a more or less well-marked purulent character. Desquamated epithelial cells also become mixed with the secretion, which, furthermore, contains bacteria among which diplococci and Friedländer's pneumobacillus predominate; staphylococci are also met with.

Should the catarrh become chronic under the influence of long-continued, injurious agencies, then the mucous membrane becomes thicker than normal on account of the extensive development of the veins and of the increase of tissue in the stratum proprium. The stroma of the mucous membrane is infiltrated with young connective tissue and round cells, and the glands are enlarged and greatly convoluted. In the latter stages it is common to find an atrophy of the whole mucous membrane. The glands shrink and disappear; the vessels show a marked thickening of their walls with narrowing of the lumen, which may become wholly closed. The mucous membrane becomes dry, the epithelium falls off or is much atrophied, the cells in the stratum proprium and the submucosa disappear, and a thin layer of stiff connective tissue develops. Such atrophic changes are generally found in connection with processes that are designated as ozena; ulcers in the altered mucous membrane are also occasionally found.

Chronic catarrh of the nasal mucous membrane is not infrequently associated with the development of circumscribed and, later, pedunculated swellings or polypi, the structure of which resembles that of the mucosa; the stroma is fibrous connective tissue, which is more or less swollen by virtue of an accumulation of edematous fluid in its meshes; at times this may give it a typical myxomatous appearance, especially when the fluid contains mucinous substances; the nuclei become spindle-shaped, and when the cell-body can be demonstrated, it is found to present numerous radiating processes. In addition, the spaces of the tissue contain numerous round cells, of the type of lymphocytes, which are found especially numerous in the vicinity of the vessels, and also some polymorphonuclear leukocytes. The glands of the normal mucous membrane are found also in the polypoid outgrowth; not infrequently, the glands show an extraordinary development, and when their

ducts are closed or narrowed, cystic dilatations result, which may become so large and so numerous that they constitute the principal mass of the polyp (cystic polyp). The surface of these new formations are covered with cylindric epithelium—at least, in their earlier stages; later, the epithelium may become much reduced or even wholly destroyed. On the whole, these polyps are best regarded as fibromata, which, when edematous, approach the type of myxomata. The word polyp does not convey any idea of the histologic structure of the growth; it refers only to the gross form—*i. e.*, a pedunculated growth, no matter whether it is a fibroma, sarcoma, or epithelioma.

Infectious processes, such as tuberculosis, syphilis, and glanders, are met with in the nasal mucous membrane. The tuberculous and syphilitic lesions differ in no way from the same processes as they occur in other mucous membranes; and the nodules of glanders, which may develop upon the nasal lining of man and animals, are also composed of epithelioid cells—derived from the fixed cells —and lymphocytes and leukocytes. Central necrosis occurs early, and may lead to perforation of the free surface and the formation of sinuous ulcers.

Diphtheria of the nose, which is not so infrequent, presents no histologic peculiarities, and further reference is made to what is said concerning diphtheria of the larynx, trachea, and the pharynx.

LARYNX, TRACHEA, AND BRONCHI.

The larynx, trachea, and bronchi are covered by a mucous membrane lined with ciliated cells. Each epithelial cell passes through the entire thickness of the epithelial covering, but on account of mutual pressure the form may be varying, such as conic and spindle-shaped. The nuclei are situated at the broadest part of the cell, and,

PLATE 26.

FIG. I.—**Diphtheria of the Trachea.** (Bird's-eye view.) ×18. 1, Cartilage of the trachea; 2, mucous glands; 3, infiltrated submucosa; 4, false membrane on the mucous surface, composed of fibrin and necrotic elements.

FIG. II.—**Diphtheria of the Trachea.** ×130. Weigert's fibrin stain. 1, Infiltrated tissue of the tunica propria; 2, fibrin layer, covering the largely necrotic mucous membrane; 3, remains of epithelium; 4, peripheral layer of the diphtheric pseudomembrane, consisting of nuclear fragments and leukocytes; 5, nonnucleated necrotic masses.

---

consequently, they occur at varying levels, so that at first glance the impression is given of several layers of cells. The thread-like, basal processes of the cells end in a dense, homogeneous basement membrane. Normally, there are found in the epithelium a large number of goblet cells whose protoplasm is the seat of mucoid change. In the larynx, however, the most exposed parts, the parts subjected to the most movement, are supplied with a more substantial and more protective covering—namely, stratified, squamous epithelium; situated upon the basal layer of cylindric cells is the stratum Malpighii with its characteristic prickle cells. The parts thus covered are the free margins of the epiglottis, a part of its upper and lower surfaces, the region between the arytenoid cartilages, and the vocal cords. Under the basement membrane lies a stratum proprium composed of fibrillated connective tissue, elastic elements, and blood-vessels; scattered throughout are numerous lymphocytes. In some points of the larynx and trachea the accumulation of lymphocytes becomes more dense, a true lymphadenoid tissue being formed; and at times complete lymph-follicles result (posterior surface of epiglottis). The stratum proprium of the true vocal cords is, for the most part, composed of stiff, parallel, elastic fibers. The glands

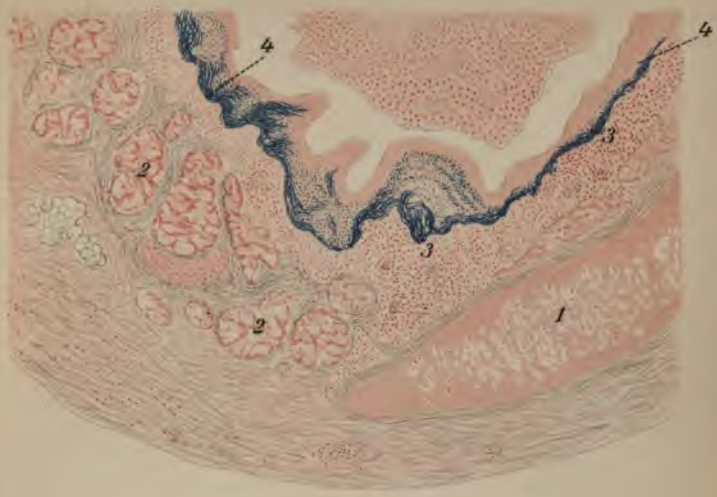

Fig. I.

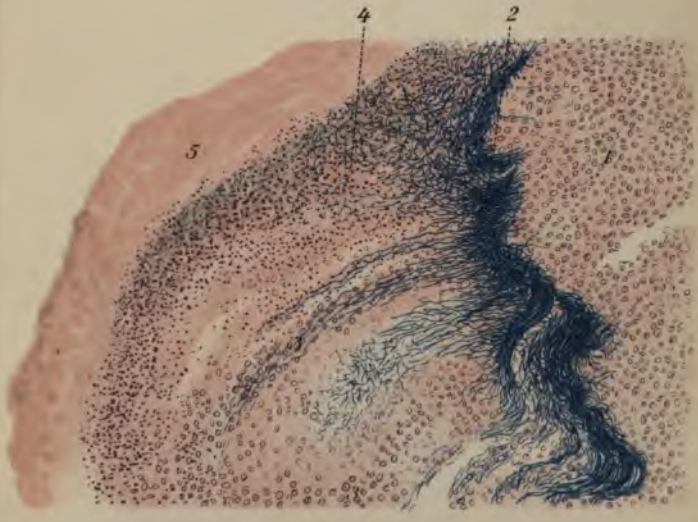

Fig. II.

Lith. Anst. F. Reichhold, München

in the submucosa and in the deeper layers of the stratum proprium belong to the compound, alveolar, mucous glands. The cells, which produce mucus, are cubic or goblet- or balloon-shaped. The gland ducts are lined with cylindric epithelium, which may be provided with cilia for a distance into the duct. There are no glands at all in the true cords. The submucosa of the larynx is separated from the cartilage by muscular tissue ; in the trachea and larger bronchi a small amount of fat and of connective tissue separates the submucosa from the internal perichondrium. The cartilage is hyaline except in the epiglottis, the cartilages of Santorini and of Wrisberg, which are composed of elastic or reticular cartilage. The external surface of all the cartilages is covered by fibrous, external perichondrium.

As in the nose, simple catarrh is the most frequent form of inflammation in the larynx. In the acute form there are diffuse swelling and redness of the mucous membrane. The vessels are distended, and frequently small hemorrhages are observed. The stratum proprium of the mucosa, as well as the submucosa, are more or less crowded with leukocytes, which infiltrate the epithelium also and appear in the secretion. Small losses of substance frequently appear in the epithelial lining. The mucous glands are swollen and in a condition of hypersecretion ; numerous goblet cells appear among the cylindric cells of the lining.

In the course of the infectious diseases, especially typhoid fever, numerous bacteria, principally staphylococci and streptococci, lodge upon the loosened epithelium, which they probably also penetrate. The collection of leukocytes in the mucous membrane increases greatly ; the superficial parts of the infiltrated area may become necrotic, and on being cast off ulcers form whose walls and floors are formed by the pus-cells. In the vicinity the epithelia appear without nuclei, and are often occupied by

PLATE 27.

FIG. I.—**Ulcer of the Larynx in Typhoid Fever.** ×35. 1, The epithelium still present around the border of the ulcer (stratified squamous epithelium, vocal cord); 2, epithelium falling off toward floor of the ulcer, over which it is completely necrotic; 3, bacterial masses; 4, tunica propria of the mucosa infiltrated with leukocytes; 5, sections of blood-vessels; 6, mucous glands; 7, transverse section of striated muscle-fibers.

FIG. II.—**Pachydermia Laryngis.** ×60. 1, Cylindric epithelium; 2, area of transition into (3) stratified squamous epithelium; 4, papillary body; 5, dilated blood-vessels of tunica propria; 6, mucous glands.

---

heaps of cocci. Similar ulcerations occur in the larynx in variola.

In chronic catarrh the entire mucous membrane is thicker than normal, due to infiltration of round cells, which occur chiefly in small masses, and to the increase of the fixed connective-tissue elements of the stratum proprium. The mucous glands are enlarged, frequently their ducts are plugged by secretions, when the overlying epithelium is liable to be pushed forward a little so that the surface of the mucous membrane appears granular (granular laryngitis).

In chronic catarrh of the larynx the epithelial covering is the seat of the most important changes. Where stratified squamous epithelium is present (margins of epiglottis, interarytenoid region, margins of vocal cords), the layers become increased in number, and in the superficial ones hornification is likely to occur. Squamous epithelium may also appear in places normally covered by cylindric cells but which have fallen off; such islands of flat cells may coalesce to form larger areas, which may be recognized macroscopically as whitish, usually definitely circumscribed thickenings of the mucous membrane, known as pachydermia laryngis (Virchow). Underneath the epi-



Fig. 1.

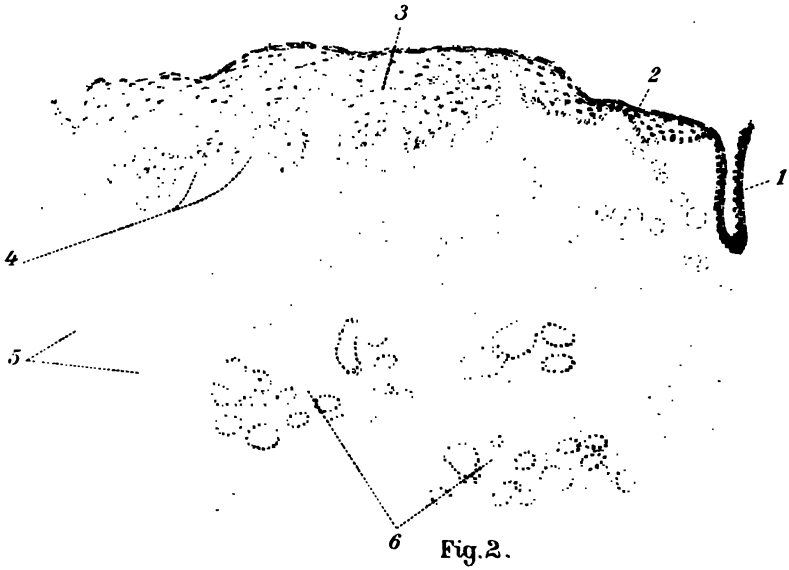

Fig. 2.

Lith. Anst. F. Reichhold

thelium a papillary body may form, the vascular papillæ at times growing in length so that warty excrescences, irregular thickenings, and branching polypoid outgrowths are produced. A large part of the so-called laryngeal polypi owe their development to such chronic catarrhal conditions.

In children croupous and diphtheric inflammations of the upper air-passages are frequent. The characteristic feature of such processes is the formation of fibrinous membranes associated with necrosis of the mucosa. When the membrane is easily removable and only the superficial layers of the mucosa undergo necrosis, the term croup is usually applied; but when the fibrinous membrane extends into the tissue of the mucosa because the necrosis involves the deeper layers of the mucous membrane, then the condition is anatomically a true diphtheric inflammation, no matter whether caused by Löffler's bacillus or by streptococci, or by chemic agents.

In both cases the fibrinous membrane presents a reticular structure. Between the fibrinous threads lie leukocytes and desquamated, more or less necrotic, cells. In croup this layer of fibrin simply covers the mucous membrane, which retains its normal structure though usually thickly infiltrated with leukocytes; the superficial epithelium is the only part that undergoes necrosis, but after the separation of the false membrane perfect regeneration of the epithelium usually takes place. In diphtheria, on the other hand, the precipitation of fibrin extends into the deeper layers of the stratum proprium, which thereby lose their distinctness and become necrotic. Between the layers of fibrin are seen the anuclear scales of the dead epithelium. The gland ducts are usually covered by membrane, so that the secretion accumulates in the glands, which may also fall victims to necrosis. At the border of the necrotic tissue is found a wall of leukocytes of considerable thickness, which cir-

PLATE 28.

FIG. I.—**Tuberculosis of the Larynx.** × 16. The epithelium is completely destroyed and is absent at many places. The free surface is formed by the floor of the tuberculous ulcer, which resulted from the growth of tubercles in the submucosa, and the tunica propria of the mucosa, and upward extension, the tubercles coalescing and breaking through the epithelial lining. At times the caseous centers of the tubercles, and at times their richly cellular peripheries, are seen on the free border of the ulcer. 1, Deep-seated tubercle in submucosa; 2, remains of mucous glands; 3, cartilage.

FIG. II.—**Tuberculosis of a Large-sized Bronchus.** × 54. Epithelium entirely disappeared. 1, Cartilage; 2, mucous glands, the interstitial tissue of which is greatly infiltrated; 3, tubercle, with beginning caseation of the center and numerous giant cells; 4, greatly distended blood-vessels, reaching to the surface of the ulcer.

---

cumscribes the area doomed to mortification. The separation of the dead tissue, infiltrated with fibrin, leaves a deep defect,—the diphtheric ulcer,—which in healing often gives rise to extensive cicatricial deformation of the mucous membrane; usually, the mucous glands are permanently lost in such areas.

Tuberculosis of the larynx is frequently associated with pulmonary tuberculosis, to which it is usually secondary; a primary laryngeal tuberculosis is much more rare. The macroscopic appearances and the histologic characteristics vary greatly. In the early stages are found small, subepithelial, more rarely submucous, nodules, which are composed of round and epithelioid cells, and frequently lift up the epithelium. With increasing growth the central necrosis, which is quite constant, also increases, several neighboring areas may coalesce, or solitary nodules increase and break through the superficial epithelium and discharge the caseous and necrotic material in the center; thus arise sinuous ulcerations with overhanging margins. Simultaneously, the caseating infiltrations may extend

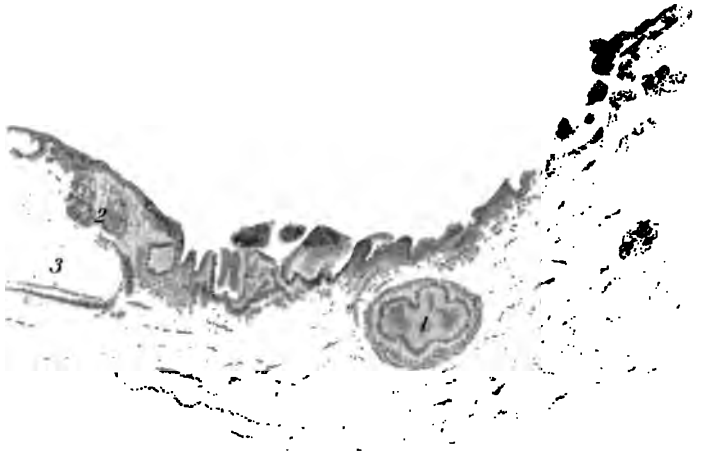

Fig. I.

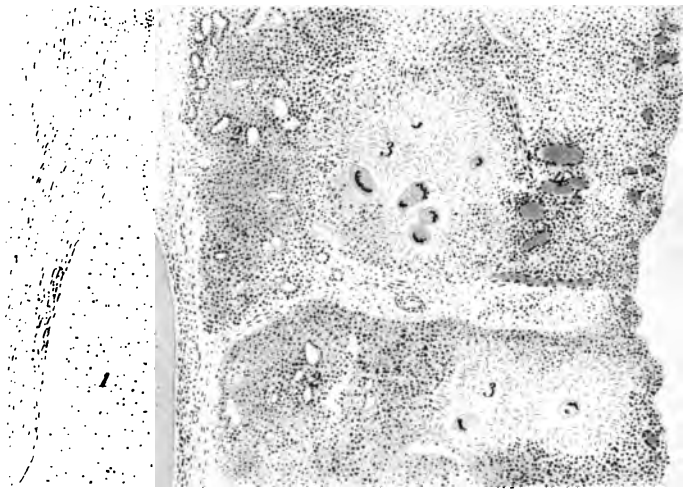

Fig. II.

Lith. Anst. F. Reichhold, München.

downward and involve the perichondrium, which is destroyed, so that the cartilage is laid bare (tuberculous perichondritis), and eventually larger and smaller necrotic pieces may be exfoliated.

In addition to this common form of ulcerative tuberculosis of the larynx other varieties also occur that oftenest are recognized as tuberculosis only by the microscopic examination; in these varieties distinct nodules and ulcers may not be formed, but large, often extensive, polypoid excrescences, composed of a diffuse, tuberculous, granulation tissue with epithelioid and giant cells. Disintegration and ulceration frequently appear late in this so-called polypoid, laryngeal tuberculosis.

Like tuberculosis, syphilis of the larynx may cause granulomatous areas, which disintegrate and form ulcers —gummatous laryngitis; extensive necrosis of the laryngeal wall may result, and especially of the epiglottis, leading to sequestration of large portions. Healing and cicatrization of syphilitic defects frequently lead to extensive connective-tissue formations, followed by contractions and narrowing of the larynx and trachea.

Leprosy and glanders produce laryngeal nodules and ulcers, whose true nature is recognized by microscopic examination and the demonstration of the specific microbes.

TRACHEA, BRONCHI.

The diseases of the trachea and larger bronchi are histologically similar to those of the larynx. The diseases of the smaller and smallest bronchi are to be studied in connection with the surrounding lung tissue.

Acute tracheal and bronchial catarrh manifest themselves by desquamation of the epithelial cells, enlargement of the mucous glands, marked vascular injection, and more or less leukocytic infiltration of the epithelium and stra-

PLATE 29.

FIG. I.—**Ectasia of a Small Bronchus.** ×10. 1, Irregularly dilated lumen; the epithelium, the whole of the mucosa, and a large part of the submucosa have disappeared; at 2 a small portion of cartilage is still present; the wall is greatly infiltrated with round cells, and penetrated throughout with numerous blood-vessels filled with blood (3). Externally, a dense, fibrillar, connective tissue is seen infiltrated with dust.

FIG. II.—**Bronchiectatic Wall.** ×127. (Part of the foregoing section.) 1, Lumen; 2, cartilage; lacunæ in cartilage, dilated and filled with leukocytes; 4, dilated blood-vessels, filled with blood.

---

tum proprium. When the catarrh becomes chronic, then the swelling of the mucous membrane may persist; but in the later stages the opposite may occur—namely, atrophy. The desquamated epithelium is not replaced, the stratum proprium and the submucosa become thin, deficient in cells, stiff, and fibrous; the glands shrink and in part disappear. Macroscopically, the mucous membrane is pale, thin, adherent to the cartilages, and traversed by occasional prominent bands. Frequently, the chronic inflammation is not confined to the bronchial mucosa but spreads to the subjacent structures. The submucous and muscular vessels, and the vessels in the connective tissue outside the cartilages are dilated and filled and surrounded by leukocytes and lymphocytes. The elastic and muscular elements are pressed apart; the leukocytes may penetrate through the perichondrium into the cartilage, the ground substance of which becomes eroded and absorbed. Finally, the cartilaginous spaces are opened and filled with pus-cells and the cartilage cells are destroyed (peribronchitis). (Plate 29, Figs. I and II.) By these processes and through the edema that accompanies the inflammatory hyperemia, the whole wall becomes softened and may give way. If there occurs a hindrance to the outflow of the secretion, or if there is present a strong, positive

Fig. 1.

Fig. 2.

Lith. Anst. F. Reichhold, München.

pressure in the bronchial lumen, as in the case of severe coughing, larger or smaller areas of permanent dilatation may result (bronchiectasis).

Oftentimes the mucous membrane of such dilatations is wholly destroyed, and the lumen is bounded by a greatly infiltrated, richly vascular, connective tissue, the vessels of which are thin walled and dilated; the continuity of the muscle layer is lost, and of the cartilage also, so that there is found only cartilaginous rudiments or islands. In the later stages the connective tissue becomes acellular and avascular, and, finally, the irregularly dilated lumen is surrounded by cicatricial connective tissue.

LUNGS.

As they become smaller and smaller, the branching, arborescent bronchioles lose altogether the cartilage and the mucous glands in their walls; the cylindric, ciliated epithelium diminishes in length, becomes polyhedral and granular, while below the epithelium lies a thin stratum proprium and a circular layer of smooth muscle-fibers, and internally a layer of loose vascular connective tissue with numerous elastic fibers.

In this manner are formed the respiratory or terminal bronchioles. Each continues as a short, tubular structure, the alveolar passage or duct, which in return terminates as a funnel-shaped expansion—the terminal vesicle or infundibulum.

The wall of the terminal vesicle becomes pouched out irregularly into saccular dilatations, generally half-globular in shape, and designated as the alveoli or lung vesicles. These alveoli communicate freely with the infundibulum, and also with one another through minute spaces in their walls—the so-called stigmata of Cohn. The walls of the alveoli and the terminal vesicles, in addi-

PLATE 30.

FIG. I.—**Colloid Goiter.** The glandular acini are dilated (1) and filled with an increased amount of homogeneous, colloid material (stained light red in color). The epithelium (2) is somewhat flattened in places. The connective-tissue septa are thickened.

FIG. II.—**Parenchymatous Goiter with Hyaline Degeneration of the Interstitial Substance.** ×70. 1, Dilated acini partly filled with colloid material; 2, epithelium of the same; 3, hyaline connective tissue, the nuclei of which have disappeared.

---

tion to the small polyhedral cells, are also lined with larger, flat cells, which are extremely thin, clear, and polygonal, and partly nonnucleated. They directly cover the capillaries, which surround the alveoli in the form of a network. When the lung is fully expanded, there are present small openings or stomas between the cells, through which communications between the alveoli and the finer lymph-channels are established. It is believed that it is through these stomas that corpuscular elements are carried by inspiration into the lymph-stream. The layer of smooth muscle is present in the wall of the infundibula in the form of remnants from the end bronchioles, but muscle-cells are not found in the alveolar walls. The framework of the alveolar walls consists of a thin net of elastic fibers that continue directly from the end bronchioles, and of a delicate, fibrillar, connective tissue with star-shaped cells.

A respiratory bronchiole with its infundibula and alveoli is surrounded by a layer of connective tissue that is continuous at the proximal end with the adventitia of the larger bronchial stem, while at the distal end it becomes lost in the connective tissue of the pulmonary pleura. In this way sharply outlined areas result, pyramidal in shape, the bases lying under the pleura, while the apices point toward the hilus of the lung. These areas are known as lobules, and are especially well marked in

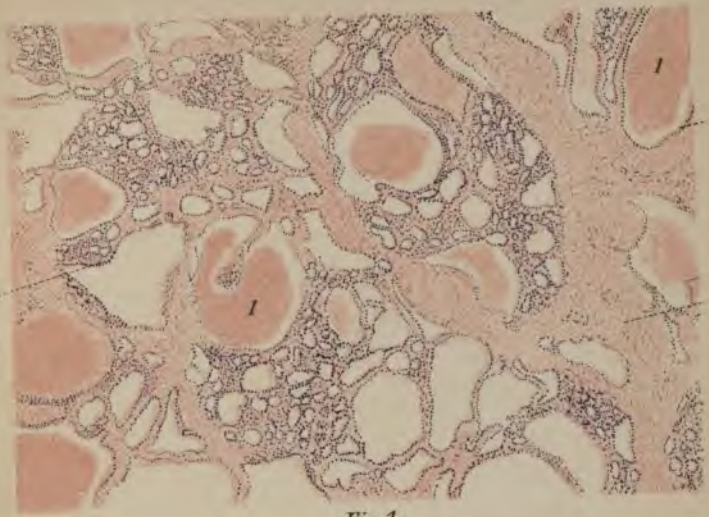

Fig. 1.

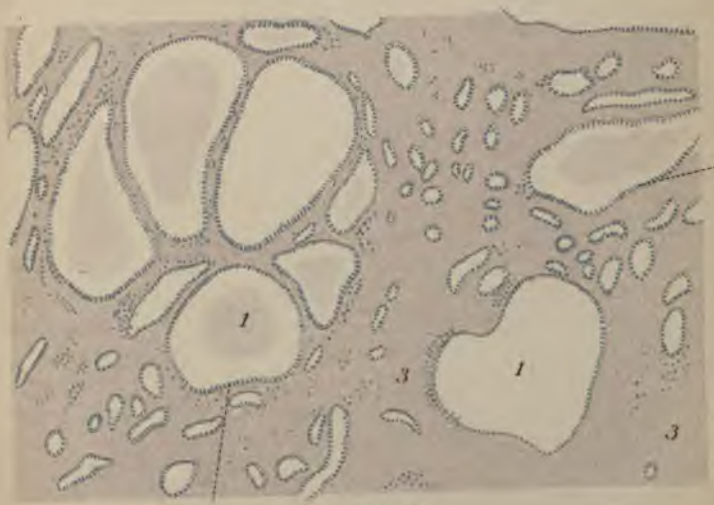

Fig. 2.

the lungs of children and in highly pigmented lungs. The capillaries of the pulmonary artery, surrounding the alveoli, anastomose more or less freely with the capillaries of the bronchial artery.

Normally, the alveoli contain air since the very first inspiration after birth; under pathologic conditions, however, the air may be pressed out either through sinking together of the alveolar walls, which come in contact with each other, or by other substances that completely fill the lumen of the alveoli. The first condition is designated as atelectasis. Its prototype is present physiologically during fetal life. In the fetus no air enters the alveoli; they are not expanded, but lie close together; at this time the alveolar epithelium has nuclei, and the flat, thin, nonnucleated platelets are as yet absent. (Plate 31, Fig. I.) Microscopically, the organ shows a compact appearance. The few spaces present correspond to the lumens of the bronchi and bronchioles, while the infundibula are hardly to be made out.

Under various pathologic conditions part of the whole organ may present the same appearance as during fetal life. This is frequently the case when a part or the whole of a lobe is pressed upon, as by tumors, exudates, transudates, by the enlargement of neighboring organs, etc. The lower sharp borders of the lower lobes frequently become compressed and airless as the result of a high position of the diaphragm. Such conditions are designated as compression atelectasis, in contradistinction to resorption or collapse atelectasis, which is also frequent and due to the occlusion of a larger bronchial stem by foreign bodies, mucus, etc., when the air present in the affected district is gradually absorbed. In consequence, the alveoli collapse because no longer exposed to the pressure of the air, and the alveolar lumens become obliterated.

When sections of this kind are stained to bring out

PLATE 31.

FIG. I.—**Fetal Atelectasis of Lung.** × 70. The alveolar walls are very close together, the alveoli not expanded. The tissue, therefore, appears more cellular than normal, aerated, lung tissue. 1, Bronchioles; 2, infundibula; 3, pleura.

FIG. II.—**Compression Atelectasis of the Lung in Serofibrinous Pleuritis.** × 70. The elastic fibers stained. The alveolar walls with their elastic fibers are approximated and compressed, especially at the peripheral portions. 1, Thickened pleura as a result of inflammation.

---

the elastic elements, the elastic fibers of the alveolar walls and the walls themselves will be found wrinkled or crumpled and in close contact with each other. (Plate 31, Fig. II.) In compression atelectasis the capillaries, in contrast to fetal atelectasis, are mostly empty and hardly visible; while in resorption atelectasis they usually contain the same amount of blood, if not more, than the surrounding vessels. If the cause in either compression or resorption atelectasis is removed in a certain length of time, it is possible for the affected lung area to return to its normal state. The air-cells become inflated, and their walls are smoothed out. If, however, the condition of atelectasis is present for a longer time, then adhesions take place between the folded alveolar septa. First, the alveolar epithelium degenerates, and then the fixed, connective-tissue cells proliferate, and finally lead to the formation of a cicatricial area which remains permanently airless. When the atelectatic area is located at the periphery of the lung, the pleural or subpleural connective tissue takes an active part in the proliferation and formation of the new tissue. The capillaries are frequently in a state of hyperemia and stasis; they may rupture and lead to extravasations into the thickened tissue, with subsequent deposit of pigments.

Resorption atelectasis, when resulting from bronchitis

Fig. I.

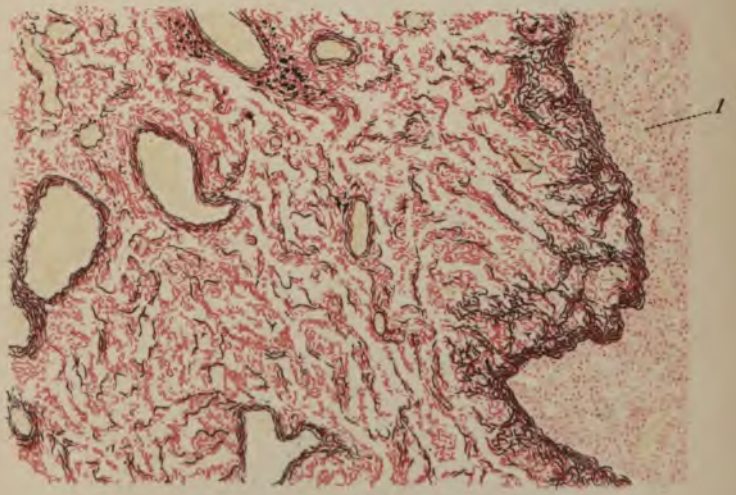

Fig. II.

Lith. Anst. F. Reichhold, München.

(especially in children), is usually a forerunner of inflammatory processes that extend from the bronchial wall down into the airless lung tissue. (See Peribronchitis and Lobular Pneumonia.)

The reverse condition of atelectasis is emphysema of the lung. By this term we understand an increase of the air contained within the lungs. Sometimes it occurs acutely after severe coughing or forcible inspiration, which leads to rupture of the air-passages or spaces, and extravasation of the air into the interlobular septa as well as under the pleura. This condition is designated as interstitial or intervesicular or subpleural emphysema, and shows no changes of any particular interest from a histologic point of view.

Important histologic changes are found, however, in the substantial or vesicular form of emphysema. This consists in the distention of the air-cells or spaces, and a simultaneous disappearance of their walls or septa so that an apparent increase in the volume of the whole organ is produced. Vesicular emphysema must be distinguished from atrophy of the lung, which always occurs more or less in old age and is distinguished histologically from emphysema only with difficulty. The alveoli, first of all, are flattened out, the edge-like partitions which project into the infundibular spaces become shorter, while the infundibula as a result become larger. Constant and increased intravesicular pressure causes the alveolar septa to become extended, stretched, and thinned out. Naturally, this extension first shows itself at those areas where the walls contain minute openings. The stigmas of Cohn are rendered dehiscent, and in the thicker sections they can be recognized on the surface of the alveolar walls as round or oval holes. If the extension continues, the alveoli become confluent with the infundibular spaces in larger areas; the increased rarefaction of the lung and the disappearance of the elastic fibers and blood-vessels produce

PLATE 32.

FIG. I.—**Anthracosis of the Lung.** ×100. The lung tissue is very much indurated as the result of newly formed connective tissue in which are embedded star-shaped masses of fine, granular, blackish pigment of inhaled coal particles.

FIG. II.—**Siderosis of Lung (Red Iron Lung).** ×330. The lung tissue is loaded with numerous masses of iron-dust, which are found mostly within the cells in the thickened alveolar walls, the nuclei being covered by the pigment. Between the pigment cells the connective tissue is fibrillar and contains but few nuclei. Alveoli partly compressed. Atypical, proliferated epithelium in the alveoli.

---

large, bladder-like, thin-walled spaces, varying in size, according to circumstances, from that of a pea to that of a large walnut, and even larger (bullous emphysema). (Plate 33, Figs. I, II, and III.)

The normal elastic fibers, always slightly tortuous or bent, become stretched, give way gradually, and are finally torn in half. The same changes take place in the capillaries in the intervesicular and infundibular walls. Their lumen becomes narrower and narrower

---

PLATE 33.

FIG. I.—**Emphysema of the Lung.** ×40. Greatly dilated alveolar spaces, extraordinarily thin alveolar septa, deficient in cells and torn at many places so that the several alveoli communicate with one another. 1, Interlobular septum; 2, contiguous but normal alveoli; 3, dilated and confluent alveoli.

FIG. II.—**Emphysema of the Lung.** ×340. Two alveoli are seen, whose interalveolar septa are extremely thin, deficient in cells, and about to be torn through in the center.

FIG. III.—**Emphysema of the Lung.** ×54. From an injected preparation.

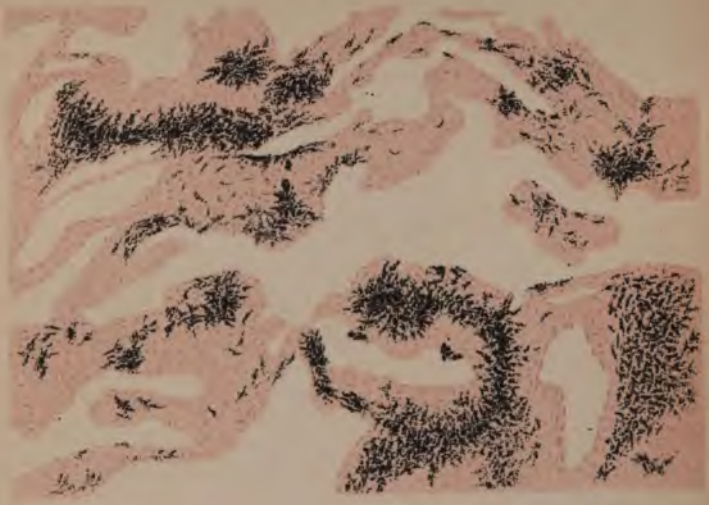

Fig. I.

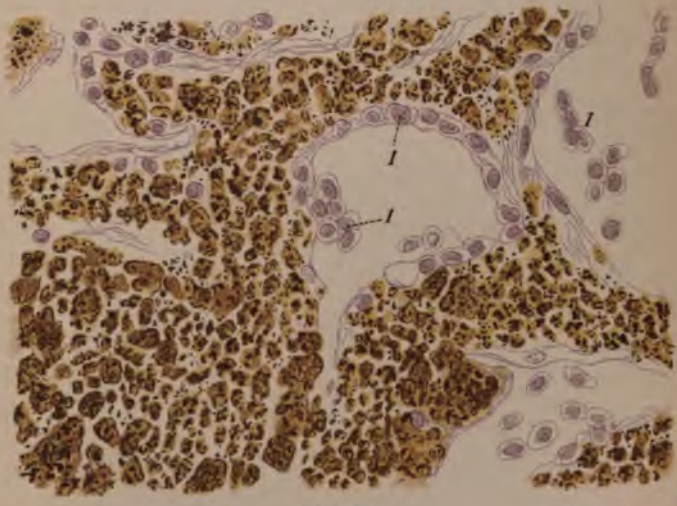

Fig. II.

Lith. Anst. F. Reid

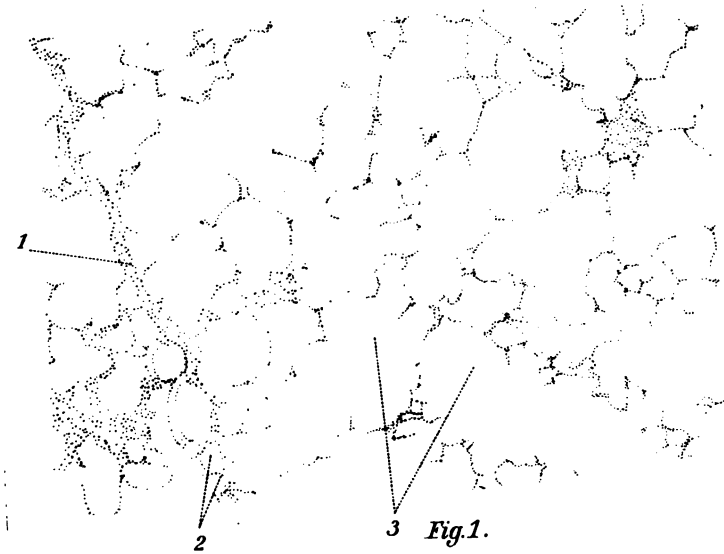

Fig. 1.

Fig. 2.

Fig. 3.

Lith. Anst. F. Reichhold

from the constant stretching, until finally the walls for some distance lie in such close contact that a solid fiber results; eventually this is torn, and the stump may still be found projecting into the dilated space. Rudiments of degenerated or obliterated vessels are especially well shown in injected preparations. In severe forms of emphysema there is also noticed a similar obliteration of the smaller arteries and veins with eventual disappearance of the walls. Naturally, the alveolar epithelium also becomes destroyed through fatty degeneration.

Usually the emphysematous portions are less pigmented than the normal lung tissue. This is due, first, to the fact that the pigment masses lie further apart on account of the widening of the tissues, which macroscopically gives it a lighter appearance, and, secondly, to the resorption of the original pigment inclosed within the alveolar and vascular epithelium, which, on breaking down, sets free the pigment.

Circulatory Disturbances.

In long-continued obstruction to the outflow of blood from the lungs to the left auricle, especially from insufficiency and stenosis of the mitral valves, there results a passive hyperemia of the lungs. Later, the organ increases in consistency, due to hyperplasia of the connective tissue. With the deposition of blood pigments the tissue acquires a brownish discoloration, and the condition is then designated as brown or cyanotic induration.

As a result of the damming back of blood in the veins, the capillaries in the alveolar walls are greatly distended; they become twisted and tortuous, and project irregularly into the alveolar lumen. In this manner the alveolar spaces become contracted and the respiratory surface diminished. (Plate 34, Figs. I and II.) With the increase of intracapillary pressure more or less diapedesis of red

PLATE 34.

FIG. I.—**Brown Induration of the Lung.** ×130. Thickened alveolar septa, due to newly formed connective tissue arranged around the blood-vessels. Large, round cells containing amorphous granular blood pigment partly in the septa and partly within the alveoli (so-called "Herzfehlerzellen").

FIG. II.—**Passive Hyperemia of the Lung.** ×250. 1, Ectatic and distended blood-vessels, filled with blood; 2, engorged and tortuous capillaries; 3, lumen of alveolus; 4, increased interlobular connective tissue; 5, cells, containing blood pigment, within the alveolar lumen; 6, free, amorphous blood pigment.

(also white) blood-corpuscles takes place and, occasionally, rupture of the capillaries. The extravasated blood is found in the alveoli as well as in the tissues of the alveolar septa, and the same changes occur as in extravasated blood in general. Later, the red blood-corpuscles are taken up by the desquamated alveolar epithelium, as well as by wandering cells (lymphocytes and leukocytes), and also by young connective-tissue cells that proliferate from the alveolar walls as a result of the irritation of the hemorrhage. The alveolar lumen and the alveolar septa are then found to contain cells loaded with masses of yellowish or brownish pigment. The pigment-containing cells are expectorated and appear in the sputum as the cells of heart-disease ("Herzfehlerzellen").

The deposit of pigment and subsequent proliferative changes in the alveolar walls lead to thickening of the walls and increased consistency. The elasticity of the tissue is lessened while the respiratory surface becomes encroached upon on account of the continued compression of the alveoli. Sometimes areas of alveoli are completely filled with pigment-containing cells, so that there results a condition of catarrhal inflammation. In addition to blood pigment the cells may also contain coal pigment,

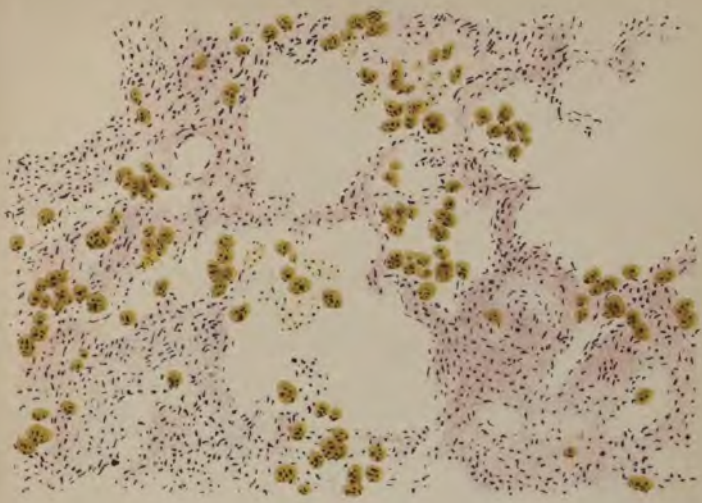

Fig. I.

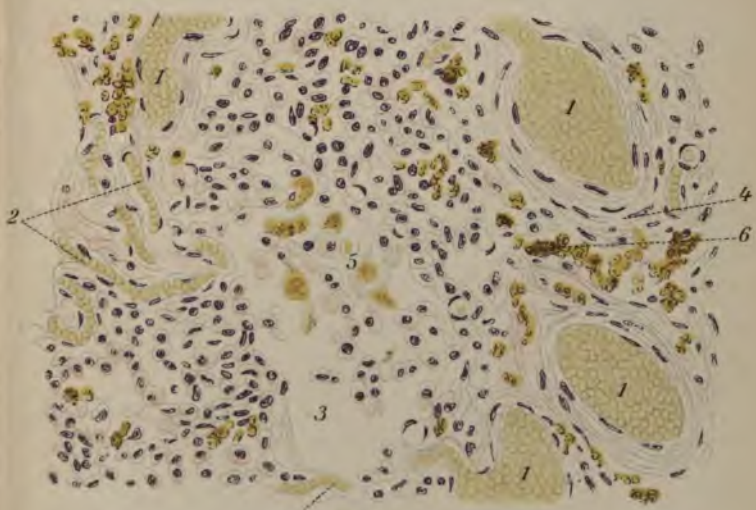

Fig. II.

Lith. Anst. F. Reichhold, München.

which is easily distinguished, however, on account of its black color. When the cells break down, the pigment is set free and is then deposited in the thickened alveolar septa, the peribronchial and perivascular connective tissue, and lymph-spaces as amorphous, hematoidin granules arranged in rows. Hematoidin crystals are rare in the lung.

In severe chronic passive hyperemia there often occurs complete stasis in many of the capillaries. The blood-corpuscles are then changed into pigment within the vessels, and in such instances we find the lumen of the capillaries and the smaller arteries dilated and completely filled with pigment, some of which is inclosed within cells. In obstructed vessels of this kind the circulation entirely ceases.

This form of passive hyperemia must not be mistaken for another that develops in the posterior portions of the lower lobes in cases of heart failure and asthenia—namely, hypostatic congestion. Here we also have dilatation of the vessels with passing out of the red blood-corpuscles into the alveolar tissue. If, in addition, inflammatory changes occur, the process is designated marantic splenization. Likewise, edema of the lung is the result of a passive hyperemia that, however, often occurs first during the death agony. (Plate 36, Fig. I.) It may either develop acutely or in a more chronic way; oftentimes it accompanies inflammation of the surrounding lung area, or it is a forerunner of inflammation, being then known as inflammatory edema. In edema the alveoli are filled with a richly albuminous fluid and cells (alveolar epithelium and round cells). For microscopic examination it is best to preserve the fluid by throwing small pieces of edematous lung tissue into boiling water for one or two minutes. This causes the fluid to become coagulated, and it is found in the alveoli as an opaque, grayish, crumbling, or thread-like mass.

This procedure is advisable when it is necessary to

PLATE 35.

FIG. I.—**Marginal Zone of Hemorrhagic Infarct of Lung.** ×40. 1, Lung tissue in which the alveoli are normal; 2, compressed and airless lung tissue; 3, infarcted lung tissue infiltrated throughout with red blood-corpuscles; the nuclei are poorly stained, and necrosis has occurred in places.

FIG. II.—**Fat Embolism of the Lung, Resulting from Fracture of a Long Bone.** ×100. Fresh preparation. There is seen an infundibulum with several alveoli, in the wall of which are present globular, sausage-shaped, and branched, shining, yellow bodies, partly inclosed within the capillaries and partly free as a result of the teasing.

---

differentiate between edematous fluid in the lung and aspirated water as a result of death by drowning.

Oftentimes the alveolar walls and interlobular septa also become saturated with the edematous fluid. The interstitial tissue is then found swollen and expanded, and the same coagulated mass is seen in the spaces. In inflammatory edema the fluid is often mixed with numerous cells, especially leukocytes.

Infarction.

It has been pointed out that the lung tissue is richly supplied with blood-vessels; therefore, in case of occlusion of an arterial branch the conditions are favorable for the establishment of collateral circulation. For, as a matter of fact, we frequently find on the postmortem table larger or smaller arterial branches of the lung occluded with thrombi without leading to any consecutive tissue changes. This being the case, then the cause of infarction of the lung must be sought for in other injuries of the vessel wall, and this is found in chronic passive congestion. For that reason infarction occurs most frequently in lungs that are the seat of passive hyperemia. (Plate 35, Fig. I.) If in such a lung one of the arterial branches is occluded

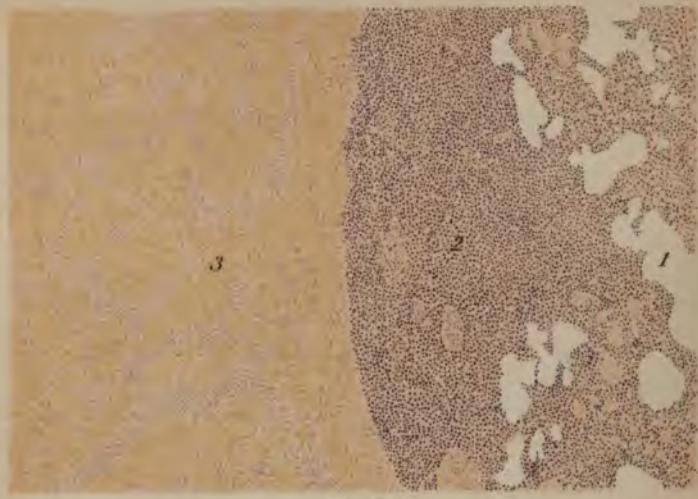

Fig. 1.

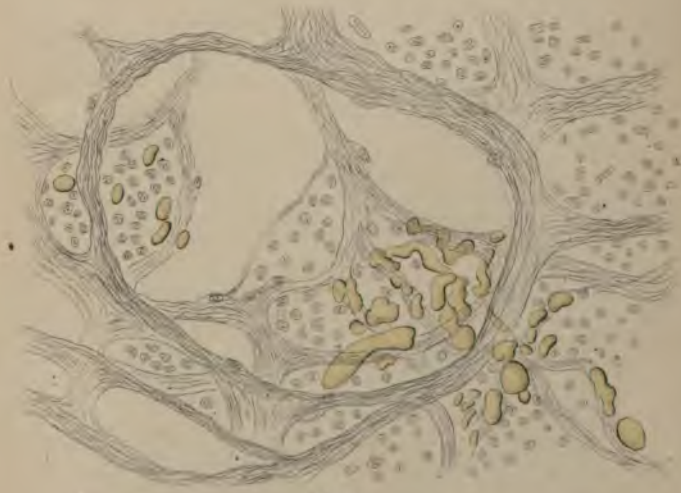

Fig. 2.

Lith. Anst. F. Reichhold, München

by an embolus, the area of tissue beyond the vessel becomes anemic. Blood now flows from the surrounding capillaries into the empty vessels, but the walls have lost their integrity ; the blood-corpuscles pass out, as through a sieve, into the lumen of the alveoli, infundibula, and oftentimes into the smaller bronchi, infiltrating in a diffuse manner these structures. All forms of infarction of the lung are, without exception, hemorrhagic. Anemic infarction does not occur, on account of the peculiar arrangement of the blood-vessels.

At this stage the infarcted lung tissue is found more or less necrotic, manifested by the absence of the nuclei ; while the tissue itself is infiltrated with closely packed red blood-corpuscles. Frequently, the capillaries are occluded with fibrinous or hyaline thrombi, which can be removed as fine bands or strings. Occasionally, fine fibrin threads are demonstrable between the extravasated red blood-corpuscles. The infarcted area is usually sharply outlined from the surrounding tissue.

After the infarct has existed for some time it may become absorbed. The necrotic lung tissue breaks down through fatty degeneration, while the blood is transformed into pigment, which is taken up by wandering cells. The infarct may also become organized—that is to say, it is replaced by granulation tissue that is derived from the surrounding connective tissue, especially the peribronchial —and finally transformed into a fibrous scar. (See Organization, in General Part.)

A form of embolism peculiar to the lung is fat embolism. It occurs after extensive crushing and bruising of the subcutaneous fat-tissue and the fatty marrow of bones, as a result of traumatism or fractures. (Plate 35, Fig. II.) The fat droplets are absorbed by the open veins and transported to the right side of the heart and then to the lungs. It may also occur, though rarely, in cases of spontaneous lipemia, as a result of diabetes. The inter-

alveolar capillaries and, occasionally, the smaller arteries are found plugged with yellowish, transparent fat droplets or fat-globules. These are partly seen singly or in the form of branched or sausage-shaped masses. The fat can be fixed *in loco* with osmic acid or it can be stained with sudan III in frozen sections after hardening in formalin. The sections must not be too thin.

Occasionally, we have pulmonary emboli that are cellular in their nature. Thus, in cases of malignant tumors the metastases in the lung can oftentimes be traced to small emboli of tumor cells. (See Metastasis, General Part.)

True parenchyma cell emboli also occur in the lung. Thus, for instance, after traumatic injury of the liver as well as in the course of the acute infectious diseases and intoxications, liver cells may be carried to the lungs as emboli. Placental cells, especially in eclampsia, and giant cells from the bone-marrow after injury to, or operations on, bones, may also be carried to the lungs as emboli.

Pneumoconiosis.

Dust is constantly carried into the respiratory organs with the inhaled air; some of the dust is caught in the upper respiratory tract by the ciliated cylindric epithelium and again discharged, while the rest reaches the alveoli of the lungs. Even in the trachea and bronchi the inhaled dust particles are found partly inclosed by cells; in the lung tissue the dust is also found either free or intracellular. These cells, which are known as dust cells, are partly small and round, with a darkly granular, richly chromatic, and sometimes lobulated nucleus, while others are larger, flat, and have clear vesicular nuclei. The former are lymphoid elements that have wandered out from the blood-stream, while the latter are desquamated, alveolar, epithelial cells. In the bronchi the cylindric epithelial cells

and the so-called goblet cells are transformed into dust cells. Occasionally, the still adherent epithelium is found filled with dust particles. Sometimes a number of such epithelial cells are detached from the underlying basement membrane while joined, and appear as small, membranous flakes. In cases of excessive inhalation of dust larger areas are found, in which the alveoli are completely filled with dust cells.

The larger part of the free and intracellular dust is again discharged through the bronchi; the rest, however, is retained within the lung and deposited at certain fixed depots. Here it may accumulate in such quantities as to give the tissue a distinct, oftentimes intense, discoloration. The free particles and the dust cells find their way between the epithelial cells of the alveolar walls, through fine stomas in the lymph-spaces of the connective tissue, and from thence into the narrow lymphatic vessels in which the dust, especially coal dust, is closely packed in rows and fills up the lumen. The free granules are swept along by the lymph-stream, while the dust cells, besides a passive, also play an active, part and penetrate into the lymph-stream by their own ameboid movements. Both lymphoid and epithelial cells have this power.

Usually, the dust is found accumulated largely in the inter- and peri-infundibular as well as peribronchial and perivascular connective tissue; in the latter it accumulates in the adventitial lymph-spaces of the small, pulmonary, lymphatic nodules. Here the dust may be arrested for some time; later, it may break through this filter, whence it is transported to the pleura, the pleural, peribronchial, and mediastinal lymph-glands. Not rarely the dust crowds into the walls of the blood-vessels as far as to the internal elastic coat.

Inhaled dust, when present in large quantities, has the power, by virtue of its chemic or physical nature, to stimulate or irritate the lung tissue to an inflammatory

reaction. The protoplasm and the nuclei of the dust cells break down with the formation of fatty granules, while the surrounding alveolar wall is infiltrated with numerous round cells and eventually replaced by fibrous tissue. The alveolar wall finally becomes very much thickened, and there results a small connective-tissue nodule, which contains more or less free pigment granules. Later, the nodule may undergo hyaline degeneration; so much so that it becomes hard to trace its genesis. It is difficult to draw a sharp line between these processes and certain forms of true inflammation of the lungs, which are classed as circumscribed indurative bronchopneumonia (endoperivasculitis nodosa of Arnold).

In long-continued inhalations of dust in large amount such nodular masses may fuse and give rise to extensive indurations.

The pigment masses deposited in the peri-infundibular, peribronchial, and perivascular tissue may excite the latter to similar connective-tissue proliferation, which leads to further enlargement of the indurated areas (peri- and endolymphangitis fibrosa or peribronchitis and perivasculitis nodosa). In the same way similar nodules may arise in the pleura, as in the case of the so-called miliary fibromas of the pleura observed in stone-cutters.

The extent and intensity of the histologic processes described depend upon the kind of dust, as well as on the amount of dust, inhaled. Fine amorphous soot—that is, amorphous coal dust—is found in the lungs of nearly every individual of adult age. This condition is designated as simple anthracosis. Since soot-particles have no sharp edges, indurations are but seldom observed. In exceptional cases, when the deposit is extensive, nodular or larger indurations occur in the lungs. (Plate 32, Fig. I.) The dust of bituminous coal acts more intensely, since the fine, sharp-edged, chip-like particles give rise to considerable irritation and inflam-

mation in the lung tissue. (Plate 32, Fig. II.) This is even more so in case of inhalation of stone dust (chalicosis pulmonis) and metal dust (siderosis pulmonis). In these cases it may lead to circumscribed necrosis of lung tissue, and finally to cavity formation.

Dust that on account of its chemic or physical nature acts injuriously upon the lung tissue produces thereby an increased susceptibility to infection. The predisposition to tuberculosis excited by metal and stone dust is generally known and feared.

Pneumonia.

By the term pneumonia we understand the filling up of the air-cells with inflammatory exudate, as a result of which areas of lung tissue become airless. When the inflammatory irritant acts directly upon the inner surface of the lung, larger portions of lung tissue (one or more lobes) may become simultaneously involved. In that case the inflammatory exudate, which is derived from the alveoli themselves, develops suddenly, and the condition is known as genuine or lobar pneumonia.

More frequently, inflammation of the lung results from extension of a primary affection in the larger or smaller bronchi. It may either spread by continuity—that is to say, along the inner surface of the bronchi, bronchioles, infundibula, and then to the alveoli—or by contiguity—that is, perpendicular to the long axis of the bronchus, spreading transversely outward to the surrounding lung tissue. The inflammation spreads from the epithelial surface to the stratum proprium, and then outward into the peribronchial connective tissue. In this manner develops an area of peribronchitis.

In both instances the pneumonic process that results is designated as bronchopneumonia. Its manner of spreading is lobular in character—that is to say, the inflamma-

tion does not usually extend beyond the limit of a lobule and its accompanying bronchiole.

Furthermore, areas of pneumonic infiltrations may be the result of emboli lodged in the blood-vessels of the lung and containing substances acting as inflammatory irritants. Around the embolic thrombus there usually develops a purulent inflammation (embolic or metastatic pneumonia). Its mode of spreading is not dependent upon the course of the bronchi, but is wholly an irregular one—the so-called insular form.

Finally, inflammation of the lung may be secondary to primary inflammatory affections of the pleura; the inflammatory processes extending usually along the course of the interlobular connective tissue toward the centrally located alveolar areas—the so-called pleurogenic pneumonia.

All the different special forms of inflammation known (see General Pathologic Anatomy) may run their course in the lung; and exudation, cellulation, and emigration share in different degrees in building up the pneumonic infiltrate. Under certain conditions we find the alveoli filled only with a richly albuminous fluid in which are present but a few cells (inflammatory edema or serous pneumonia). The exudate may be fixed *in situ* by boiling portions of the lung tissue. Frequently, this condition is only an early stage of other inflammatory changes. This is due to the fact that the bacteria that we believe cause the cellular or fibrinous form of pneumonia are often found in the inflammatory, edematous fluid in very large numbers. The serous exudate may become cloudy and partly crowded out by the admixture of cells or through the precipitation of fibrin. Occasionally, there are present a considerable number of red blood-corpuscles, so that the exudate is distinctly hemorrhagic in character (hemorrhagic pneumonia). If the process occurs suddenly and extensively, it usually leads to fatal results, and it may then be

recognized upon the postmortem table only. Usually, inflammatory edema occurs in parts of the lung surrounding inflammatory areas (collateral edema), and may appear in the same or neighboring lobes.

Most frequently, the exudate filling the alveoli is cellular in nature from the very beginning ; two types of cells are recognized—first, large, flat, epithelial cells from the alveolar lining, and, second, leukocytes. If the alveolar epithelium prevails and if desquamation is combined with active proliferation, the process is designated as catarrhal pneumonia. On the other hand, if the leukocytes are more numerous or present exclusively, the term purulent pneumonia is employed.

The leukocytes (pus-cells) not only fill the lumen of the alveoli, but oftentimes infiltrate throughout the alveolar septa, infundibular walls, and occasionally the interlobular connective tissue. If the leukocytes accumulate in large numbers, it may lead to larger areas of necrosis. This is frequently the case in the hematogenous, embolic pneumonia.

In nearly all cases there is present in the inflammatory exudate a varying amount of thread-like fibrin, the distribution of which will be referred to later.

In special forms of pneumonia, especially the genuine pneumonia, which is distinguished by the fact that large areas, usually a whole lobe, become simultaneously affected, the inflammatory exudate which rapidly fills the alveoli soon coagulates, so that there appears in each alveolus a plug of fibrin mixed with but few cells. This form is, therefore, known as croupous or fibrinous pneumonia in the strict sense.

As the terminations of pneumonia differ clinically from one another, so, in like manner, the histologic picture is a variable one. The most frequent termination—namely, resolution of the inflammatory consolidation and resorption of the exudate—is manifested by a progressive fatty

PLATE 36.

FIG. I.—**Edema of the Lung.** ×127. Section through a portion of boiled lung. In the somewhat dilated alveoli is seen a grayish, opaque, homogeneous mass (the coagulated edematous fluid) in which are intermingled single, desquamated, alveolar, epithelial cells and leukocytes.

FIG. II.—**Marantic Splenization of the Lung.** ×360. 1, Elastic fibers, sharply outlining an alveolus; in the latter (2) coagulated edematous fluid; 3, desquamated alveolar epithelium; 4, leukocytes; 5, red blood-corpuscles.

FIG. III.—**Beginning Red Hepatization of Lung in Croupous Pneumonia.** ×340. Weigert's fibrin stain. Alveolar walls apparently broadened, owing to the great distention with blood of the capillaries, which are tortuous and project into the lumen of the alveoli. In the alveoli are seen red blood-corpuscles, a few desquamated alveolar epithelial cells, and fine, thread-like bunches of fibrin.

---

degeneration and breaking down of the cells and the fibrin, and gradual emulsification of the fibrinous plugs.

Occasionally, the pneumonic area may become purulent, due to the presence of a large number of emigrated leukocytes and the melting down of the lung tissue; this leads to the formation of an abscess cavity filled with pus. The cause of this result is to be found in the kind and number of micro-organisms present in the exudate. Frequently, partial or total purulent softening may occur in fibrinous pneumonia as a result of the penetration within the exudate of pus-producing microbes.

If putrefactive bacteria gain entrance into an inflammatory area in the lung,—for instance, by aspiration of fluid substances from the mouth,—the exudate may then undergo putrid decomposition; the surrounding lung tissue as well as the part primarily affected may undergo necrosis and putrefaction, large gangrenous shreds being thrown off (termination in gangrene of the lung).

Finally, the various forms of pneumonic exudates, in-

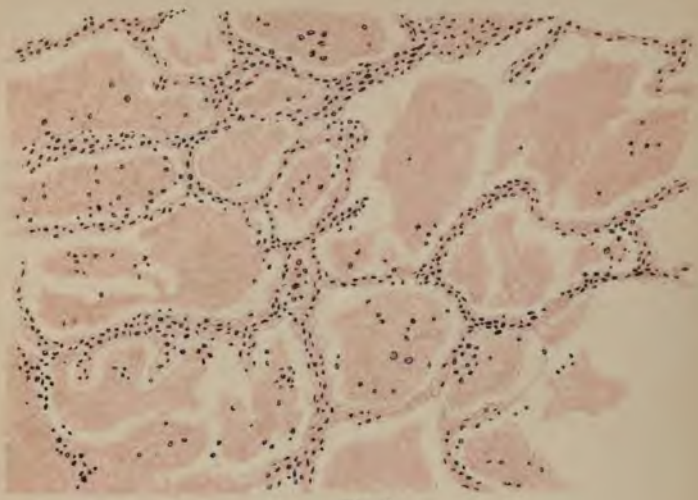

Fig. 1.

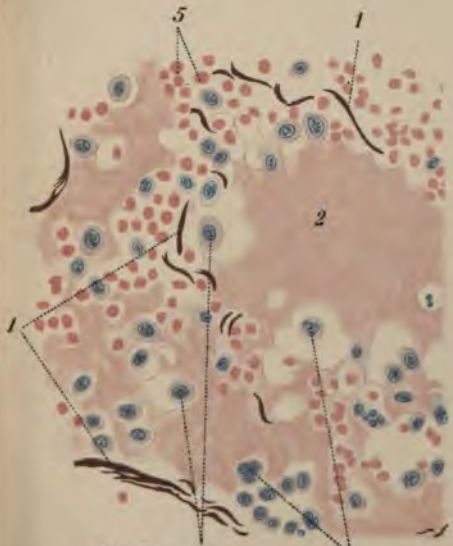

Fig. 2.

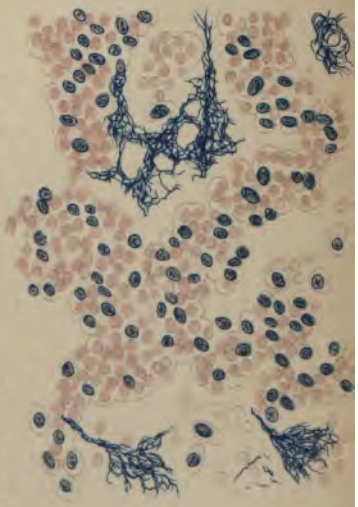

Fig. 3.

Lith. Anst. F. Reichhold., Mü

stead of becoming resolved, undergo organization, the end of which is the filling up and the compression of the lung tissue by fibrillar connective tissue; as a result, larger portions of the lung become converted into a resisting, tough mass. This condition is designated as carnification, because the lung tissue, as a result of this process, has a flesh-like consistence.

Croupous Pneumonia.

Croupous pneumonia is, in a certain manner, the paradigm of a typical inflammation of the lung, and therefore is here considered first. The inflammation starts in the lung tissue proper—that is to say, the alveoli—and affects usually large areas, mostly a whole lobe, occasionally several at the same time, and in rare instances even both lungs. It is characterized by the coagulation of the exudate within the alveoli.

From the microscopic appearances croupous pneumonia is usually divided into four stages, which, however, are not sharply separable from one another, but microscopically they clearly show recognizable differences.

1. The Stage of Congestion.—The affected lung area is highly injected, the capillaries of the alveolar walls are filled to their full extent with blood and partly bulge in a tortuous manner into the alveolar lumens. The latter are filled with a fluid substance composed largely of albumin, which, after boiling small pieces or hardening in the ordinary fixing solutions, appears as a homogeneous, coagulated mass that stains readily with the acid aniline dyes. Even at this stage fine threads of fibrin are found, usually as star-shaped bunches, radiating from particular points upon the alveolar surface ("coagulative centers," Hauser). Among the fibrin are intermingled a few large, vesicular, alveolar, epithelial cells, as well as a variable number of leukocytes and red blood-corpuscles. (Plate 36, Fig. III.)

PLATE 37.

FIG. I.—**Croupous Pneumonia at the Height of Hepatization.** ×88. Weigert's fibrin stain. The infundibula and alveoli are filled with a thick network of fibrin (stained blue); owing to the hardening agent, it has retracted from the walls. In several of the alveoli the exudate has altogether or partly dropped out.

FIG. II.—**Croupous Pneumonia, Stage of Gray Hepatization.** ×360. Weigert's fibrin stain. The fibrin network is beginning to break up (1); at 2 exudate passing through Cohn's interalveolar spaces; 3, leukocytes; 4, alveolar epithelium mixed with exudate.

---

2. *The Stage of Red Hepatization.*—The hyperemia still continues, but the separation of fibrin has increased in proportion, so that the affected lung area has more of a liver-like consistence.

The fibrin threads fill the alveoli in the form of plugs or skeins that are more compact at their periphery, while the central parts are looser in structure, inclosing within the meshes some leukocytes and swollen or broken down alveolar epithelium. The cells and fibrin are not necessarily uniformly distributed; there is usually a sort of a lobular arrangement, the cells being found most numerous within the bronchioles and the central alveoli, while the peripheral alveoli contain principally a fibrinous exudate (Bezzola). At many points fibrinous bands are found to pass over from one alveolus to another through their walls, and form interalveolar bridges. Occasionally, the bridges consist of single fibrinous threads, oftentimes of whole bundles, with their broad bases toward the skeins in which they become lost.[1]

At times we see fibrinous deposits within the capillaries of the alveolar walls, in the larger arterial and venous branches, as well as within the lymph-vessels of the interlobular connective tissue. (Plate 37, Figs. I and II.)

[1] Formerly, it was believed that the spaces were the result of the pneumonia, but the investigations of Hansemann have shown that they are normally present in the lung (Cohn's stigmas).

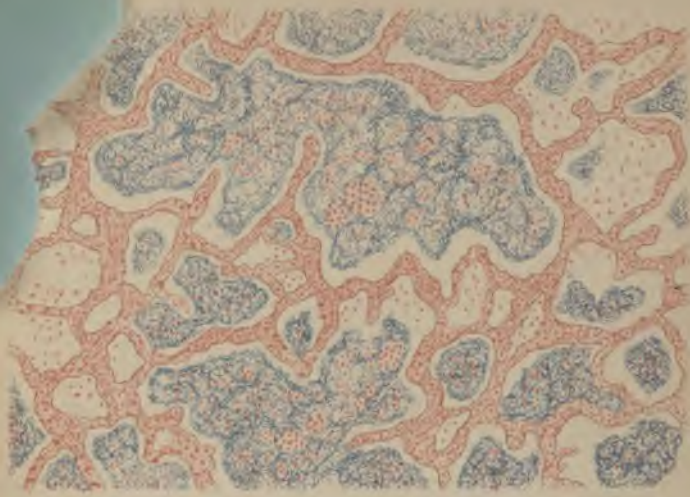

Fig. 1.

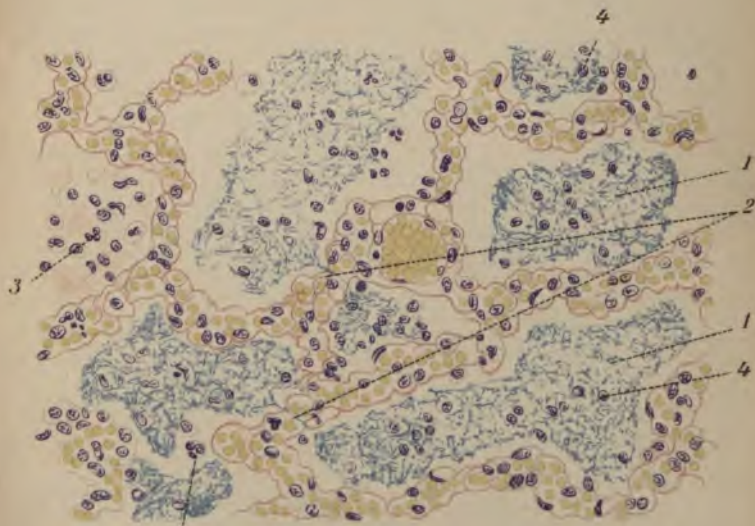

Fig. 2.

Lith. Anst. F. Reichhold, München.

3. Gradually, the condition passes over into the third stage—*the stage of gray hepatization.* The cut surface is granular, due to the projecting fibrinous plugs ; it is grayish in color, explained by two factors—namely (1) the depletion of the alveolar capillaries, caused by the increased pressure of the ever-increasing fibrinous exudate, and (2) to the retrograde metamorphosis of the exudate itself. At this stage the cut surface, when scraped, will yield an opaque, puriform, viscid, juicy substance. The latter, when freshly examined, is found to be composed of fatty plugs, partly of shining, fibrinous masses, and of cells which have undergone marked fatty changes. Stained sections will show the exudate to be partly broken down into fine, molecular granules, or changed into thick clumps that give the fibrin reaction but do not show the single threads of which they are formed.

4. The exudate, which gradually softens and becomes similar to an emulsion of milk, is expectorated and absorbed, and finally the stage of gray hepatization passes into the fourth stage — the stage of *resolution or lysis.* This stage is recognized histologically by the complete disintegration of the fibrinous network and of the cells, and by the gradual emptying of the alveolar spaces. The lung tissue, as a rule, is wholly restored.

The specific micro-organisms which are looked upon as the causative factors of croupous pneumonia are, in the first place, the diplococcus pneumoniæ of Fränkel and Weichselbaum (micrococcus lanceolatus), less frequently, pneumobacillus of Friedländer (bacillus mucosus capsulatus), and sometimes the pyogenic staphylococci and streptococci. As a rule, the bacteria are demonstrable microscopically in large numbers in the early stages of the inflammation. They are seen sometimes in thick clumps, especially in the central lobules, which contain many cells and but little fibrin. [It is exceedingly probable that the micrococcus lanceolatus or the diplococcus

PLATE 38.

FIG. I.—**"Carnification" of the Lung, Following Croupous Pneumonia.** × 170. Stained with orcein. There is passing into the alveoli, which are sharply outlined by the staining of the elastic fibers (1), a dense, fibrillar, and somewhat richly cellular, connective tissue in the form of loops or garland-like bundles (2); at areas is still recognized the swollen, partly desquamated epithelium (3).

FIG. II.—**Organization of the Exudate in Bronchopneumonia.** A proliferating connective-tissue shoot within a small bronchus. × 200. 1, Epithelium of bronchus; 2, plug of connective tissue.

---

pneumoniæ is the essential cause of croupous pneumonia, the other bacteria met with being due to a secondary, mixed infection.]

The regular typical course of croupous pneumonia depends evidently on the vitality of the micro-organisms in question; with the death of the latter disintegration of the exudate soon follows.

Occasionally, resolution does not take place; the fibrin may disappear, but in its place the leukocytes increase. The latter fill the lumens of the alveoli, break through their walls, and infiltrate the lobular septa of connective tissue. In this way, as a result of either a continued increase or growth of the pneumococci (Zenker) or through subsequent infection with pus organisms, pneumonia is succeeded by either focal or more extensive suppuration and destruction of lung tissue. Not infrequently, especially in cachectic individuals, in children, and in the aged, putrefactive bacteria may gain entrance through the bronchial tract into pneumonic areas, or areas previously the seat of purulent infiltration, and set up a putrefactive destruction of the lung—gangrene and sequestration.

In croupous pneumonia the stage of resolution is sometimes retarded; the fibrin remains present for an unusually long time, and finally becomes replaced by the in-

Fig. 1.

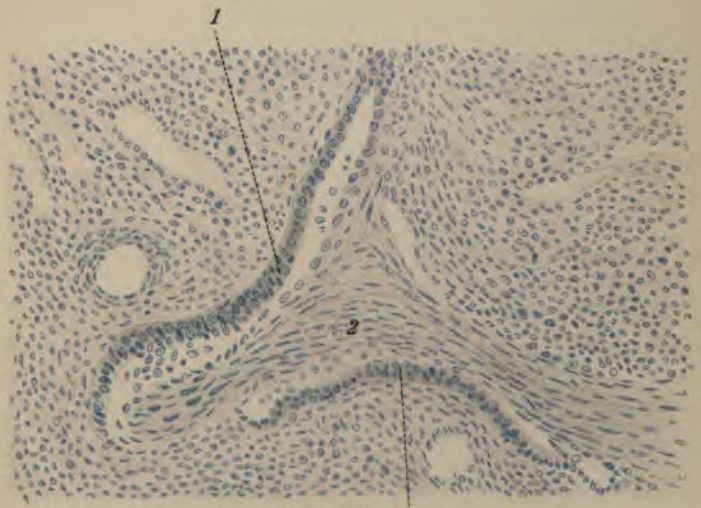

Fig. 2.

Lith. Anst. F. Reichhold, München

growth into the alveoli of fibrous tissue. The latter eventually converts portions of lung tissue into a resisting, flesh-like mass — carnification, or chronic fibrous pneumonia.

In sections of this kind (chiefly when stained especially for elastic fibers) there will be seen shoots of spindle-shaped, connective-tissue cells (fibroblasts) breaking through the alveolar walls and passing in a wreath-like manner from alveolus to alveolus, filling up and distending the lumens. The connective tissue is moderately cellular, especially in the central portions of the shoots, in which are seen richly protoplasmic, epithelioid cells, as well as dark, small, round cells. An increase in the thickness of the alveolar walls does not usually take place. The rather scanty vascular connective tissue does not, therefore, originate from the alveolar walls, but rather from the scanty connective tissue surrounding the end bronchioles. Sometimes the shoots also penetrate into the finer bronchioles. The unresolved fibrin seems to play the rôle of bridges, which the connective tissue follows in passing through Cohn's spaces, which become dilated. Polypoid connective-tissue plugs are seen penetrating into smaller bronchioles, and finally occluding them. Detached alveolar epithelium may still be found within the alveoli and near the connective-tissue shoots. Occasionally, these shoots become lined with extensive rows of cuboid epithelium.

Quite frequently, there is seen a proliferation of the remaining epithelium of the alveoli not altogether filled with the connective-tissue plugs. These new cells do not remain flat and low, but become higher, cuboid, oftentimes cylindric in shape, so that adenoma-like structures result (Friedländer's atypical proliferation of the alveolar epithelium). This atypical proliferation occurs in all those processes in which the lung tissue becomes indurated, including tuberculosis and syphilis, and depends undoubt-

edly on the removal of the pressure of the air on the walls of the partially occluded alveoli.

Naturally, such fibrous, "carnified" portions of the lung are rendered useless for respiratory purposes. In such areas are sometimes found glistening, concentrically lamellated, globular bodies, the so-called corpora amyloidea. (See General Part.)

Bronchopneumonia.

All the remaining forms of pneumonia (with the exception of the tuberculous) are macroscopically distinguished, in the early stages, by the appearance of circumscribed areas of inflammation, usually affecting single lobules. Through confluence of many lobules it may lead to larger areas of infiltration: sometimes a whole lobe may in this manner become solidified. When this occurs, it is known as "pseudolobular" extension. All these forms of pneumonia are most commonly the result of extension from a primary infection of the smaller bronchioles. A simple catarrhal inflammation of a bronchiole may spread to the surrounding lung tissue, which the bronchiole supplies. Usually, the bronchial stem becomes occluded by the accumulation of cells and increased mucous secretion, as a result of which the alveolar area that it supplies collapses and becomes atelectatic. Later, these collapsed alveoli become distended, not with air, but with cellular elements, especially with alveolar epithelium. The latter find their way into the lumen partly through desquamation and, on the other hand, as a result of active proliferation. Some of the cells are still flat and polygonal in shape, while others have become swollen, vesicular, or globular, and may easily be distinguished from other cellular elements by their vesicular nuclei. Around tuberculous areas in the lung similar forms of pneumonia may develop (desquamative pneumonia of Buhl, see Tuberculosis).

In the later stages these cells become mixed with a variable number of leukocytes as well as red blood-corpuscles which have passed out from the alveolar capillaries. Fibrin is not found in the purely catarrhal forms of bronchopneumonia ; if present, it is only met with in limited amount. Macroscopically, the cut surface of such inflammatory areas is always smooth. Resolution takes place through fatty degeneration of the cells that fill the alveoli.

A form of consolidation that resembles catarrhal pneumonia very much in structure is the so-called marantic splenization of the lung. It is usually found in connection with long-standing, hypostatic congestion, especially when edema is also present. (Plate 36, Fig. II.)

Complicated in structure as well as in genesis is the so-called lobular pneumonia that occurs secondarily to various other diseases, and especially in children after the acute infections, such as diphtheria, measles, scarlatina, smallpox, whooping-cough, influenza, etc. These forms of pneumonia are also of bronchiogenic development, but the inflammation, instead of extending along the long axis of the bronchial tube into the corresponding lobule, spreads into the bronchial walls and the surrounding peribronchial tissue, whence it passes over into the neighboring groups of alveoli. Since the latter do not belong to the lobule supplied by the affected bronchus, the typical lobular arrangement of the consolidation is disturbed, and there are produced variously sized, rounded, elongated or circular, infiltrated areas, which surround a bronchus and are not confined to the lobular limit or border. Transverse sections through a bronchus and its surrounding lung tissue will show, even macroscopically, the central yellow-stained portion—namely, the bronchus—filled with the purulent exudate, and its infiltrated wall, while the periphery of the nodule is deeper in color.

Microscopically, the bronchus is filled with pus-cells

PLATE 39.

FIG. I.—**Beginning Catarrhal Pneumonia.** × 250. In the alveoli is seen a purely cellular exudate; the latter consists of large, swollen, polygonal or round, alveolar, epithelial cells (1) and a few leukocytes.

FIG. II.—**A Peribronchial Inflammatory Area with Beginning Extension into the Surrounding Lung Tissue.** × 80. 1, Lumen of small bronchus filled with pus-cells and cocci (diplococcus pneumoniæ and streptococcus); 2, epithelium of bronchus infiltrated with leukocytes; 3, muscularis, also infiltrated with leukocytes; 4, peribronchial tissue greatly infiltrated with leukocytes; the blood-vessels are greatly dilated; 5, the infiltration extends to the walls as well as to the lumen of the adjacent alveoli.

---

as well as detached cylindric epithelium, sometimes in rows, and also numerous micro-organisms. The connective tissue and muscular layers are densely infiltrated with leukocytes; sometimes the muscle-fibers are so pressed apart by the pus-cells that they are hardly recognizable. The blood-vessels of the bronchial wall are greatly distended with red blood-corpuscles, oftentimes occluded with fibrin and leukocytic thrombi. The surrounding alveoli are not sharply outlined, as their walls are also infiltrated with polymorphonuclear leukocytes filling the lumen. The composition of the exudate is a variable one, especially as regards the amount of fibrin present, and its manner of distribution is often irregular. (Plate 39, Fig. II.)

There are cases of bronchopneumonia in which the exudate is purely cellular, in other instances fibrin predominates at the peripheral alveoli of the lobule, while in the central ones the cellular elements of the exudate predominate. Sometimes areas are found in which single fields can not be distinguished from a typical croupous pneumonia. The fibrinous plugs are quite numerous, while interalveolar fibrin threads and bundles are also

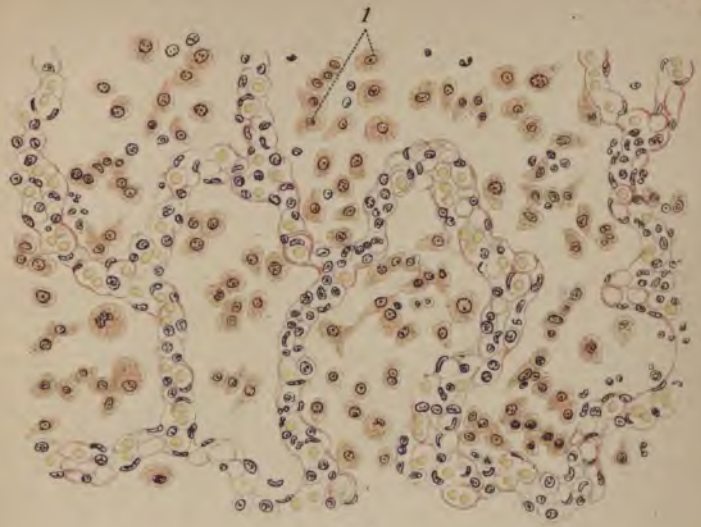

Fig. 1.

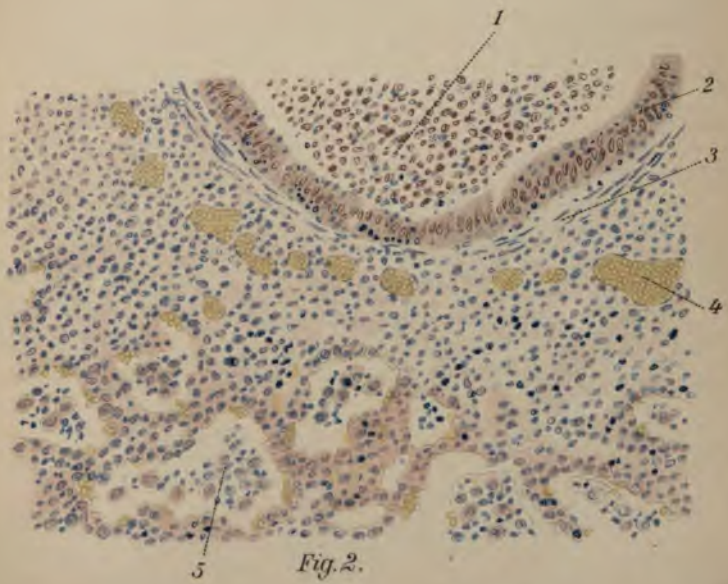

Fig. 2.

Lith. Anst. F. Reichhold, München.

present, and oftentimes the fibrinous exudate extends into the bronchi themselves, from which it may also start. The variability of the exudate does not depend so much upon the kind of micro-organism present as upon their number. The micro-organisms that are found are the diplococcus pneumoniæ (Fränkel-Weichselbaum), the streptococcus pyogenes, the pyogenic staphylococci, the pneumobacillus of Friedländer, the diphtheria bacillus, the influenza bacillus, and the tubercle bacillus which is found in the bronchopneumonia around tuberculous areas.

Generally speaking, it may be said that the amount of fibrin found is in inverse proportion to the number of bacteria present; in other words, the greater the number of bacteria, the smaller is the amount of fibrin. The whole process really depends upon the chemotactic action of bacteria on the leukocytes. (See General Part, Inflammation.)

Under peculiar circumstances there are formed in the exudate of the alveoli a larger or smaller number of giant cells, especially in cases of postdiphtheric pneumonia and in cases following measles. They are seen in the alveoli as massive, polynuclear, occasionally extraordinarily large-sized, polygonal, or irregularly pointed cells that inclose within their cytoplasm a number of white blood-corpuscles, nuclear and cellular fragments, and clumps of fibrin. (Plate 40, Fig. II.) These cells are formed by the conglutination of a number of detached, alveolar, epithelial cells, as well as by the multiplication of the nucleus in the cell without subsequent division of the cell-body. Occasionally, they are found in fibrous indurated lungs, resulting from the "atypically proliferated" epithelium.

The embolic and pleurogenous forms of pneumonia have been mentioned. The embolic forms are often accompanied with the formation of infarction; this occurs when bacteria alone do not reach the lung, but are car-

PLATE 40.

FIG. I.—**Purulent (Lobular) Pneumonia Following Diphtheria.** × 250. 1, Bronchus filled with pus-corpuscles and loosened epithelium, the latter in form of rows. The wall of the bronchus is infiltrated with leukocytes (pus-cells). Alveolar septa contain greatly injected blood-vessels. The alveoli are filled with a purely cellular exudate, composed largely of leukocytes and partly of desquamated epithelium.

FIG. II.—**Postdiphtheric Lobular Pneumonia.** × 280. Weigert's fibrin stain. The exudate in the alveoli is partly cellular and partly fibrinous (2); capillaries of the alveolar walls are greatly injected; the cellular material in the alveoli consists largely of leukocytes, less so of alveolar, epithelial, and giant cells (1). The giant cells are the result of the melting together of a number of the alveolar epithelial cells; their protoplasmic bodies are filled with various kinds of detritus, nuclear fragments, and particles of fibrin, etc.

---

ried there by an embolus in which they are inclosed. The most frequent points of origin are infectious thrombi in veins in various parts of the body: for instance, the uterine veins in puerperal septicopyemia; more rarely, endocarditic vegetations in the right side of the heart. First, there is formed a hemorrhagic infarct in the affected area that soon becomes infiltrated with leukocytes as a result of the peculiar action of the micro-organisms, and more or less purulent softening of the surrounding tissue (embolic abscess) soon takes place. The picture of an insular pneumonia in this instance is of brief duration, as the process of softening of larger areas is soon accomplished. Sometimes the clump-like masses of cocci are visible with the low power.

Tuberculosis.

The histologic appearance of pulmonary tuberculosis is extremely varying and polymorphous. Formerly, before the discovery of the tubercle germ led to the establishment

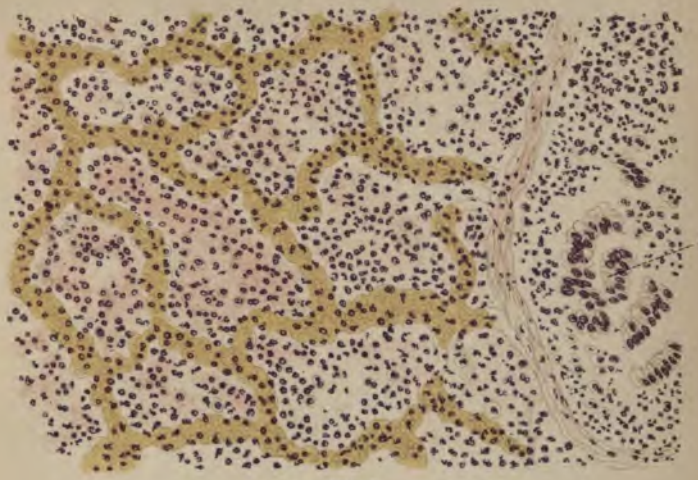

Fig. I.

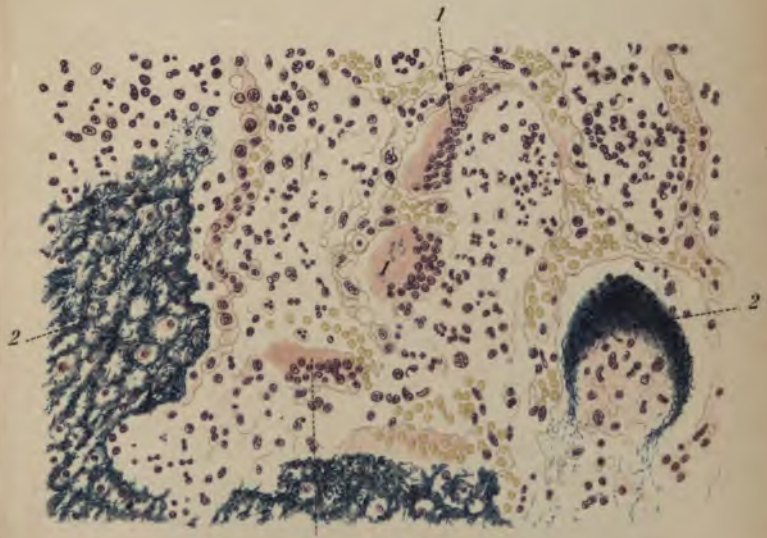

Fig. II.

Lith. Anst. F. Reichhold, München

of their etiologic unity, these processes were looked upon as a series of distinct diseases (phthisis, caseous pneumonia, cirrhosis, etc.).

The localization, distribution, and course of the tuberculous diseases of the lungs are so manifold that it becomes well nigh impossible to consider these processes from a common histologic standpoint. All the forms of inflammation and their several terminations, which were referred to previously, may run their course side by side with the specific tuberculous processes; no organ in the body undergoes so many alterations from tuberculosis as the lung.

The tuberculous virus may reach and spread throughout the lung along three distinct routes: the circulating blood, by inhalation through the bronchi, and by way of the lymph-vessels. In the first case we speak of a hematogenous or embolic tuberculosis, or of an acute miliary tuberculosis, because in this case the tuberculous eruptions at the time of death generally reach the size of millet seeds. This form of tuberculosis most frequently develops as the result of a tuberculous focus in some part of the body—*e. g.*, a tuberculous lymphatic gland rupturing into a vein, the infectious material being carried by the blood to the right heart and thence into the lungs. A somewhat similar event occurs after the rupture of a tuberculous focus into a larger lymphatic vessel, followed by a transport of tuberculous material into the circulating blood. Circumscribed miliary tuberculosis of parts of the lung tissue may result from the breaking into an arterial branch of a preexisting tuberculous focus in the lung itself.

In all these cases there circulate in the blood tubercle bacilli that, if arrested in the capillaries, produce multiple, miliary, embolic, tuberculous foci, the beginning of which takes place in the capillary walls and their immediate surroundings.

As elsewhere, tubercle bacilli in the lungs cause first

a proliferation of the fixed tissue cells. The capillary endothelium, the connective-tissue cells of the alveolar septa, the alveolar epithelium in the neighborhood of the bacilli begin to proliferate, and there are produced the so-called epithelioid cells that form the basis for the pulmonary tubercle. At this stage a purely cellular nodule is found, usually surrounded by the elastic fibers of the alveolar walls, and projecting into the adjacent alveolar or infundibular lumen. Under the influence of this nodule the alveolar epithelium begins to desquamate at the same time that inflammatory exudation also occurs, so that a varying amount of fibrin is deposited in the affected alveoli and around the cellular nodules. Histologically, the pulmonary tubercles of hematogenous origin differ in no way from miliary tuberculopneumonic foci that develop in lymphogenic or bronchiogenic tuberculosis of the lung. Several adjacent tubercles may coalesce with one another, thus giving origin to large conglomerations of tubercles, which for some time remain microscopically distinct.

In acute general miliary tuberculosis the nodules do not, as a rule, reach beyond the stages just described. Occasionally, such nodules are found in the lumen of an infundibulum or an alveolus ; their localization is readily seen in preparations in which the elastic fibers are stained by special methods. It is then seen that, according to age, the cellular or more or less caseous centers are encircled by the elastic fibers of the walls of these spaces.

The epithelioid cells may form giant cells in varying numbers. Frequently, giant cells are seen with numerous protoplasmic pseudopods extending out and becoming lost in the reticulum of the tubercle. (See General Part, Tuberculosis.) With increasing growth there develops in the center of the cellular complexus a caseous necrosis which steadily advances.

The forms of tuberculosis that begin in and spread

along the bronchial tree or the lymphatic vessels, while presenting the same histologic changes in their inception, differ markedly in their further course.

By far the most frequent mode of tuberculous infection of the lung and of the body as a whole is by way of the inspiration. Through the respiratory passages the bacilli reach the small bronchial branches, where they become arrested and produce in the walls the earliest changes, or they reach the infundibula or alveoli, where the specific changes then develop. In the first case processes develop similar to those seen in the evolution of bronchopneumonia. Bronchitis, peribronchitis, and bronchopneumonia develop successively, the inflammation extending through the bronchial wall into the surrounding tissue; histologically, these changes are modified only in so far as the specific effects on the tissues of the tubercle bacillus come into play. There is formation of nodules and then the caseous necrosis, which, as a rule, befalls tuberculous tissue at a certain stage.

It may be assumed that the bacilli are arrested in a plug of mucus in a small bronchus, and next come in contact with the epithelial cells of the walls; the toxic action of the bacilli at once induces a proliferation of the cells and leukocytic emigration, and a bronchial tubercle is formed. The nodules enlarge; the smaller the bronchus, the sooner the nodules coalesce; caseation occurs, and the caseous centers soon run together and form a partial or complete caseous ring around the bronchial lumen. At this point the neighborhood of the bronchus is extensively involved; the nodules spread to the external layers of the bronchial wall, which are destroyed and included in the caseous ring. Caseous material either partially or wholly fills the lumen, and, in consequence, the corresponding alveolar area sinks together in atelectasis. Furthermore, the peribronchial connective tissue and the alveoli adjacent thereto present consecutive changes: the alveolar walls are

PLATE 41.

FIG. I.—**Embolic Abscess of Lung in Pyemia.** × 75. (Insular, embolic, purulent pneumonia.) Around the blue stained coccal masses lie a great number of leukocytes in the alveolar lumens and septa. The lung tissue is in part undergoing purulent softening.

FIG. II.—**Caseous Bronchitis.** × 40. Transverse section through a small bronchus and surrounding lung tissue. The wall of the bronchus is completely broken down, caseated (1), its lumen partly filled with the cheesy material (2). The tuberculous process extends in a circular manner outward to the surrounding lung tissue; the alveoli of the latter are infiltrated and filled with numerous confluent tubercles (3).

---

infiltrated with numerous round cells and appear thickened; in the alveolar lumen a lively desquamation of the epithelium occurs, and the cells are mixed with red and white blood-corpuscles; at certain points large accumulations of leukocytes appear, which obscure the outlines of the alveolar walls. Fibrin, in greater or less quantity, may also be precipitated in the surrounding alveoli; in brief, at a short distance from the caseated bronchus there exists a typical bronchopneumonic focus, which at first presents nothing to betray its tuberculous origin; gradually, the picture changes, however; tubercle bacilli enter this zone also, either directly by virtue of their own proliferation, or, more frequently by far, they are imported by wandering cells. And now there appear in the walls of the alveoli new nodules, which grow eccentrically while central necrosis takes place; or, when bacilli are present in large numbers, the cellular exudate already present in the alveoli undergoes caseation to a larger extent, so that now a focus of caseous pneumonia results.

Further inflammatory changes of a consecutive nature also develop in the lobule of the occluded bronchus. The atelectasis is succeeded by a lively proliferation and des-

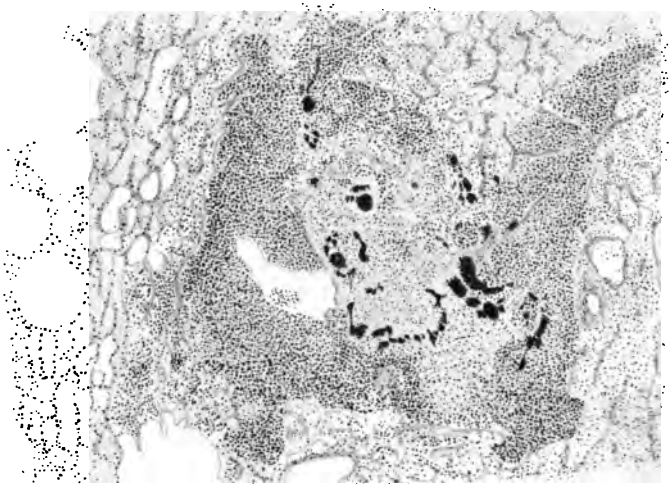

Fig. I.



Fig. II.

Lith. Anst F. Reichhold, München

quamation of the alveolar epithelium, which fills the alveolar spaces; often some fibrin is also precipitated, and this gives the tissue a certain compactness and a peculiar gelatinous consistence. In the absence in the closed alveoli of all interalveolar pressure on part of the air-current the proliferating epithelium frequently assumes the cubic and atypical forms referred to, which bear such resemblance to glandular epithelium. The connective tissue of the interlobular septa, or the peribronchial tissue, if not already tuberculous, may inaugurate the same processes of organization that are seen in the common pneumonia, and that lead to fibrous induration and obliteration of the pulmonary area involved. Frequently, however, the collapsed and gelatinous lung tissue becomes infected with tubercle bacilli, either from the surrounding tuberculous bronchopneumonia or from the tuberculous plug in the bronchial lumen, and in this case it undergoes a rapid caseous necrosis (caseous pneumonia). When fibrin is present in larger quantities in the alveoli, then it may—as also the elastic tissue in the alveolar walls—resist the necrotic action of the bacilli longer than the cells in the alveoli. The bodies of the cells run together, and the individual cells are no longer distinguishable, but disintegrate into a finely granular, opaque mass; peculiar distortions occur in the nuclei which undergo fragmentation, the resulting particles often retaining for a long time their affinity for stains. Gradually, this process extends to the cells of the alveolar walls and destroys the epithelium, the capillaries, and the connective-tissue fibers and cells. At this stage the necrotic lung tissue may still contain dense, easily stainable plugs of fibrin; even the interalveolar connecting bands may be retained. Eventually, the fibrin also disintegrates, leaving only the elastic fibers, which, as a rule, break up into segments arranged in rows before disappearing. Finally, there result larger areas composed of an unstainable and almost structureless

PLATE 42.

FIG. I.—**Miliary Tuberculosis of the Lung.** × 35. The tubercles are caseated in the center (2), and are surrounded by air-containing, alveolar tissue (1); at parts the tubercles are so close to each other that larger nodules are formed; giant cell (3).

FIG. II.—**Caseous Pneumonia.** Weigert's fibrin stain and elastic-fiber stain. × 70. The tissue has undergone complete necrosis; nuclei can not be recognized either in the alveolar walls or in their lumens; in the latter are seen an opaque, granular (cheesy) detritus with some chromatin fragments; 3, well-preserved fibrin is seen in the peripheral parts, and a few alveoli are filled with closely packed fibrin, as is seen in croupous pneumonia; the elastic fibers in the alveolar walls (1) and blood-vessels (2) are still well preserved.

---

material,—the caseous material,—which is rather dry and wholly bloodless, hence the well-known yellowish-white color. The blood-vessels in areas of caseous pneumonia are usually stopped up by fibrinous and leukocytic thrombi—a dense network of fibrin adhering to the intima.

Tuberculous bronchopneumonia, and caseous, circumscribed pneumonic foci are commonly succeeded by a further spread of the tuberculous process through the lymphatic system. The lymph-vessels run parallel with the bronchi and with the vessels, being situated in the peribronchial and perivascular connective tissue; their roots and radicles are, therefore, inclosed in the tuberculous granulation tissue in the forms of pulmonary tuberculosis now described, and bacilli naturally find their way into the lymph-current, by which they are then carried further. In this way multiple tubercles form in the lymph-vessels themselves, which, on account of the resulting swellings, may appear as strings of beads, as they run around the bronchi. This may be properly designated as peribronchial tuberculous lymphangitis.

In this case the tubercles originate from the lymphatic epithelium. The concentric enlargements extend, on the

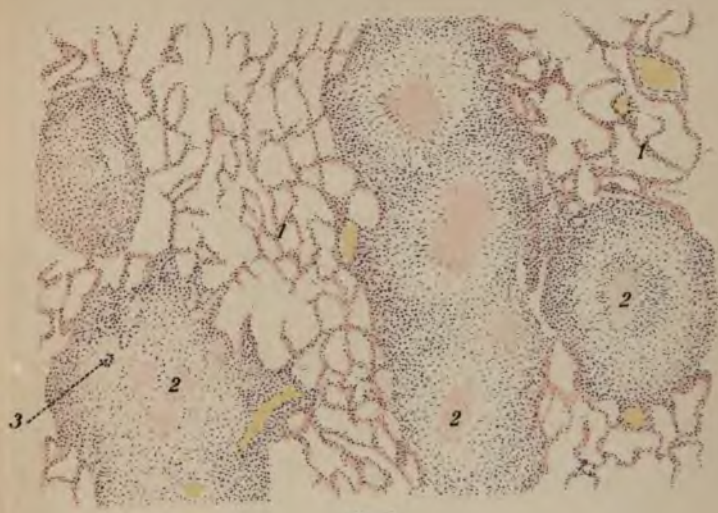

Fig. 1.

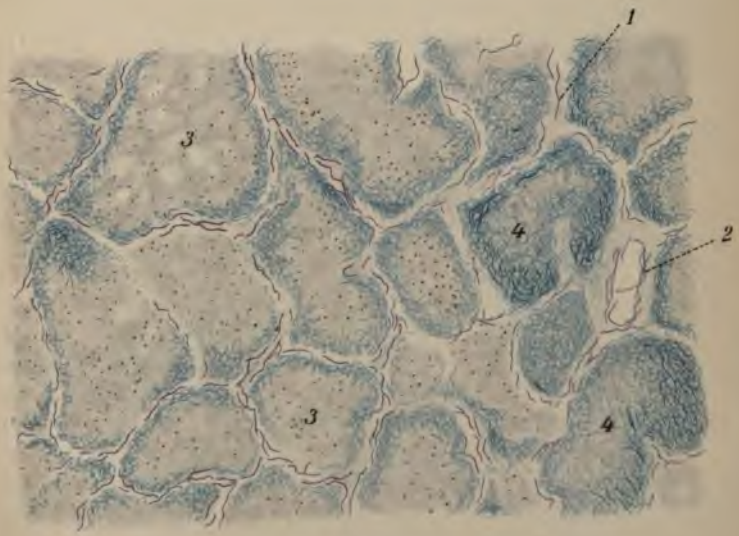

Fig. 2.

Lith. Anst. F. Reichhold, München.

one hand, toward the bronchi; on the other hand, toward the surrounding alveolar tissue. When several lymph-vessels in the circumference of a bronchus become tuberculous, then caseous rings may form around the bronchi, due to the circular confluence of spreading tubercles which may attack the bronchial wall secondarily, and eventually extend to the lumen. It sometimes happens that in favorable sections of a pulmonary lobe the yellowish, nodular cords can be followed with the naked eye clear to the hilus, where they end in the peribronchial lymph-glands. In the latter stages of the disease, when the confluent nodules have destroyed the bronchus and invaded the surrounding tissue, the exact genesis of the disease can no longer be followed.

When the tubercle bacilli enter the alveolar tissue directly through the bronchi, which is often the case in the apices of the lungs, then there develops a minute pneumonic infiltration in case the bacilli remain; or they may be taken up by wandering cells and carried into the lymph-vessels of the interstitial tissue, become arrested here, and induce the formation of nodules. In the first case there is produced a miliary, tuberculous pneumonia; in the second, a pulmonary tubercle. But the histologic differences as to position and mode of further spreading are early obliterated, because the interstitial tubercle very soon causes pneumonic changes, while the primary foci in the alveoli, in their turn, soon induce interstitial changes. In the beginning the alveolar foci consist principally of proliferated, alveolar epithelium and wandering cells, while the interstitial foci are built up by connective-tissue cells and vascular epithelium. From the resulting epithelioid cells giant cells are formed with pseudopodial processes extending into the reticulum of the tubercle; the protoplasm of the giant cells frequently contains tubercle bacilli as well as disintegration products of such. In general the giant cells are the more numerous the

PLATE 43.

FIG. I.—**Miliary Tuberculous Pneumonia.** × 170. Weigert's fibrin stain and elastic-fiber stain. Several alveoli adjoining each other are filled with a cellular and fibrinous exudate. The cells consist largely of desquamated epithelium ; some of their nuclei have not taken the stain (beginning caseation). The attached alveolar epithelium is undergoing proliferation.

FIG. II.—**Caseation of the Exudate in an Alveolus in a Case of Caseous Pneumonia.** × 360. Elastin staining. The alveolus is filled up with a grayish, fine, granular mass, containing a larger number of nuclei which are undergoing degeneration. The cell-bodies are no longer visible.

---

slower the process of nodule formation; in the rapidly spreading, diffusely pneumonic, and extensively caseated forms giant cells are often absent. As elsewhere, the center of the nodules, after a time, becomes caseous, and larger caseous areas result from the confluence of groups of nodules.

The further fate of such isolated tuberculous foci may vary much. The form of healing through connective-tissue encapsulation is relatively common. In this case the exudation does not progress further into the adjacent alveolar groups, but from the margins of the nodules

---

PLATE 44.

FIG. I.—**Desquamative Pneumonia (Buhl) Around a Tuberculous Area of the Lung.** × 340. 1, "Atypically proliferated," cuboid, and cylindric, alveolar epithelium ; 2, desquamated, vesiculated, swollen, alveolar, epithelial cells ; 3, epithelial cells loaded with anthracotic pigment.

FIG. II.—**Proliferation and Desquamation of the Alveolar Epithelium in Tuberculous Pneumonia.** × 520. 1, Fibrin plug in an alveolus ; 2, interalveolar fibrin bridge (Cohn's stigma) ; 3, proliferated alveolar epithelium partly detached from the underlying membrane ; 4, elastic fibers of the alveolar wall.

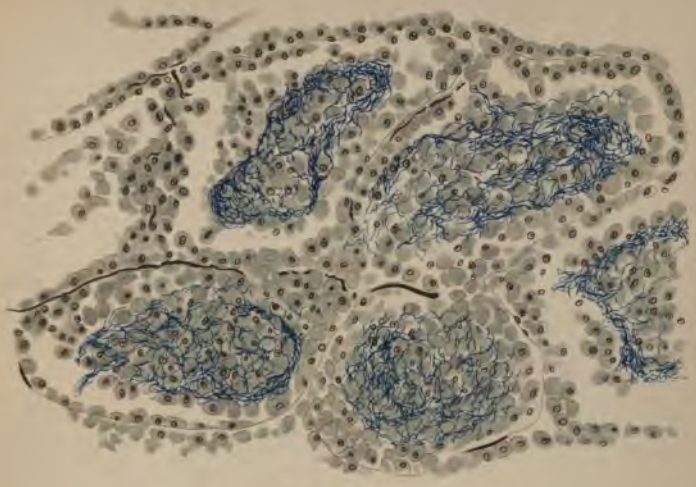

Fig. 1.

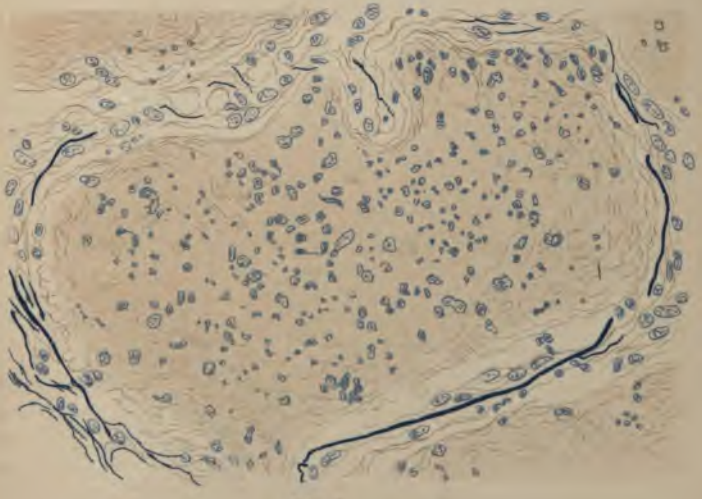

Fig. 2.

Lith. Anst. F. Reichhold, München.

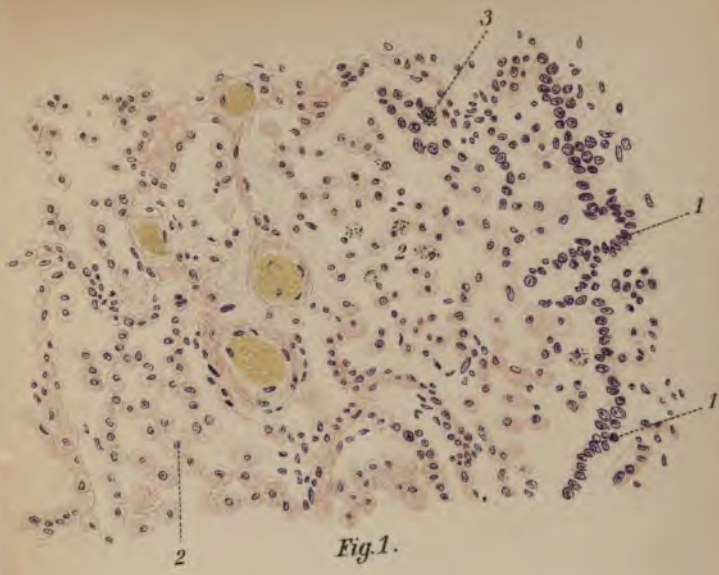

Fig. 1.

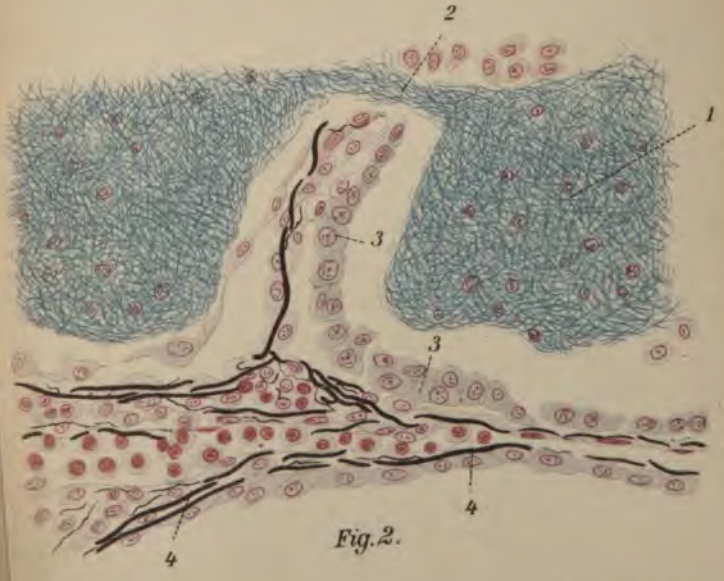

Fig. 2.

Lith. Anst. F. Reichhold, München.

springs a cellular connective tissue which gradually becomes more and more fibrous and less cellular at the same time as it surrounds and encroaches upon the caseous zone; the epithelioid cells, which often are arranged in a radiating manner around the caseous center, and also the more peripheral round cells, disappear, and in their place connective-tissue bands appear derived from the interstitial tissue, especially the peribronchial. The advancing connective tissue frequently takes up the giant cells, which may remain inclosed with the new tissue. The caseous material dries up more and more, and shrinks, and calcareous salts are frequently deposited here; the caseous focus, at first soft and gritty, later becomes converted into a dry and brittle calcareous mass. The connective-tissue formation is not always limited to encapsulation of a preexisting focus, but may assume a more progressive character and give rise to a cirrhotic induration of the surrounding tissue; fibroplastic sprouts, similar to those observed in the organization after lobar pneumonia, grow into the alveoli, fill up the lumens, and eventually change the tissue into a hard, cicatricial mass. Such scars are favorite places for the deposition of coal pigment, which is scattered about in stellate and spindle-shaped groups between the fibrillæ as well as in the persisting cells (slaty induration). The alveoli immediately adjacent are often the seat of a vicarious emphysema. (Plate 45, Fig. II.) The epithelium of the alveoli that are not obliterated often assumes a cubic form, giving rise to gland-like spaces and tubules. (Plate 44, Fig. I.) If living tubercle bacilli are not present in the caseous or calcareous focus, then the tuberculosis is to be regarded as healed.

But the course is not always so favorable as this; frequently, indeed, does the opposite happen—namely, softening and solution of the foci. Two conditions are to be considered in connection with this process—namely, the mechanical and the infectious.

PLATE 45.

FIG. I.—**Wall of a Tuberculous Cavity in the Lung with Cirrhosis of the Apex.** × 16. 1, Cavity; 2, shreddy, caseous masses; 3, closely fibrillar fibrous tissue with anthracotic pigment; 4, compressed alveoli with proliferating epithelium.

FIG. II.—**Slaty Induration of the Lung in Obsolete Fibrous Tuberculosis (Cirrhosis).** × 55. 1, Emphysematous lung tissue; 2, an indurated area of lung, composed of a close, fibrillar, and slightly cellular, connective tissue (scar), infiltrated with masses of black pigment.

If the tuberculous focus either starts from a bronchus or a bronchiole or reaches them in the course of its extension, then the bronchial wall becomes involved in the necrotic process; no longer able to withstand the inspiratory pressure, the wall dilates, and in the necrotic district there results a cavity which is in connection with the bronchus—the so-called bronchiectatic cavity. Such cavities may arise in the smaller bronchi and, by amalgamation, form larger, irregular caverns.

The majority of the cavities, however, are the result of mixed infections with pneumococci, streptococci, etc., which reach the tuberculous pneumonic areas with the air. This mixed infection leads to a softening of the caseous material and a progressive suppuration at the periphery of the focus; sooner or later the focus empties itself through a bronchus. The innermost layer of the walls of a cavity like this consists of necrotic tissue containing innumerable tubercle bacilli; the adjacent layers are infiltrated very densely with leukocytes; following the evacuation there ensues an active and productive inflammation, the result of which is the production of a connective-tissue sac around the cavity; this sac has a structure similar to the slaty induration around caseous foci; coal pigment may be deposited in fibrous lamellæ, and the epithelium of the adjacent alveoli may assume a cuboid form.

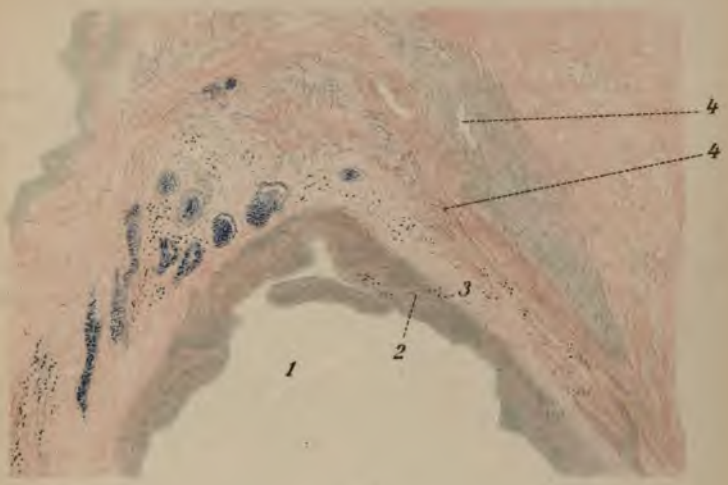

Fig. 1.

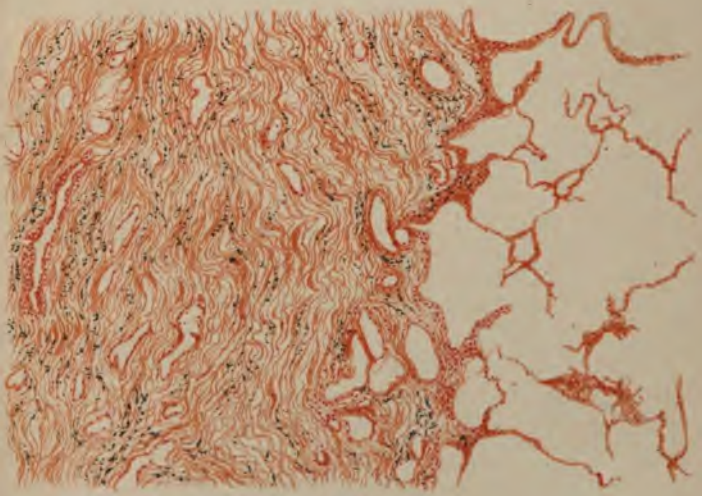

Fig. 2.

Lith. Anst. F. Reichhold., München.

As the cavities enlarge, a few persisting bands or ridges of tissue are usually found to pass across the spaces. On examination, these are found to consist largely of blood-vessels with greatly thickened walls, the lumens being wholly or partly closed by endarteritic or endophlebitic changes. (See Circulatory Organs, p. 39.)

Syphilis.

There is no doubt but that syphilis of the lungs occurs in the adult, but its histologic changes are little known. It is probably frequently confounded with the chronic indurative forms of tuberculosis, both macroscopically and microscopically. The tubercle bacilli are absent, of course. In the new-born, however, and the prematurely still-born the pulmonary lesions of congenital lues present characteristic appearances. Two chief forms are distinguished — the pneumonic form, which involves whole lobes and often the entire lung, and the circumscribed, nodular form.

The diffuse form is characterized by a general increase of the interstitial connective tissue, interlobular as well as peribronchial ; the alveolar septa are also thickened ; this is due to the presence of numerous, spindle-shaped and polygonal, fibroblastic cells. The alveolar spaces become contracted ; they usually contain a rather richly cellular exudate composed of some leukocytes and numerous, desquamated, epithelial cells, which have a pronounced tendency to fatty changes. The blood-vessels present thickened walls ; in the adventitia are connective tissue proliferation and follicular heaps of rounds cells, and in the intima is hyperplasia of the subepithelial connective tissue, so that the lumen becomes greatly narrowed and even wholly closed. This renders the organ anemic. This combined with the fatty changes in the alveolar epithelium gives the involved district a yellowish-white

PLATE 46.

FIG. I.—**Syphilitic "White" Pneumonia of the New-born.** × 250. The alveolar walls are considerably thickened with a richly cellular, connective tissue (1). In the alveolar lumen numerous large, desquamated, epithelial cells (2) and several leukocytes are seen.

FIG. II.—**Indurative Interstitial Pneumonia in Hereditary Syphilis.** × 250. The connective-tissue septa of the alveoli are considerably broadened (1). The alveolar lumens are small and tubular in appearance (2), with atypically proliferated, cuboid epithelium.

---

appearance and a firm consistence, and hence the term "white pneumonia."

In many cases the lungs of syphilitic fetuses contain larger or smaller, light-colored, dry nodules, which are usually not sharply circumscribed. Examined microscopically, it is seen that the changes evidently date from an early embryonal period. The principal part of these nodules consists of a dry connective tissue with long fibrillæ and spindle-shaped nuclei. This tissue is arranged in dense bands, and incloses gland-like and branching centers lined with a cubic, cylindric, or quite regular epithelium. These spaces correspond to the alveoli whose development was arrested by the growth of connective tissue in an early period when the alveolar lining in general is cubic in character. The centers of these nodules are often caseous—that is, the nuclei are not stained while the coarser structure is quite distinct, as is often the case in the caseation of syphilitic lesions. In the lung tissue about the nodules the alveolar septa are usually thickened for a considerable extent, and frequently a "white pneumonia" is also present.

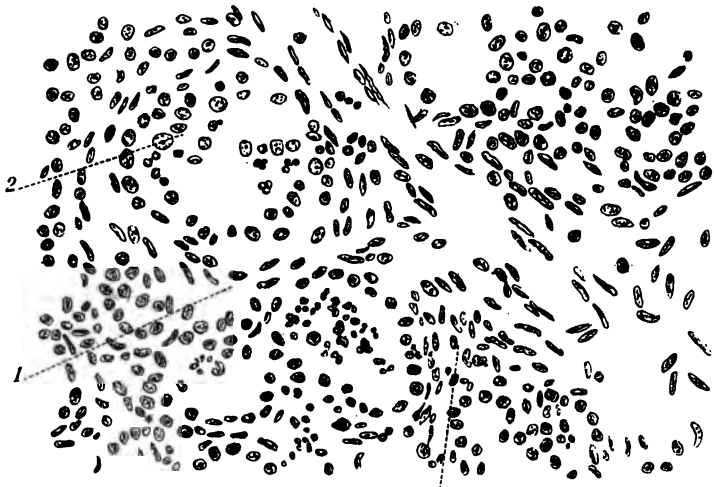

Fig. I.



Fig. II.

Lith. Anst F. Reichhold, München.

PLEURA.

The pulmonary and costal (including the diaphragmatic) pleura consists of a layer of parallel connective-tissue fibers with but few nuclei and interspersed with numerous elastic fibers. The free surface is covered with flat, polygonal epithelium. The pleura is involved in all pulmonary inflammations that reach the pleural surface of the lung. The character of the exudate varies from a fine, macroscopically barely visible layer of fibrin to voluminous, fibrinous precipitates or purulent collections.

In fibrinous pleuritis the epithelium is lost early through swelling and fatty changes; where it is still retained it shows loosening and granular disintegration; rarely does it appear to proliferate. The fibrin, which is derived from the exudation and coagulation of plasmatic fluid, may appear first upon or under the epithelial cells. The connective tissue shows much vascular congestion, the blood-vessels often containing leukocytes or thrombi of filamentous fibrin; the lymph-vessels are widened and often contain fibrin in addition to desquamated cells. Between the connective-tissue fibers lie leukocytes, which usually also infiltrate the fibrinous deposit; the cells of the connective tissue proliferate freely and a granulation tissue is formed, composed of fibroblasts, leukocytes, and new blood-vessels, which push toward and eventually replace the fibrin. Islands of fibrin may be found inclosed in the granulation tissue; such fibrinous masses often undergo hyaline changes, and form glistening, homogeneous flakes which no longer take the fibrin stain. Gradually, the granulation tissue changes into a densely fibrillated, fibrous tissue, its cells diminish, its vessels becoming obliterated.

According to recent investigations by Ziegler, hyaline changes may also occur in mature connective tissue, probably due to an infiltration of the connective tissue with an albuminous body that has coagulated in hyaline form.

PLATE 47.

FIG. I.—**Acute Fibrinous Pleuritis in Croupous Pneumonia.** × 66. Weigert's fibrin stain. 1, Deposit of fibrin inclosing leukocytes; 2, lung tissue infiltrated with pneumonic exudate; 3, thickened pleura infiltrated with young connective-tissue cells and shoots of thin walled blood-vessels, in the lumen of which are seen leukocytes and fibrin (2).

FIG. II.—**Beginning Organization in Fibrinous Pleuritis.** A part of the preceding figure × 340. 1, Layer of fibrin (the pleura is to be thought as near 2); 3, young blood-vessels growing toward the fibrinous layer; 4, as a result of fibrinous accumulation, one of the vessels has become thrombosed; 5, large epithelioid cells with vesicular nuclei; 6, spindle-shaped, young, connective-tissue cells; 7, lymphocytes; 8, leukocytes.

In this way arise the connective-tissue bands, wide-spread fibrous adhesions, and extensive scars in which lime-salts are later deposited.

The tuberculous pleuritis is distinguished from the simple by the presence of tubercles and caseating nodules in the granulation tissue. Otherwise, the same processes of exudation, proliferation, and organization occur.

THYROID GLAND.

The thyroid gland is a compound tubular gland whose duct,—the thyroglossal,—which at one time opens at the foramen cecum on the back of the tongue, becomes obliterated in early embryonal life. The tubules are blind at both ends, and dense strands of fibrous tissue separate them into lobules. Clothed with a cubic and cylindric epithelium, which is arranged upon a basement membrane, the tubules at all stages contain a homogeneous, so-called colloid mass which also fills the lymph-vessels. The stroma is richly vascular.

migrating through the epithelium, and constitute a fertile source of the salivary corpuscles. The tunica propria of the pharynx is also infiltrated with leukocytes which migrate through the epithelium.

In the esophagus three coats are present: The mucosa, covered by stratified squamous epithelium, and containing in the tunica propria a longitudinal muscularis mucosæ; the submucosa; and the internal circular and the external, longitudinal, muscular layers. In the upper fourth the muscular tissue is exclusively striated; in the lower fourth it is exclusively unstriated; and in the middle two-fourths the two are mixed. Outside of the muscular coat are connective-tissue bundles, interspersed with elastic fibers, among which run vessels and nerves. The submucosa contains mucous glands; in the upper and lower ends of the esophagus are glands which correspond in structure to the fundus glands of the stomach. Leukocytes commonly infiltrate the neighborhood of the glands.

Throughout the entire intestinal tract, from the stomach to the rectum, the walls comprise three layers: The serous coat, the muscular, and the mucous. Between the mucous and the muscular lies the submucous.

The serous coat, or the visceral layer of the peritoneum, consists of interlacing bundles of connective-tissue and numerous elastic networks, which externally in places are condensed to form a distinct limiting membrane. The free surface is covered by a single layer of flat, polygonal, epithelial cells. In various places the subserous connective tissue contains a varying amount of fat-cells. The parietal peritoneum at some points contains smooth muscle-fibers.

The muscular coat of the stomach has three layers—namely, external longitudinal fibers, a central circular layer, and an oblique inner layer which in the fundus presents a complicated arrangement. Throughout the large and small intestines the muscularis presents but an inner

circular and an external longitudinal coat. Normally, the spindle-shaped muscle-cells in the adult contain some pigment granules about the nucleus. Between the two muscular layers occurs Auerbach's nerve-plexus.

The submucous coat consists of fibrillated connective tissue with numerous elastic elements; it contains spindle-shaped, stellate, and other cells, and also small masses of fat-cells. Internally, this layer passes on into the stratum proprium of the mucous coat, in which there are no elastic elements, but it contains a varying number of lymphoid cells and thus acquires the characteristics of the so-called cytogenic connective tissue (adenoid tissue).

The muscularis muscosæ, which occurs throughout the whole gastro-intestinal tract, may be regarded as the boundary between the submucous coat and the tunica propria of the mucous layer. The muscularis mucosæ consists, as a general rule, of a single layer of longitudinal, smooth muscle-bundles, which at certain places (the villi) send prolongations into the mucous membrane proper.

The epithelium from the cardiac end of the stomach to the anus is a single layer of cylindric cells. In the submucous coat lies a second nerve-plexus with ganglion cells, the so-called Meissner's plexus. The transition between the flat epithelium of the esophagus and the cylindric epithelium of the stomach is sudden and sharp.

The epithelium of the stomach covers its interior completely; it continues into the mouths of the glands and produces mucus, in consequence of which there are found a varying number of goblet cells. There is no cuticular formation.

Three forms are recognized among the tubular glands: (1) The cardiac glands, occupying a small zone at the transition of the esophagus into the stomach. They are compound, tubular glands, which empty into pit-like depressions lined by typical gastric epithelium. (2) The gastric glands proper, which are found in the fundus and

the body of the stomach. They rest upon the muscularis mucosæ, and are simple tubular glands, often branched. They contain two distinct kinds of cells—the chief or central cells which, small and prismatic, line the principal part of the tubule and secrete pepsin; and the parietal or acid cells, which occur at irregular intervals along the membrana propria and outside of the chief cells. The parietal cells appear to secrete the acids of the gastric juice. (3) The pyloric glands, occurring in the pyloric part of the stomach, and distinguished from the preceding by numerous turns and divisions of the tubules and by entire absence of the parietal cells. In addition, the mucous membrane of the stomach contains closed follicles similar in structure to that of the solitary follicles of the intestine.

The mucous membrane of the intestine presents numerous elevations,—the intestinal villi,—which consist of a prolongation of the tunica propria, smooth muscle-fibers, a capillary network with small meshes, and also, as a rule, one, or rarely several, central chyle vessels. In the duodenum the villi are broad and leaf-like. Two kinds of epithelium cover the villi—the epithelial cells proper, of cylindric form and provided with a distinct cuticular border on their free surface, the nucleus lying in the inferior half of the cells; between these occur the second kind of cells, the goblet cells.

The glands of the small intestine are formed by the simple tubular depressions, or Lieberkühn's crypts, between the villi, and they are lined with cylindric cells and goblet cells. Between the epithelial cells of the villi and of the crypts migratory leukocytes are found in varying numbers.

In the duodenum there occur also branched tubular glands of Brunner, which pierce the muscularis mucosæ, and are lined with darkly granular, cylindric cells.

The large intestine is devoid of villi; the crypts of Lieberkühn are larger and contain numerous goblet cells.

The surface epithelium presents a cuticular or basal border.

In the mucous membrane of both large and small intestines are numerous lymph-nodules, occurring either singly (solitary follicles) or in flattened groups (agminated follicles or Peyer's patches). They lie partly in the mucous membrane itself, partly in the submucous tissue; they reach, on the one hand, to the surface epithelium; on the other, to the muscular coat. They possess a delicate connective-tissue capsule and a delicate reticulum, in the spaces of which lie the lymphocytes. The interior presents a distinct germinal center.

In the large intestine are found only solitary follicles that here are embedded a little deeper in the mucosa, the epithelium forming small crypt-like depressions upon their surface.

ORAL CAVITY, PHARYNX, ESOPHAGUS.

In the mouth and pharynx occur simple catarrhal processes that histologically resemble those of the upper air-passages, except in so far as the stratified squamous epithelium naturally is more resistant than the cylindric.

The vessels of the stratum proprium and of the submucosa are strongly injected. The wandering cells, present normally, are now increased, lymphocytes and numerous leukocytes are present, and in the act of passing out between the epithelial cells, in whose interior they also frequently are found.

The mucous glands are enlarged; here and there a duct is dilated and cystic, filled with mucus. The epithelium shows a granular cloudiness of its protoplasm, especially in the upper layers, and there is an increased desquamation; on the tongue the loosened cells dry up and form brownish masses, which contain numerous bacteria and thread fungi; the adenoid tissue is often considerably

increased, especially in the pharynx in chronic catarrhal conditions, leading to follicular nodules, which give the mucous membrane a granular appearance (granular pharyngitis).

The papillæ of the tongue, especially the secondary papillæ of the filiform variety, are often covered by the threads of a fungus (Leptothrix buccalis, Robin), which must not be confounded with the hair-like prolongations of the apices of the filiform papillæ, produced by increased growth of the epithelium; in marked cases the tongue appears as if covered with hairs, from nine to thirteen millimeters long and pointing backward (lingua hirsuta or villosa; frequently, the hornified epithelium assumes a black color (black, hairy tongue).

Infants that are poorly nourished, marantic individuals in general, and especially diabetics, frequently present whitish-yellow, circumscribed deposits upon the lining of the mouth, pharynx, esophagus, and in children even of the stomach; these deposits are easily removable and at first glance they are not unlike diphtheric membranes. Microscopically, they are found to consist almost wholly of a branching network of the mycelium of the thrush fungus, or oidium or saccharomyces albicans. The threads are septate, and the hyphæ carry oval conidia or spores. Between the threads lie masses of desquamated, partly necrotic, epithelium. In sections it is seen that the mycelium passes deeply into the softened epithelium, which is infiltrated with leukocytes. On the surface of the mass lie masses of spores and bacteria of various kinds. The loosened epithelial cells frequently show poorly stained nuclei, or no nuclei. Occasionally, the mycelium penetrates the entire thickness of the epithelium and reaches down into the stratum proprium.

Tuberculosis of the mucous membrane of the mouth and of the pharynx, as well as of the esophagus, is relatively rare; histologically, it is devoid of peculiarities;

PLATE 48.

FIG. I.—**Variola Vera of the Tongue.** × 75. 1, The whole thickness of the epithelial lining is broken down and necrotic; submucosa penetrated with greatly injected blood-vessels; 2, the submucous glands are necrotic, with cyst-like dilatation of the acini; 3, musculature.

FIG. II.—**Tuberculosis of the Pharynx.** × 75. 1, Epithelium in places very thin and at the point of rupture; in stratum proprium numerous confluent tubercles with beginning necrosis and many giant cells (2); 3, mucous glands.

---

the nodules develop in the stratum proprium of the mucosa, and consist of epithelioid and giant cells and peripherally arranged round cells. The center early becomes caseous, and as the process invades the epithelium this becomes thinner and thinner and infiltrated with round cells, until, finally, rupture takes place; caseous material is then discharged, and a tuberculous ulcer with sinuous outlines is formed; the development of new tubercles followed by caseation leads to increase in extent and depth of the ulcer, whose surroundings are usually widely infiltrated with round cells.

PLATE 49.

FIG. I.—**Diphtheria of the Pharynx.** × 80. The exudation of fibrin (1) between the necrotic epithelial cells is far advanced; the necrosis has not yet reached the superficial surface. In the submucosa (2) the blood-vessels are dilated, some filled with fibrinous thrombi (3).

FIG. II.—**Diphtheria of the Tonsil.** × 280. 1, Fibrinous deposit, inclosing in its meshes nuclei which are disintegrating; 2, zone of the former epithelial layer; epithelial cells largely disintegrated; 3, nuclei of disintegrated epithelial cells; 4, lymphocytes of tonsillar follicle.

Fig. 1.

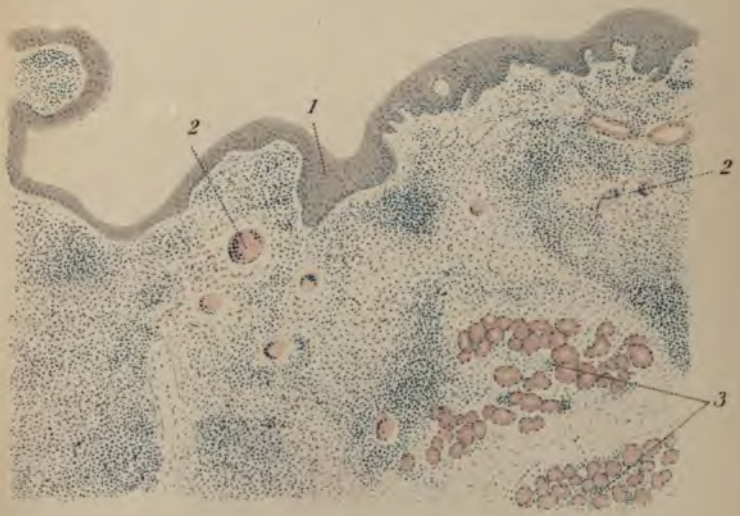

Fig. 2.

Lith. Anst F. Reichhold, München.

Tab. 49.

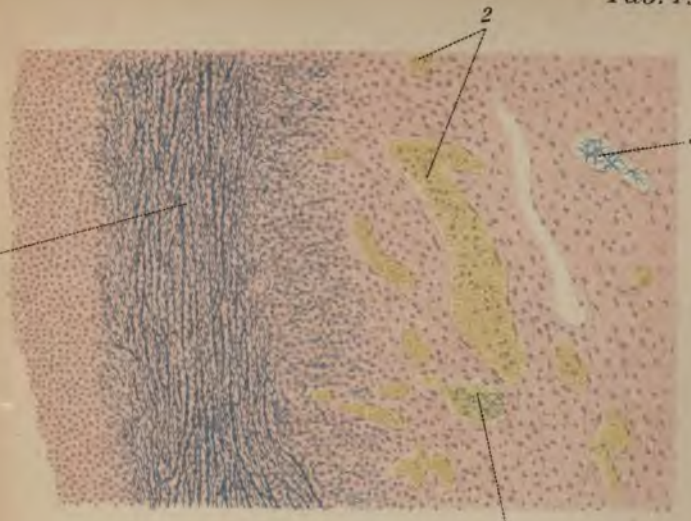

Fig. 1.

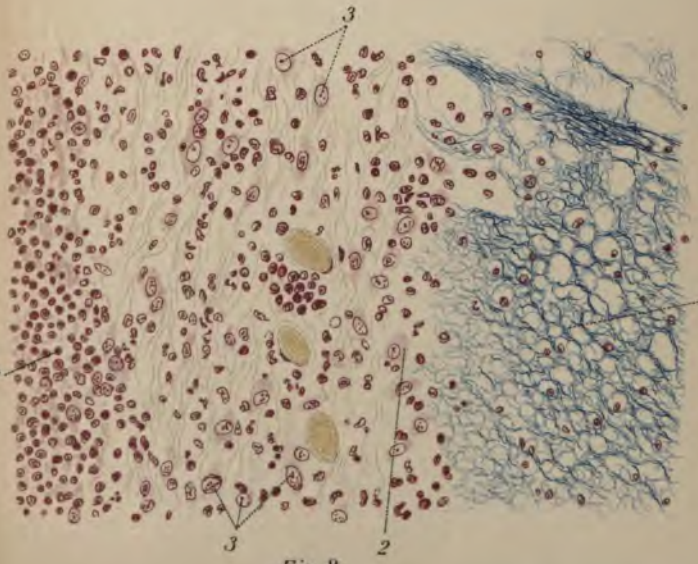

Fig. 2.

Lith. Anst. F. Reichhold, München.

Noma is the name given to an inflammation beginning in the mucous membrane of the lips or the mouth, especially in children after severe infectious diseases. At first the mucous and submucous coats become edematous and infiltrated with blood, followed by leukocytic accumulation and an extensive and rapid gangrene, which spreads in extent and depth, involving all the adjacent soft tissues, such as glands, muscles, fat, and external skin. Previous to their total disappearance the nuclei break up into fragments and deeply staining, minute particles. The blood-vessels generally are thrombotic.

In smallpox the mouth, pharynx, and also the esophagus are often the seat of eruptions quite similar histologically to the cutaneous pustules of variola. The epithelium becomes the seat of vesicular spaces filled with serous fluid, and formed by the pressing asunder of the cells that may remain connected by protoplasmic bands and bridges, so that the cavity of the vesicle is subdivided into many compartments. The accumulation of emigrating leukocytes ultimately renders the contents wholly purulent. Through rupture of the summit of the pustule a flattened ulcer is formed; usually, this occurs earlier in the eruptions upon mucous surfaces than on the external skin, whose horny layer is more resistant. The floor of the ulcer is formed by necrotic epithelium and bacterial masses, especially staphylococci and streptococci. The stratum proprium and the submucosa are much congested and infiltrated with leukocytes. The mucous glands of the submucosa may present similar pustular efflorescences with necrosis of the glandular epithelium and also cystic dilatations of some acini, which become filled with masses of mucus owing to occlusion of some of the secretory ducts. The infiltration usually extends to the underlying tissues.

Croupous and Diphtheric Inflammation.

Croupous and diphtheric processes occur frequently, especially in children, upon the soft palate, the tonsils, in the pharynx, and more rarely in the mouth itself. Anatomically, the terms croupous and diphtheric signify an inflammation in which are combined necrosis of the mucous membrane and fibrinous exudation, so that a membrane ("pseudomembrane") is formed. If the necrosis involves only the superficial layers of the mucosa, —merely the epithelial layer or perhaps only the outer layers of this,—the affection is called croup; while diphtheria, in the anatomic sense, is characterized by a deeper necrosis, which extends into the stratum proprium. Practically, the two forms are hard to differentiate from each other; transitional stages occur from superficial fibrinous deposits with but a slight necrosis, to a severe mortification with the formation of fibrinous material in the deepest layers of the mucous membrane. The necrosis and precipitation of fibrin go hand in hand, and stand in direct causal relation with each other because the death of the tissue cells sets free fibrin ferment which induces coagulation in the plasmatic fluid exuded from the dilated vessels. This process can be observed histologically in various stages of the disease. In the beginning the vessels of the stratum proprium are greatly dilated and filled to distention with blood; mixed among the red blood-corpuscles are numerous leukocytes which are also found free in the connective tissue and the epithelial layer. In some vessels occlusion by fibrinous filaments can be recognized. The epithelium is swollen, the protoplasm of the cells in the rete Malpighii is granular, and the intercellular cement lines appear broad. And now the first threads of fibrin can be observed as broad, glistening bands between the cells; the bands or layers unite to form a network the meshes of which become narrower and narrower while the inclosed

epithelial cells undergo a progressive solution. Gradually, the nuclear chromatin becomes condensed (pyknosis), followed by disintegration into minute fragments; eventually, the fragments disappear wholly, and the destruction of the epithelium is now complete. In the mean time other nuclei appear in the fibrin, due to the migration of numerous leukocytes and nuclear fragmentation; occasionally, lymphocytes are also visible. Usually, the exudation rises above the epithelium. The plasmatic fluid emerges upon its surface and runs over it for a distance before coagulation takes place; on this account the margins of the pseudomembrane are usually easily separated from the underlying tissue. Sometimes the emigration of leukocytes into the membrane is very marked, so that it becomes softened and assumes a purulent appearance. A dense, leukocytic wall forms at the margins of the zone of coagulation necrosis; finally, the new membrane separates either in the form of large shreds or as smaller, softer pieces, due to fatty changes, so that a more or less deep loss of substance results—the diphtheric ulcer. Healing results from proliferation of the epithelium in the vicinity, and new cells gradually cover the defect.

The disease just described is caused in the pharyngeal cavity and in the respiratory mucous membranes principally by Löffler's bacillus of diphtheria; in the latter stages other micro-organisms, especially streptococci, are also found present, often in dense layers. At times these only are active—as, for instance, in scarlatinal diphtheria. But chemic agents, especially corroding substances such as ammonia, can also produce the anatomic picture of a croupous-diphtheric inflammation. This form of inflammation is consequently not of itself absolutely distinctive of a definite infection.

PLATE 50.

FIG. I.—**Acute Suppurative Embolic Parotitis.** × 70. (In appendicitis.) The interstitial tissue of the lobules is purulently infiltrated, the acini themselves are largely destroyed and also greatly infiltrated with leukocytes (2); a few are still present (1). At several areas accumulations of pyogenic cocci (3) are seen.

FIG. II.—**Thrush Vegetations in Esophagus.** × 270. Stained by Gram's method. The upper epithelial layers are loosened in their connections, separated and infiltrated with the mycelium of the thrush fungus (oidium or saccharomyces albicans); the threads are septate. In the lower layers of the epithelium (right) numerous leukocytes are present.

SALIVARY GLANDS.

The salivary glands, especially the parotid, are not rarely the seat of inflammation. In addition to the epidemic form of acute parotitis or mumps, the parotid gland is frequently involved in suppurative processes, principally in the acute infectious diseases—typhoid fever, dysentery, cholera, scarlet fever, diphtheria, sepsis, pyemia. The pyogenic microbes in most cases probably enter the ducts of the gland (Stenson's duct) from the oral cavity. There results an acute sialodochitis with occlusion of the salivary passages by pus-cells, desquamated epithelial cells, and bacterial masses. The overflow of secretion is hindered and the entrance of bacteria into the substance of the gland favored. The interstitial tissue, and later the acini, become densely infiltrated with leukocytes: the epithelial cells may be covered over by leukocytes; numerous cloud-like masses of cocci are seen. Finally, multiple abscesses are formed, which coalesce, and thus establish suppuration throughout the whole gland. Frequently, the purulent process extends to the periglandular tissue.

The diseases of the esophagus do not demand any separate consideration from the histologic standpoint, resembling those of the mouth and the pharynx.

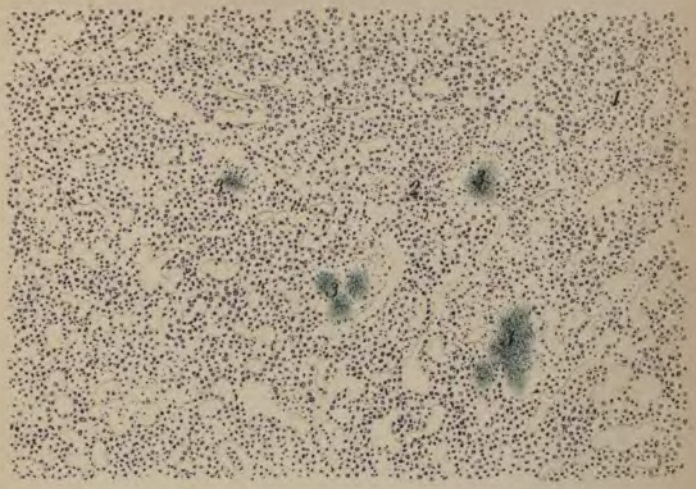

Fig. 1.

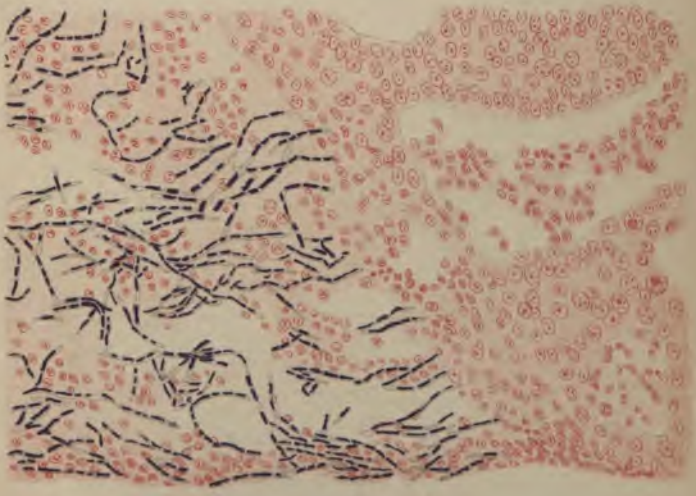

Fig. 2.

Lith. Anst. F. Reichhold, München.

Corrosion of the esophagus by caustic alkalies and by acids presents the appearance of a more or less deep-seated necrosis, with a fibrinous exudation between the necrotic epithelial cells and even in the deeper layers of the mucosa. Ammonia and carbolic acid especially produce typical lesions.

In cardiac insufficiency and in cirrhosis of the liver the submucous veins of the esophagus frequently become varicose, and this may result in rupture and hemorrhage as well as in the formation of genuine varicose ulcers.

STOMACH.

Circulatory disturbances of the stomach are observed in cardiac insufficiency and in obstruction of the portal circulation, as in cirrhosis of the liver. The veins of the mucosa become dilated and small hemorrhages frequently occur; yellow or brownish blood-pigment is often found in the stratum proprium, and the tissue of the submucosa may be edematous.

Acute catarrhal gastritis does not present any histologic peculiarities. In chronic gastric catarrh, as seen so commonly in drunkards, noteworthy changes occur in the mucous membrane, affecting the glands as well as the stratum proprium. Usually, the surface epithelium appears increased as compared with the glandular epithelium proper; frequently, it contains remarkably tall cylindric cells and also numerous goblet cells. In the glands the parietal cells especially appear atrophic; often they disappear wholly. The chief cells occasionally present numerous karyokinetic figures and other evidences of proliferation. They also form numerous goblet cells, which are found from the mouth to the fundus of the glands, giving the mucosa a certain resemblance to that of the rectum. The specific glandular elements disappear more and more, and in the stratum proprium proliferative processes on

PLATE 51.

FIG. I.—**Chronic Granular Gastritis.** × 30. 1, Mucosa; 2, proliferated and greatly convoluted gastric glands; 3, stratum proprium, thickened, infiltrated with round cells, and provided with papillary elevations; below, the muscularis mucosæ and the submucosa; 4, tunica muscularis; 5, serosa with subserous fat-layer.

FIG. II.—**Chronic Catarrh of the Stomach.** × 160. The cells of the stratum proprium much increased in number. Interstices between the glands broadened. In the glandular cells are numerous mitotic figures; many are changing into goblet cells (1).

---

part of the connective tissue are very prominent. The cells are increased in number, and there is also leukocytic infiltration, so that the glands and their ducts are crowded apart and forced above the level of the surrounding mucosa as small papillæ, which form especially in the course of the large submucous vessels (granular gastritis). The resulting irregularity and granular condition of the mucous membrane and the increased consistence are readily recognized macroscopically, and, when marked, frequently referred to as the so-called *état mamelonné*. Occasionally, the increasing proliferation of the connective-tissue ele-

---

PLATE 52.

FIG. I.—**Hemorrhagic, Necrotic Gastritis in Sulphuric Acid Poisoning (from Dog).** × 80. The upper layers of the mucosa form a necrotic scab, infiltrated with numerous red blood-corpuscles; the glands are not visible (1); 2, areas still containing glands; in stratum proprium many round cells; 3, muscularis mucosæ; 4, submucosa.

FIG. II.—**Hemorrhagic Erosion of the Stomach.** × 57. The superficial layers of the mucosa are destroyed. 1, Remains of glands; 2, deposit composed of conglutinated red blood-corpuscles and portions of necrotic mucosa; 3, the stratum proprium is exposed; 4, muscularis mucosæ; 5, submucosa; 6, circular muscular layer.

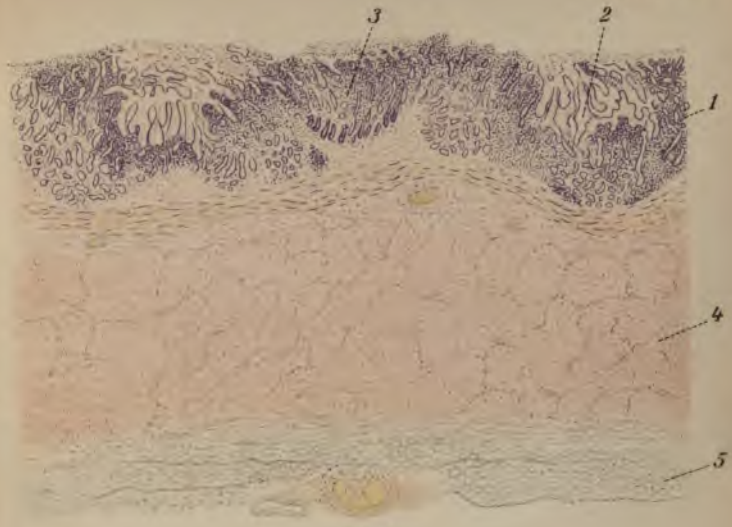

Fig. 1.

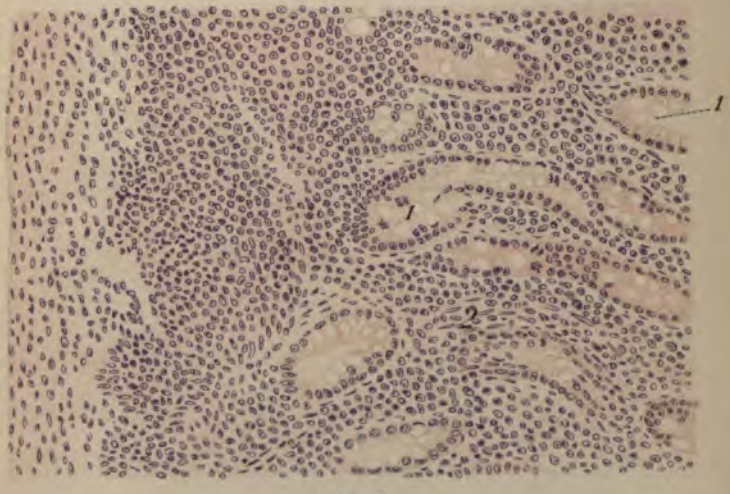

Fig. 2.

Lith. Anst. F. Reichhold, München.

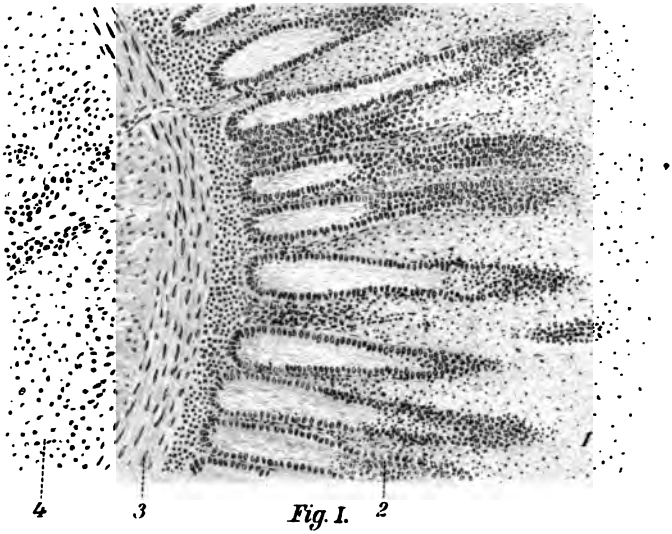

Fig. I.

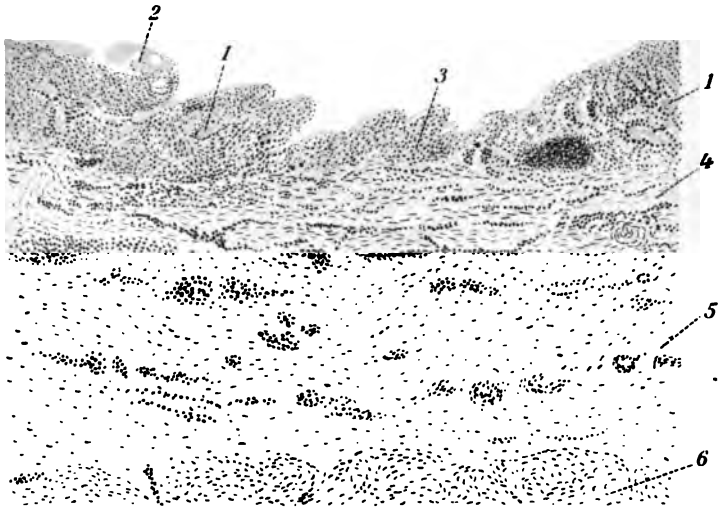

Fig. II.

Lith. Anst. F. Reichhold, München.

PLATE 53.

FIG. I.—**Round Ulcer of the Stomach with Erosion of a Blood-vessel.** ×16. 1, Ulcerated margin, with surrounding mucosa, muscularis mucosæ, and submucosa; the ulcer extends to the inner muscle layer; its floor (2) is covered with necrotic material; 3, eroded arterial blood-vessel with thrombotic lumen.

FIG. II.—**Margin of a Round Ulcer of the Stomach.** ×64. 1, Mucosa; 2, muscularis mucosæ; 3, submucosa; 4, muscularis; 6, infiltrated floor of the ulcer in the outer layers of the muscular coat.

---

rhages, as occur in gastric catarrh and passive congestion, are, perhaps, the most frequent first cause for the superficial defects, usually called hemorrhagic erosions. These are frequently multiple, and at times the mucous membrane is thereby given a sieve-like appearance; they generally involve the mucous coat only, reaching rarely through the muscularis mucosæ; the surface epithelium is destroyed, while the lower part of the glands may be present, especially in the slanting margins; the tissue immediately adjacent is usually necrotic and infiltrated with disintegrated red blood-corpuscles and brownish blood-pigment; below this zone there is proliferation of cells and leukocytic accumulations.

Superficial defects like these commonly heal; the tunica propria is repaired by scar tissue, and new epithelium covers the surface.

Should the peptic action last for a longer time, the defect becomes deeper and wider and there is formed the round ulcer of the stomach. This ulcer extends through the entire thickness of the mucosa, the muscularis mucosæ, and the submucosa; frequently, part or all of the musculature is also eaten away, and even the serous coat may be perforated.

Generally, the margins of the ulcer appear terraced or step-like, because the loss of substance in the mucosa is

Fig. 1.



Fig. 2.

Lith. Anst. F. Reichhold., München.

larger than in the inner layers of the muscular coat, and this again larger than in the outer layers. With low powers, sections of the ulcer show that the margins rapidly slope to the bottom, that the mucosa is frequently contracted in a somewhat funnel-shaped manner, that the immediate vicinity of the defect is necrotic while the more distant parts are infiltrated with round cells. The bottom of the ulcer also presents a thin, necrotic, anuclear layer. Blood-vessels are often eroded and fatal hemorrhage may occur. Microscopically, the vessel walls are then found cut through just as sharply as the single layers in the margins of the ulcer. Usually, the lumen of the vessels is partly or wholly closed by thrombi. It is highly probable that a part of the round ulcers of the stomach originate upon the basis of a hemorrhagic infarction of the gastric wall with consecutive digestion of the mortified area.

Simple atrophy of the mucous membrane of the stomach with disappearance of the glands occurs in chronic gastric catarrh, in carcinoma of the stomach, also in the marantic, and especially in atrophic infants.

Amyloid degeneration occasionally occurs simultaneously with amyloidosis of the intestinal mucous membrane.

Fatty changes of the epithelial and connective-tissue elements are observed, especially in acute phosphorous, and also in arsenous, poisoning.

Tuberculosis and syphilis of the wall of the stomach are of rare occurrence; the specific granulomatous processes form in the stratum proprium and in the submucosa.

Tumors.—The adenomas of the mucous membrane frequently originate from the polypi previously mentioned. Of the connective-tissue tumors, fibroma, myoma, lipoma, and sarcoma are observed. All forms of carcinoma occur in the stomach, from the hard, fibrous scirrhous to soft, almost confluent colloid.

Opportunity is occasionally given for the study of

the beginning of the development of carcinoma in the mucous membrane of the stomach. It is then seen that many layered or solid epithelial masses, starting from the lower parts of the glands, perforate the stratum proprium and the muscularis mucosæ, and infiltrate the submucosa in nest-like groupings. The carcinoma in this case grows into the wall of the stomach without first destroying the overlying mucous membrane. At times larger portions of the wall of the stomach are diffusely infiltrated with carcinomatous masses, and thus rendered greatly thickened and stiff, while the mucosa does not show any loss of substance.

The hard or scirrhous forms of carcinoma are quite prone to cause much narrowing of the lumen, especially of the pylorus. Microscopically, the walls are composed of broad fibrous masses in which are narrow slit-shaped alveoli, filled with a sparse, low epithelium, also present in the muscular coat, which is then usually hypertrophied.

INTESTINE.

Passive congestion of the intestines with marked injection of the vessels and edema of the walls occurs in cardiac insufficiency and in obstruction to the portal circulation; when of longer duration, it is usually associated with the manifestations of a chronic gastric catarrh.

Hemorrhagic infarction and necrosis of larger segments of the intestine occur only after complete occlusion of the superior mesenteric artery. The occlusion of small arteries is generally without effect, because of the numerous anastomoses.

Atrophy of the intestinal wall is found in prolonged inanition, especially in atrophic infants. The lumen is then usually widened by the presence of gas, the walls are thin as paper, transparent, and exceedingly pale.

Microscopically, all layers appear uniformly thinned. The surface epithelium is lost, as a rule, the glands are short, the lymph-follicles have generally disappeared, and both muscle-layers are greatly attenuated. On account of the diminution of the muscle-cells, the lymph-vessels appear more distinct. (Plate 55, Fig. I.)

A peculiar form of atrophy, associated with pigmentation of the musculature, is observed in old age, in marantic and cachectic persons, in alcoholics, and also in cases of a simultaneous pigmentation of other organs, such as the lymph-glands, spleen, kidneys, and liver—the so-called hemochromatosis of Recklinghausen, a disease which apparently depends on an increased destruction of the red blood-corpuscles.[1] Examined fresh, the muscle-cells are found somewhat enlarged and partly, or in severe cases wholly, filled with numerous, minute pigment-granules, which do not always give the iron reaction. Often the nuclei are covered by the pigment particles. The longitudinal muscular layer is commonly more pigmented than the circular. Occasionally, pigment is found in the muscularis mucosæ and the submucosa. The process has a marked similarity to the brown atrophy of striped muscle as seen in the heart. (Plate 55, Fig. II.)

Amyloid degeneration of the intestinal mucosa is occasionally observed in amyloidosis of other organs (kidney, spleen, liver). As elsewhere, the degeneration of the intestinal mucosa also begins in the smaller arteries and preferably in the branches within the villi; glistening masses, giving the well-known specific reactions, are deposited in their walls. The further increase causes a narrowing of the vessels, the mucous membrane becomes anemic and acquires a peculiar stiffness; the epithelium is lost, and many villi appear as if broken across; in some

[1] For a full discussion of hemochromatosis see Opie, "The Journal of Experimental Medicine," 1889, IV, 279, and "Transactions of the Association of American Physicians," 1899, XIV, 253.

PLATE 54.

FIG. I.—**Beginning Carcinoma of the Stomach.** ×54. At left, free surface of mucosa. 1, Proliferated glands with several layers of epithelial cells; 2, muscularis mucosæ, at one point ruptured by glandular proliferation; 3, submucosa; 4, in the submucosa are seen the alveoli of the carcinoma.

FIG. II.—**Marked Stenosis of the Pylorus as a Result of a Scirrhous Carcinoma.** ×13. The lumen is extraordinarily narrowed; the mucosa is wholly destroyed. 1, Connective-tissue bands with small, slit like, cancer alveoli; greatly hypertrophied muscularis.

---

cases the villi are represented by short, broad, anuclear projections. The vessels in the muscular coat are also liable to amyloid change, but the process does not extend to the muscle itself, which may, however, undergo a secondary atrophy.

Inflammations.

In acute catarrhal enteritis the intestinal mucous membrane is swollen, hyperemic, and edematous. The epithelium contains an increased number of goblet cells, and often extensive mucous degeneration is observed, not only in the surface epithelium, but also in the glandular; the mucus accumulates as large, viscid, flocculent, grayish

---

PLATE 55.

FIG. I.—**Atrophy of the Large Intestine; Chronic Tuberculosis in a Child.** ×85. Mucous membrane very thin, with short glands (1) and somewhat increased stratum proprium (2); 2, muscularis mucosæ; 3, submucosa; 4, muscularis; 5, serosa.

FIG. II.—**Brown Atrophy of the Muscularis of the Small Intestine in Cachexia Due to Cancer.** ×330. Almost all muscle-cells filled with fine, granular, brownish pigment; the nuclei are covered by the latter.

Fig. I.

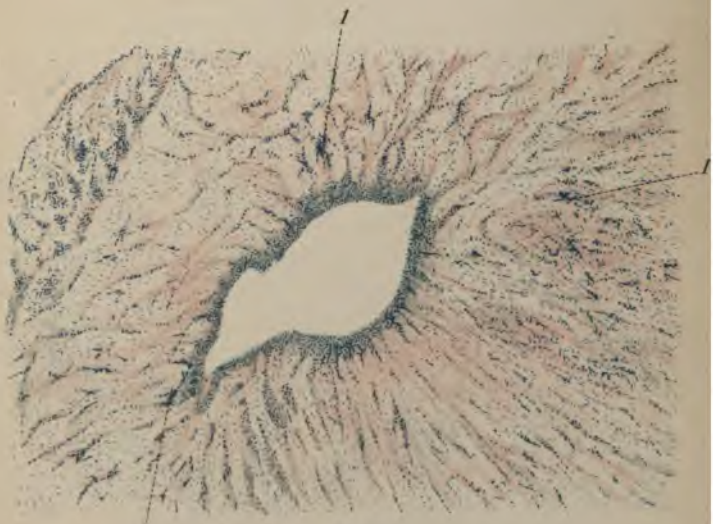

Fig. II.

Lith. Anst. F. Reichhold, München.

Fig. 1.

Fig. 2.

Lith. Anst. F. Reichhold, München.

masses. The lymphatic apparatus is also involved; the follicles are swollen and often project above the level of the mucosa as small nodules as large as a grain of wheat (follicular enteritis). The germinal centers are enlarged on account of an increased formation of lymphocytes; frequently, the centers become necrotic, and, on rupture into the lumen, small, follicular ulcers are produced, which usually heal promptly by proliferation of the reticulum, leaving, however, a small depression easily recognized by the presence of blackish pigment.

In chronic catarrh, which frequently develops as a consequence of long-continued passive hyperemia, the changes described are supplemented by an increase in the stratum proprium and the submucosa, owing to round-cell infiltration and proliferation of the fixed cells. The continuation of this process may lead to partial destruction of the intestinal glands, the mucous membrane becomes irregularly uneven, and polypoid protuberances may be formed by the connective-tissue proliferation (polypoid enteritis). The frequent, minute hemorrhages may lead to an extensive punctiform, blackish pigmentation.

Genuine croupous enteritis—*i. e.*, formation of a fibrinous layer upon the surface of the necrotic intestinal epithelium—is a very rare disease; on the other hand, various etiologic agents may produce the anatomic picture of diphtheria; deep necrosis of the mucosa with precipitation of a varying amount of fibrin. Toxic agents are the most common; in mercurial poisoning the action of the corrosive chlorid eliminated by the mucous membrane of the colon produces a diphtheric colitis; and uremic colitis is a diphtheria caused by an elimination of derivatives from urea; diphtheric inflammation is also the result of pressure-necrosis of the mucous membrane, caused by inspissated fecal masses or hard foreign bodies; in severe septic and pyemic processes diphtheric inflammation of the large intestine arises by metastasis; finally,

PLATE 56.

FIG. I.—**Diphtheric Colitis in Corrosive Sublimate Poisoning.** × 20. 1, Necrotic mucous membrane, covered by eschar; 2, leukocytic wall at margin of slough; 3, greatly injected submucosa; 4, muscularis.

FIG. II.—**Dysentery of Large Intestine.** × 50. The superficial layers of the mucosa are necrotic. In the deeper layers between the glands many leukocytes have accumulated (1); 2, fibrinous thrombus in a small artery; 3, muscularis mucosæ ruptured in many places by leukocytic accumulations; 4, submucosa with greatly dilated blood-vessels.

---

some forms of the so-called dysentery are anatomically diphtheria of the colon. In sublimate poisoning the diphtheric changes may be very extensive; the entire mucous membrane may be converted into a solid, hard eschar, composed of an opaque, grayish layer, which microscopically is found to be without nuclei and infiltrated with hemorrhages and small chromatin fragments; Lieberkühn's glands may be recognized in the form of shadowy and indistinct outlines. Externally, the zone of necrosis is bounded by a thick layer of polynuclear leukocytes, the subjacent submucosa is highly congested, hemorrhagic, and infiltrated with round cells; similar, but not so well-marked, changes may be present in the muscular coat. By means of the fibrin stain the necrotic eschar and also the submucous tissue are shown to contain a fine, fibrinous network; many of the vessels are also often the seat of fibrin formation. (Plate 56, Figs. I and II.)

Dysentery, in the strict sense, is characterized by a purulent infiltration of the mucous and submucous coats. The glands are compressed and separated from each other by the accumulation of cells, and pus may form in the glandular lumen. Simultaneously, fibrin is deposited in

Tab. 56.

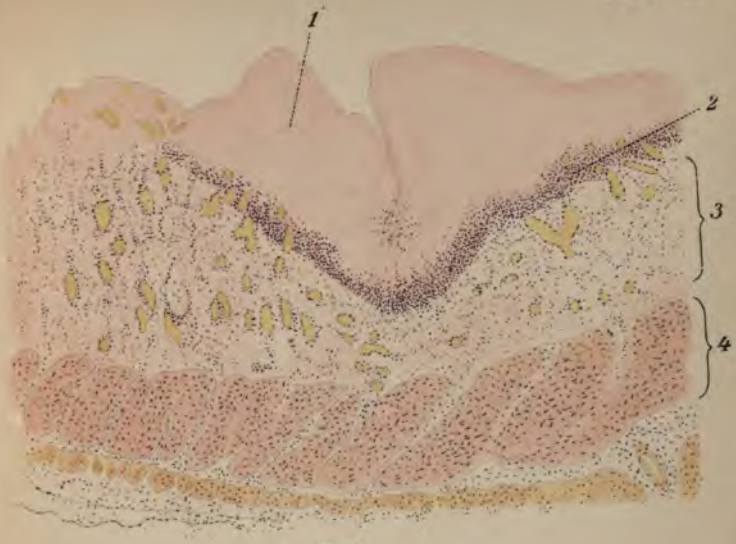

Fig. 1.

Fig. 2.

Lith. Anst. F. Reichhold, München.

the superficial layers of the epithelium, which undergoes necrosis. The process may spread toward the submucosa and lead to an extensive and deep coagulation necrosis of the mucous membrane. In the beginning the necrotic areas may be separated from each other, but later they coalesce to form thick, stiff, brownish or greenish crusts and membranes. The increasing accumulation of the leukocytes gradually separates the crusts and ulcers, at the base of which appears the hyperemic and infiltrated submucosa, which may continue to suppurate for a long time. The lymphatic follicles are also much swollen, and a central necrosis may produce crater-shaped losses of substance. [In amebic dysentery the ulcers have overhanging margins.]

In these processes, as well as in the typhoid intestinal lesions, the lymph-vessels are involved in a characteristic manner. They appear as remarkably distinct, richly cellular cords at the boundary of the submucosa and between the muscular layers. Their lumen is filled with large, polygonal, and flat cells,—desquamated epithelial cells,—which often appear necrotic or filled with fat-vacuoles; in addition, are seen leukocytes and deeply stained bacterial masses. (Plate 58, Fig. II.)

On account of its rapid course cholera does not produce extensive or noteworthy histologic changes in the intestines. In the cases that die in the stage of asphyxia there are found small hemorrhages, extensive desquamation of the surface epithelium, necrosis of the summits of the villi; occasionally, the necrosis may extend to the base of the villi; the submucosa usually contains numerous mast-cells.

The changes in the intestines in typhoid fever are more characteristic and more severe. The specific microbes localize in the lymphatic apparatus of the mucous membrane, and it is here that the most marked changes occur. These changes correspond in a general way with those

PLATE 57.

FIG. I.—**Typhoid Fever. Medullary Swelling of Follicle of Large Intestine.** × 50. The follicle is greatly enlarged, and shades into the surrounding infiltration ; at its upper part the mucous membrane is almost displaced. 1, Remains of the glands of Lieberkühn ; 2, infiltrated submucosa ; 3, remains of follicle.

FIG. II.—**Typhoid Fever. Medullary Swelling with Beginning Necrosis of a Follicle.** × 50. In the center of the follicle necrosis has taken place ; a small amount of fibrin is here found (3) ; in the submucosa (4) greatly injected blood-vessels and numerous, large, round cells (deeply stained with eosin) ; 1, mucosa infiltrated with leukocytes ; 2, muscularis mucosæ ; 5, muscularis.

---

that occur in the mesenteric lymph-glands and in the spleen, and which have been referred to. In the first stage, corresponding to the first two weeks of the disease, the solitary follicles and Peyer's patches, especially those near the ileocecal valve, become considerably enlarged, of soft consistence, rising above the surrounding mucosa (so-called medullary infiltration).

Microscopically, the swelling of the follicles is found to depend upon a marked multiplication and enlargement of the cells in the germinal centers and their vicinity. In place of the lymphocytes appear numerous, large, roundish cells, with a large amount of acidophilous protoplasm, the nuclei being mostly vesicular, although some may be richer in chromatin and often a number are present in one cell. The appearance resembles very much those presented by mesenteric glands that are the seat of typhoid swelling. (Plate 14, Fig. II.) This similarity is increased by the appearance of fat-vacuoles in the plasmatic cells [phagocytic cells that often contain red corpuscles, etc.] in the intestinal follicles.

In the beginning masses of typhoid bacilli are found just as in the lymph-glands (Plate 14, Fig. II) ; later, the

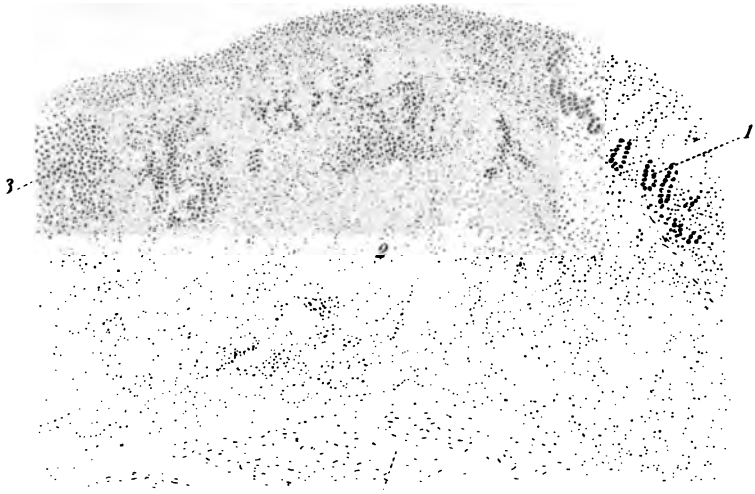

Fig. 1.



Fig. 2.

Lith. Anst F. Reichhold, München.

bacilli disappear, while other micro-organisms may invade the tissue secondarily. Mast-cells appear in the vicinity of the swollen follicles almost without exception; these cells are large, round cells filled with small, roundish granules, which stain deeply with alkaline, aniline dyes. The limits of the follicles become obscured on account of the leukocytic infiltration of the adjacent mucosa and submucosa.

[Mast-cells are cells whose protoplasm is filled with basophile granules that stain red (metachromatically) with polychrome methylene-blue. Plasma cells are cells of oval, cubic, or rhombic form, whose protoplasm retains a blue color when stained with methylene-blue, while the nucleus, generally eccentric in its situation, stains more lightly and presents a few blue, chromatic masses. It is regarded as derived from preexisting or emigrated lymphocytes, and occurs in various cell accumulations of inflammatory nature.]

The mucous membrane covering the follicles is raised so that the crypts at the side of the swelling acquire an oblique position; very soon retrogressive changes make their appearance in these parts of the mucosa. The superficial epithelium, and also, in part, that lining the crypts, becomes necrotic; the villi also undergo necrosis; fibrin is deposited in the necrotic layer, so that at a certain definite stage there is a diphtheric inflammation over the follicles. The surrounding blood-vessels are greatly congested. Occasionally, the medullary infiltration of the follicles subsides, and a simple resolution ensues without extensive and general necrosis; the swollen and enlarged cells undergo fatty changes, and the fat-drops are absorbed. (Plate 57, Figs. I and II.) Usually, however, the end of the second or the beginning of the third week witnesses the appearance of an at first limited and superficial necrosis that gradually involves the whole follicle. A delicate, fibrinous network appears between the

PLATE 58.

FIG. I.—**Typhoid Fever. Ulcer after Detachment of Slough.** × 50. The margins of the defect end abruptly; in the floor of the ulcer, which reaches into the submucosa, are seen a few necrotic portions of tissue with extensive infiltration of leukocytes. 1, Mucosa; 2, muscularis mucosæ; 3, submucosa with overfilled blood-vessels; 4, muscularis.

FIG. II.—**Intestinal Lymphangitis. Cellular "Thrombus" in a Lymph-vessel of the Submucosa of the Large Intestine in Dysentery.** × 360. 1, In the lymph-vessel are seen large polygonal, partly necrotic cells, some with two nuclei; among these are several leukocytes.

---

disintegrating cells; eventually, the necrotic follicle and the necrotic mucous membrane are changed into a structureless mass, often stained greenish by the bile, and surrounded by a dense leukocytic wall. This is the typhoid slough.

Toward the end of the third or the beginning of the fourth week this slough becomes loosened from the surroundings and thrown off—the typhoid ulcer has formed. (Plate 58, Fig. I.) The margins of the ulcer are usually abrupt; the depth varies, depending on the extent of the necrosis and the size of the follicles involved; it always extends at least to the submucosa, and not rarely the necrosis may involve the muscular coat, so that at times there is exposed the serous membrane, which may become perforated. The floor of the ulcer is at first brownish or blackish from the extravasated blood, but soon it becomes clean, so that the tissue exposed is readily recognizable. Later, the tissue forming the floor of the ulcer produces granulation tissue from newly formed connective-tissue cells and embryonic vessels, until the defect is filled up. The surface epithelium may be regenerated from that at the margin; even the villi are partly reproduced, but the glands do not seem to be reproduced.



Fig. 1.

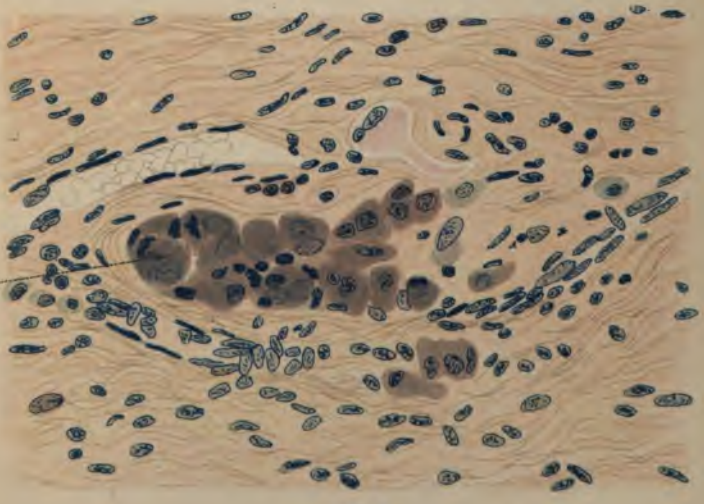

Fig. 2.

Lith. Anst F. Reichhold, München.

These regenerative processes do not generally appear before the fifth to the sixth week of the disease.

As in diphtheric enteritis and in dysentery, so also in typhoid, the lymph-vessels of the intestinal wall become involved through extensive desquamation and new formation of their epithelium.

Tuberculosis.

Primarily, tuberculosis of the intestines also tends to become localized in the lymphatic apparatus of the mucous membrane. As the leukocytes accumulate, large polygonal cells, with vesicular, clear nuclei,—the so-called epithelioid cells,—appear among them and often form giant cells. The epithelioid cells are undoubtedly derivatives of connective-tissue cells, and the cells lining lymph-vessels.

While different cells accumulate about the small nodules and densely infiltrate the mucous membrane, the center of the mass undergoes coagulation necrosis; the nuclei disintegrate into fine fragments and finally disappear wholly. The caseous area spreads and involves the surrounding tissue, so that the mucous membrane is broken through and the caseous center empties itself into the lumen of the intestine; the follicular, tuberculous ulcer which is thus formed corresponds to the caseous area, and has overhanging, irregularly thickened, swollen margins. The defect increases rapidly because new tubercles form in the floor and undergo caseation; the process frequently spreads in a circular direction—that is, perpendicularly to the long axis of the intestine. In advanced instances all the layers of the intestinal wall—the submucous, muscular, and serous—become infiltrated with nodules that may undergo necrosis, until eventually perforation takes place. (Plate 59, Figs. I and II.)

Syphilitic granulomas occur in the intestinal walls in congenital syphilis of the new-born as well as in adults

PLATE 59.

FIG. I.—**Beginning Tuberculosis in the Vermiform Appendix.** × 80. Mucosa about normal, but with infiltrated stratum proprium. 1, Moderately sharply circumscribed, cellular nodule in the submucosa with beginning central necrosis.

FIG. II.—**From the Margin of a Tuberculous Ulcer of the Intestine.** × 80. The greater part of the mucosa is destroyed by exfoliation of the caseous tissue. 3, The overhanging margin of the tuberculous ulcer; 2, floor of ulcer; at (1) is a newly formed nodule. All the blood-vessels are greatly distended with blood.

---

in the later stages of acquired lues. The nodules differ from tuberculosis on account of their tendency to fibrous encapsulation and the constant presence of syphilitic endarteritis in their vicinity. The confluence of adjacent nodules may occasionally produce larger sclerotic patches in the mucosa and submucosa.

PERITONEUM.

The inflammations (including tuberculosis) of the peritoneum resemble, histologically, the same processes in the pleura. In order to avoid repetitions, it is sufficient to refer the reader to page 117.

PLATE 60.

FIG. I.—**Beginning Suppurative Peritonitis, Twenty-four Hours after Ligating the Intestine (from Guinea-pig).** × 625. 1, Peritoneal connective tissue in longitudinal and transverse section; 2, epithelium; 3, exudate, consisting of a moderate amount of fibrin (several of the threads are also deposited between the epithelial cells and the connective tissue of the serosa), numerous leukocytes, and red blood-corpuscles. Scattered about are nuclei of detached epithelium and various bacteria.

FIG. II.—**Tuberculous Peritonitis.** × 72. 1, Epithelium; 2, infiltrated connective tissue of the serosa; 3, subserous fat-layer; 4, tubercle with giant-cells; 5, villus-like elevations.

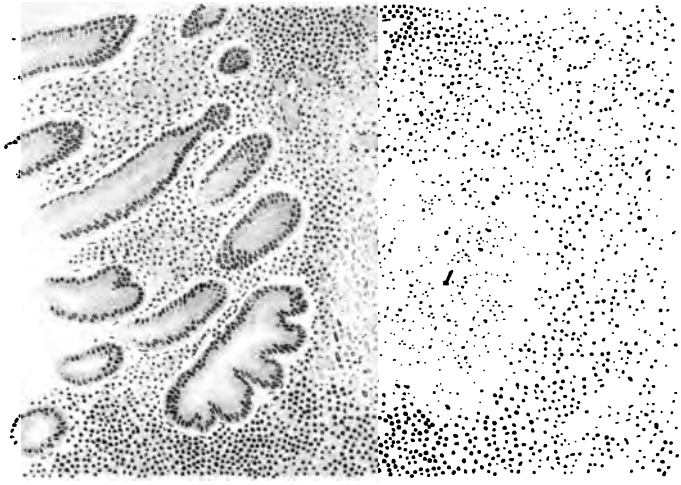

Fig. I.



Fig. II.

Lith. Anst. F. Reichhold, München.

Tab. 60.

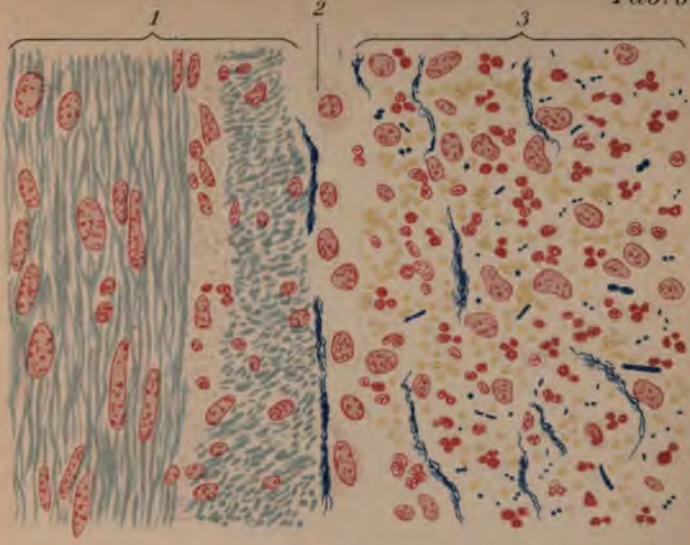

Fig. 1.

Fig. 2.

Lith. Anst. F. Reichhold., München

INDEX.

C.

D.

L.

M.

N.

T.

U.

Medical and Surgical Works

PUBLISHED BY

W. B. SAUNDERS, 925 Walnut Street, Philadelphia, Pa.

GENERAL INFORMATION.

One Price. One price absolutely without deviation. No discounts allowed, regardless of the number of books purchased at one time. Prices on all works have been fixed extremely low, with the view to selling them strictly net and for cash.

Orders. An order accompanied by remittance will receive prompt attention, books being sent to any address in the United States, by mail or express, all charges prepaid. We prefer to send books **by express** when possible.

Cash or Credit. To physicians of approved credit who furnish satisfactory references our books will be sent free of C. O. D. **One volume or two** on thirty days' time if credit is desired; larger purchases on monthly payment plan. See offer below.

How to Send Money by Mail. There are four ways by which money can be sent at our risk, namely: a post-office money order, an express money order, a bank-check (draft), and in a registered letter. Money sent in any other way is at the sender's risk. Silver should not be sent through the mail.

Shipments. All books, being packed in patent metal-edged boxes, necessarily reach our patrons by mail or express in excellent condition.

Subscription Books. Books in this catalogue marked with a star (*) are for sale by subscription only, and may be secured by ordering them through any of our authorized travelling salesmen, or direct from the Philadelphia office: they are **not** for sale by booksellers. All other books in our catalogue can be procured of any bookseller at the advertised price, or directly from us.

Miscellaneous Books. We carry in stock only our own publications, but can supply the publications of other houses (except subscription books) on receipt of publisher's price.

Latest Editions. In every instance the latest revised edition is sent.

Bindings. In ordering, be careful to state the style of binding desired—Cloth, Sheep, or Half Morocco.

Special Offer. Monthly Payment Plan. To physicians of approved credit who furnish satisfactory references books will be sent express prepaid; terms, $5.00 cash upon delivery of books, and monthly payments of $5 00 thereafter until full amount is paid. Any of the publications of W. B. Saunders (100 titles to select from) may be had in this way at catalogue price, including the American Text-Book Series, the Medical Hand-Atlases, etc. All payments to be made by mail or otherwise, free of all expense to us.

SAUNDERS'
MEDICAL HAND-ATLASES.

THE series of books included under this title consists of authorized translations into English of the world-famous **Lehmann Medicinische Handatlanten,** which for **scientific accuracy, pictorial beauty, compactness,** and **cheapness** surpass any similar volumes ever published. Each volume contains from **50 to 100 colored plates,** executed by the most skilful German lithographers, besides numerous illustrations in the text. There is a full and appropriate **description,** and each book contains a condensed but adequate **outline of the subject** to which it is devoted.

In planning this series arrangements were made with representative publishers in the chief medical centers of the world for the publication of translations of the atlases into nine different languages, the lithographic plates for all being made in Germany, where work of this kind has been brought to the greatest perfection. The enormous expense of making the plates being shared by the various publishers, the cost to each one was reduced to practically one-tenth. Thus by reason of their **universal translation** and reproduction, affording international distribution, the publishers have been enabled to secure for these atlases the **best artistic and professional talent,** to produce them in the **most elegant style,** and yet to offer them at a **price heretofore unapproached in cheapness.** The great success of the undertaking is demonstrated by the fact that the volumes have already appeared in **thirteen different languages** —German, English, French, Italian, Russian, Spanish, Japanese, Dutch, Danish, Swedish, Roumanian, Bohemian, and Hungarian.

In view of the unprecedented success of these works, Mr. Saunders has contracted with the publisher of the original German edition for **one hundred thousand copies** of the atlases. In consideration of this enormous undertaking, the publisher has been enabled to prepare and furnish special additional colored plates, making the series even **handsomer and more complete** than was originally intended.

As an indication of the great practical value of the atlases and of the immense favor with which they have been received, it should be noted that the **Medical Department of the U. S. Army** has adopted the "Atlas of Operative Surgery," as its standard, and has ordered the book in large quantities for distribution to the various regiments and army posts.

The same careful and competent **editorial supervision** has been secured in the English edition as in the originals. The translations have been edited by the **leading American specialists** in the different subjects.

(*For List of Volumes in this Series, see next two pages.*)

SAUNDERS' MEDICAL HAND-ATLASES.

VOLUMES NOW READY.

Atlas and Epitome of Internal Medicine and Clinical Diagno
By DR. CHR. JAKOB, of Erlangen. Edited by AUGUSTUS A. ESHNER, M.
Professor of Clinical Medicine, Philadelphia Polyclinic. With 68 co
plates, 64 text-illustrations, and 259 pages of text. Cloth, $3.00 net.

"The charm of the book is its clearness, conciseness, and the accuracy and beauty
illustrations. It deals with facts. It vividly illustrates those facts. It is a scientific
put together for ready reference."—*Brooklyn Medical Journal.*

Atlas of Legal Medicine. By DR. E. R. VON HOFMANN, of Vienna. E
by FREDERICK PETERSON, M. D., Chief of Clinic, Nervous Dept., C
of Physicians and Surgeons, New York. With 120 colored figures o
plates, and 193 beautiful half-tone illustrations. Cloth, $3.50 net.

"Hofmann's 'Atlas of Legal Medicine' is a unique work. This immense field finds i
book a pictorial presentation that far excels anything with which we are familiar in any
work."—*Philadelphia Medical Journal.*

Atlas and Epitome of Diseases of the Larynx. By DR. L. GRUNW
of Munich. Edited by CHARLES P. GRAYSON, M. D., Physician-in-Ch
Throat and Nose Department, Hospital of the University of Pennsylv
With 107 colored figures on 44 plates, 25 text-illustrations, and 103 p
of text. Cloth, $2.50 net.

"Aided as it is by magnificently executed illustrations in color, it cannot fail of bein
the greatest advantage to students, general practitioners, and expert laryngologists."
Louis Medical and Surgical Journal.

Atlas and Epitome of Operative Surgery. By DR. O. ZUCKERKAN
of Vienna. Edited by J. CHALMERS DACOSTA, M. D., Clinical Profe
of Surgery, Jefferson Medical College, Philadelphia. With 24 colored pl
217 text-illustrations, and 395 pages of text. Cloth, $3.00 net.

"We know of no other work that combines such a wealth of beautiful illustration
clearness and conciseness of language, that is so entirely abreast of the latest achieve
and so useful both for the beginner and for one who wishes to increase his knowledge of
ative surgery."—*Münchener medicinische Wochenschrift.*

Atlas and Epitome of Syphilis and the Venereal Diseases.
PROF. DR. FRANZ MRACEK, of Vienna. Edited by L. BOLTON BA
M. D., Professor of Genito-Urinary Surgery, University and Bellevue
pital Medical College, New York. With 71 colored plates, 16 black
white illustrations, and 122 pages of text. Cloth, $3.50 net.

"A glance through the book is almost like actual attendance upon a famous clinic
Journal of the American Medical Association.

Atlas and Epitome of External Diseases of the Eye. By DR
HAAB, of Zurich. Edited by G. E. DE SCHWEINITZ, M. D., Professo
Ophthalmology, Jefferson Medical College, Philadelphia. With 76 co
illustrations on 40 plates, and 228 pages of text. Cloth, $3.00 net.

"It is always difficult to represent pathological appearances in colored plates, but
work seems to have overcome these difficulties, and the plates, with one or two excep
are absolutely satisfactory."—*Boston Medical and Surgical Journal.*

Atlas and Epitome of Skin Diseases. By PROF. DR. FRANZ MRA
of Vienna. Edited by HENRY W. STELWAGON, M. D., Clinical Profe
of Dermatology, Jefferson Medical College, Philadelphia. With 63 co
plates, 39 half-tone illustrations, and 200 pages of text. Cloth, $3.50 n

"The importance of personal inspection of cases in the study of cutaneous diseas
readily appreciated, and next to the living subjects are pictures which will show the ap
ance of the disease under consideration. Altogether the work will be found of very
value to the general practitioner."—*Journal of the American Medical Association.*

SAUNDERS' MEDICAL HAND-ATLASES.

VOLUMES IN PRESS FOR EARLY PUBLICATION.

Atlas and Epitome of Diseases Caused by Accidents. By DR. ED. GOLEBIEWSKI, of Berlin. Translated and edited with additions by PEARCE BAILEY, M.D., Attending Physician to the Department of Corrections and to the Almshouse and Incurable Hospitals, New York. With 40 colored plates, 143 text-illustrations, and 600 pages of text.

Atlas and Epitome of Special Pathological Histology. By DR. H. DÜRCK, of Munich. Edited by LUDVIG HEKTOEN, M.D., Professor of Pathology, Rush Medical College, Chicago. Two volumes, with about 120 colored plates, numerous text-illustrations, and copious text.

Atlas and Epitome of General Pathological Histology. With an Appendix on Patho-histological Technic. By DR. H. DÜRCK, of Munich. Edited by LUDVIG HEKTOEN, M.D., Professor of Pathology, Rush Medical College, Chicago. With 80 colored plates, numerous text-illustrations, and copious text.

Atlas and Epitome of Gynecology. By DR. O. SCHÄFFER, of the University of Heidelberg. With 90 colored plates, 65 text-illustrations, and 308 pages of text. Edited by RICHARD C. NORRIS, A. M., M. D., Gynecologist to the Philadelphia and the Methodist Episcopal Hospitals.

IN PREPARATION.

Atlas and Epitome of Orthopedic Surgery. By DR. SCHULTESS and DR. LÜNING, of Zurich. About 100 colored illustrations.

Atlas and Epitome of Operative Gynecology. By DR. O. SCHÄFFER, of Heidelberg. With 40 colored plates and numerous illustrations in black and white from original paintings.

Atlas and Epitome of Diseases of the Ear. Edited by PROF. DR. POLITZER, of Vienna, and DR. G. BRÜHL, of Berlin. With 120 colored illustrations and about 200 pages of text.

Atlas and Epitome of General Surgery. Edited by DR. MARWEDEL, with the coöperation of PROF. DR. CZERNY. With about 200 colored illustrations.

Atlas and Epitome of Psychiatry. By DR. WILH. WEYGANDT, of Würzburg. With about 120 colored illustrations.

Atlas and Epitome of Normal Histology. By DR. JOHANNES SOBOTTA, of Würzburg. With 80 colored plates and numerous illustrations.

Atlas and Epitome of Topographical Anatomy. By PROF. DR. SCHULTZE, of Würzburg. About 100 colored illustrations and a very copious text.

***THE INTERNATIONAL TEXT-BOOK OF SURGERY. In two volumes. By American and British authors.** Edited by J. COLLINS WARREN, M.D., LL.D., Professor of Surgery, Harvard Medical School, Boston; Surgeon to the Massachusetts General Hospital; and A. PEARCE GOULD, M. S., F. R. C. S., Eng., Lecturer on Practical Surgery and Teacher of Operative Surgery, Middlesex Hospital Medical School; Surgeon to the Middlesex Hospital, London, England. Vol. I.—**General and Operative Surgery.**—Handsome octavo volume of 947 pages, with 458 beautiful illustrations, and 9 lithographic plates. Vol. II.—**Special or Regional Surgery.**—Handsome octavo volume of 1050 pages, with over 500 woodcuts and half-tones, and 8 lithographic plates. Prices per volume: Cloth, $5.00 net; Half-Morocco, $6.00 net.

Just Issued.

In presenting a new work on surgery to the medical profession the publisher feels that he need offer no apology for making an addition to the list of excellent works already in existence. Modern surgery is still in the transition stage of its development. The art and science of surgery are advancing rapidly, and the number of workers is now so great and so widely spread through the whole of the civilized world that there is certainly room for another work of reference which shall be untrammelled by many of the traditions of the past, and shall at the same time present with due discrimination the results of modern progress. There is a real need among practitioners and advanced students for a work on surgery encyclopedic in scope, yet so condensed in style and arrangement that the matter usually diffused through four or five volumes shall be given in one-half the space and at a correspondingly moderate cost.

The ever-widening-field of surgery has been developed largely by special work, and this method of progress has made it practically impossible for one man to write authoritatively on the vast range of subjects embraced in a modern text-book of surgery. In order, therefore, to accomplish their object, the editors have sought the aid of men of wide experience and established reputation in the various departments of surgery.

CONTRIBUTORS:

Dr. Robert W. Abbe.
C. H. Golding Bird.
E. H. Bradford.
W. T. Bull.
T. G. A. Burns.
Herbert L. Burrell.
R. C. Cabot.
I. H. Cameron.
James Cantlie.
W. Watson Cheyne.
William B. Clarke.
William B. Coley.
Edw. Treacher Collins.
H. Holbrook Curtis.
J. Chalmers Da Costa.
N. P. Dandridge.
John B. Deaver.
J. W. Elliot.
Harold Ernst.

Dr. Christian Fenger.
W. H. Forwood.
George R. Fowler.
George W. Gay.
A. Pearce Gould.
J. Orne Green.
John B. Hamilton.
M. L. Harris.
Fernand Henrotin.
G. H. Makins.
Rudolph Matas.
Charles McBurney.
A. J. McCosh.
L. S. McMurtry.
J. Ewing Mears.
George H. Monks.
John Murray.
Robert W. Parker.

Dr. Rushton Parker.
George A. Peters.
Franz Pfaff.
Lewis S. Pilcher.
James J. Putnam.
M. H. Richardson.
A. W. Mayo Robson.
W. L. Rodman.
C. A. Siegfried.
G. B. Smith.
W. G. Spencer.
J. Bland Sutton.
L. McLane Tiffany.
H. Tuholske.
Weller Van Hook.
James P. Warbasse.
J. Collins Warren.
De Forest Willard.

***AN AMERICAN TEXT-BOOK OF PHYSIOLOGY.** Edited by WILLIAM H. HOWELL, PH. D., M. D., Professor of Physiology in the Johns Hopkins University, Baltimore, Md. One handsome octavo volume of 1052 pages, fully illustrated. Prices: Cloth, $6.00 net; Sheep or Half-Morocco, $7.00 net.

This work is the most notable attempt yet made in America to combine in one volume the entire subject of Human Physiology by well-known teachers who have given especial study to that part of the subject upon which they write. The completed work represents the present status of the science of Physiology, particularly from the standpoint of the student of medicine and of the medical practitioner.

The collaboration of several teachers in the preparation of an elementary text-book of physiology is unusual, the almost invariable rule heretofore having been for a single author to write the entire book. One of the advantages to be derived from this collaboration method is that the more limited literature necessary for consultation by each author has enabled him to base his elementary account upon a comprehensive knowledge of the subject assigned to him; another, and perhaps the most important, advantage is that the student gains the point of view of a number of teachers. In a measure he reaps the same benefit as would be obtained by following courses of instruction under different teachers. The different standpoints assumed, and the differences in emphasis laid upon the various lines of procedure, chemical, physical, and anatomical, should give the student a better insight into the methods of the science as it exists to-day. The work will also be found useful to many medical practitioners who may wish to keep in touch with the development of modern physiology.

CONTRIBUTORS:

HENRY P. BOWDITCH, M. D.,
Professor of Physiology, Harvard Medical School.

JOHN G. CURTIS, M. D.,
Professor of Physiology, Columbia University, N. Y. (College of Physicians and Surgeons).

HENRY H. DONALDSON, Ph. D.,
Head-Professor of Neurology, University of Chicago.

W. H. HOWELL, Ph. D., M. D.,
Professor of Physiology, Johns Hopkins University.

FREDERIC S. LEE, Ph. D.,
Adjunct Professor of Physiology, Columbia University, N. Y. (College of Physicians and Surgeons).

WARREN P. LOMBARD, M. D.,
Professor of Physiology, University of Michigan.

GRAHAM LUSK, Ph. D.,
Professor of Physiology, Yale Medical School.

W. T. PORTER, M. D.,
Assistant Professor of Physiology, Harvard Medical School.

EDWARD T. REICHERT, M. D.,
Professor of Physiology, University of Pennsylvania.

HENRY SEWALL, Ph. D., M. D.,
Professor of Physiology, Medical Department, University of Denver.

"We can commend it most heartily, not only to all students of physiology, but to every physician and pathologist, as a valuable and comprehensive work of reference, written by men who are of eminent authority in their own special subjects."—*London Lancet.*

"To the practitioner of medicine and to the advanced student this volume constitutes, we believe, the best exposition of the present status of the science of physiology in the English language."—*American Journal of the Medical Sciences.*

***AN AMERICAN TEXT-BOOK OF APPLIED THERAPEUTICS. For the Use of Practitioners and Students.** Edited by JAMES C. WILSON, M. D., Professor of the Practice of Medicine and of Clinical Medicine in the Jefferson Medical College. One handsome octavo volume of 1326 pages. Illustrated. Prices: Cloth, $7.00 net; Sheep or Half-Morocco, $8.00 net.

The arrangement of this volume has been based, so far as possible, upon modern pathologic doctrines, beginning with the intoxications, and following with infections, diseases due to internal parasites, diseases of undetermined origin, and finally the disorders of the several bodily systems—digestive, respiratory, circulatory, renal, nervous, and cutaneous. It was thought proper to include also a consideration of the disorders of pregnancy.

The articles, with two exceptions, are the contributions of American writers. Written from the standpoint of the practitioner, the aim of the work is to facilitate the application of knowledge to the prevention, the cure, and the alleviation of disease. The endeavor throughout has been to conform to the title of the book—Applied Therapeutics—to indicate the course of treatment to be pursued at the bedside, rather than to name a list of drugs that have been used at one time or another.

The list of contributors comprises the names of many who have acquired distinction as practitioners and teachers of practice, of clinical medicine, and of the specialties.

CONTRIBUTORS:

Dr. I. E. Atkinson, Baltimore, Md.
Sanger Brown, Chicago, Ill.
John B. Chapin, Philadelphia, Pa.
William C. Dabney, Charlottesville, Va.
John Chalmers DaCosta, Philada., Pa.
I. N. Danforth, Chicago, Ill.
John L. Dawson, Jr., Charleston, S. C.
F. X. Dercum, Philadelphia, Pa.
George Dock, Ann Arbor, Mich.
Robert T. Edes, Jamaica Plain, Mass.
Augustus A. Eshner, Philadelphia, Pa.
J. T. Eskridge, Denver, Col.
F. Forchheimer, Cincinnati, O.
Carl Frese, Philadelphia, Pa.
Edwin E. Graham, Philadelphia, Pa.
John Guitéras, Philadelphia, Pa.
Frederick P. Henry, Philadelphia, Pa.
Guy Hinsdale, Philadelphia, Pa.
Orville Horwitz, Philadelphia, Pa.
W. W. Johnston, Washington, D. C.
Ernest Laplace, Philadelphia, Pa.
A. Laveran, Paris, France.
Dr. James Hendrie Lloyd, Philadelphia, Pa.
John Noland Mackenzie, Baltimore, Md.
J. W. McLaughlin, Austin, Texas.
A. Lawrence Mason, Boston, Mass.
Charles K. Mills, Philadelphia, Pa.
John K. Mitchell, Philadelphia, Pa.
W. P. Northrup, New York City.
William Osler, Baltimore, Md.
Frederick A. Packard, Philadelphia, Pa.
Theophilus Parvin, Philadelphia, Pa.
Beaven Rake, London, England.
E. O. Shakespeare, Philadelphia, Pa.
Wharton Sinkler, Philadelphia, Pa.
Louis Starr, Philadelphia, Pa.
Henry W. Stelwagon, Philadelphia, Pa.
James Stewart, Montreal, Canada.
Charles G. Stockton, Buffalo, N. Y.
James Tyson, Philadelphia, Pa.
Victor C. Vaughan, Ann Arbor, Mich.
James T. Whittaker, Cincinnati, O.
J. C. Wilson, Philadelphia, Pa.

"As a work either for study or reference it will be of great value to the practitioner, as it is virtually an exposition of such clinical therapeutics as experience has taught to be of the most value. Taking it all in all, no recent publication on therapeutics can be compared with this one in practical value to the working physician."—*Chicago Clinical Review.*

"The whole field of medicine has been well covered. The work is thoroughly practical, and while it is intended for practitioners and students, it is a better book for the general practitioner than for the student. The young practitioner especially will find it extremely suggestive and helpful."—*The Indian Lancet.*

***AN AMERICAN TEXT-BOOK OF OBSTETRICS.** Edited by RICHARD C. NORRIS, M. D.; Art Editor, ROBERT L. DICKINSON, M. D. One handsome octavo volume of over 1000 pages, with nearly 900 colored and half-tone illustrations. Prices: Cloth, $7.00 net; Sheep or Half Morocco, $8.00 net.

The advent of each successive volume of the *series* of the AMERICAN TEXT-BOOKS has been signalized by the most flattering comment from both the Press and the Profession. The high consideration received by these text-books, and their attainment to an authoritative position in current medical literature, have been matters of deep *international* interest, which finds its fullest expression in the demand for these publications from all parts of the civilized world.

In the preparation of the "AMERICAN TEXT-BOOK OF OBSTETRICS" the editor has called to his aid proficient collaborators whose professional prominence entitles them to recognition, and whose disquisitions exemplify **Practical Obstetrics.** While these writers were each assigned special themes for discussion, the correlation of the subject-matter is, nevertheless, such as ensures logical connection in treatment, the deductions of which thoroughly represent the latest advances in the science, and which elucidate *the best modern methods of procedure.*

The more conspicuous feature of the treatise is its wealth of illustrative matter. The production of the illustrations had been in progress for several years, under the personal supervision of Robert L. Dickinson, M. D., to whose artistic judgment and professional experience is due the **most sumptuously illustrated work of the period.** By means of the photographic art, combined with the skill of the artist and draughtsman, conventional illustration is superseded by rational methods of delineation.

Furthermore, the volume is a revelation as to the possibilities that may be reached in mechanical execution, through the unsparing hand of its publisher.

CONTRIBUTORS:

Dr. James C. Cameron.
Edward P. Davis.
Robert L. Dickinson.
Charles Warrington Earle.
James H. Etheridge.
Henry J. Garrigues.
Barton Cooke Hirst.
Charles Jewett.
Dr. Howard A. Kelly.
Richard C. Norris.
Chauncey D. Palmer.
Theophilus Parvin.
George A. Piersol.
Edward Reynolds.
Henry Schwarz.

"At first glance we are overwhelmed by the magnitude of this work in several respects, viz.: First, by the size of the volume, then by the array of eminent teachers in this department who have taken part in its production, then by the profuseness and character of the illustrations, and last, but not least, the conciseness and clearness with which the text is rendered. This is an entirely new composition, embodying the highest knowledge of the art as it stands to-day by authors who occupy the front rank in their specialty, and there are many of them. We cannot turn over these pages without being struck by the superb illustrations which adorn so many of them. We are confident that this most practical work will find instant appreciation by practitioners as well as students."—*New York Medical Times.*

Permit me to say that your American Text-Book of Obstetrics is the most magnificent medical work that I have ever seen. I congratulate you and thank you for this superb work, which alone is sufficient to place you first in the ranks of medical publishers.

With profound respect I am sincerely yours, ALEX. J. C. SKENE.

***AN AMERICAN TEXT-BOOK OF THE THEORY AND PRACTICE OF MEDICINE. By American Teachers.** Edited by WILLIAM PEPPER, M. D., LL.D., Provost and Professor of the Theory and Practice of Medicine and of Clinical Medicine in the University of Pennsylvania. Complete in two handsome royal-octavo volumes of about 1000 pages each, with illustrations to elucidate the text wherever necessary. Price per Volume: Cloth, $5.00 net; Sheep or Half-Morocco, $6.00 net.

VOLUME I. CONTAINS:

Hygiene.—Fevers (Ephemeral, Simple Continued, Typhus, Typhoid, Epidemic Cerebro-spinal Meningitis, and Relapsing).—Scarlatina, Measles, Rötheln, Variola, Varioloid, Vaccinia, Varicella, Mumps, Whooping-cough, Anthrax, Hydrophobia, Trichinosis, Actinomycosis, Glanders, and Tetanus.—Tuberculosis, Scrofula, Syphilis, Diphtheria, Erysipelas, Malaria, Cholera, and Yellow Fever.—Nervous, Muscular, and Mental Diseases etc.

VOLUME II. CONTAINS:

Urine (Chemistry and Microscopy).—Kidney and Lungs.—Air-passages (Larynx and Bronchi) and Pleura.—Pharynx, Œsophagus, Stomach and Intestines (including Intestinal Parasites), Heart, Aorta, Arteries and Veins.—Peritoneum, Liver, and Pancreas.—Diathetic Diseases (Rheumatism, Rheumatoid Arthritis, Gout, Lithæmia, and Diabetes.)—Blood and Spleen.—Inflammation, Embolism, Thrombosis, Fever, and Bacteriology.

The articles are not written as though addressed to students in lectures, but are exhaustive descriptions of diseases, with the newest facts as regards Causation, Symptomatology, Diagnosis, Prognosis, and Treatment, including a large number of approved formulæ. The recent advances made in the study of the bacterial origin of various diseases are fully described, as well as the bearing of the knowledge so gained upon prevention and cure. The subjects of Bacteriology as a whole and of Immunity are fully considered in a separate section.

Methods of diagnosis are given the most minute and careful attention, thus enabling the reader to learn the very latest methods of investigation without consulting works specially devoted to the subject.

CONTRIBUTORS:

Dr. J. S. Billings, Philadelphia.
Francis Delafield, New York.
Reginald H. Fitz, Boston.
James W. Holland, Philadelphia.
Henry M. Lyman, Chicago.
William Osler, Baltimore.
Dr. William Pepper, Philadelphia.
W. Gilman Thompson, New York.
W. H. Welch, Baltimore.
James T. Whittaker, Cincinnati.
James C. Wilson, Philadelphia.
Horatio C. Wood, Philadelphia.

"We reviewed the first volume of this work, and said: 'It is undoubtedly one of the best text-books on the practice of medicine which we possess.' A consideration of the second and last volume leads us to modify that verdict and to say that the completed work is, in our opinion, THE BEST of its kind it has ever been our fortune to see. It is complete, thorough, accurate, and clear. It is well written, well arranged, well printed, well illustrated, and well bound. It is a model of what the modern text-book should be."—*New York Medical Journal.*

"A library upon modern medical art. The work must promote the wider diffusion of sound knowledge."—*American Lancet.*

"A trusty counsellor for the practitioner or senior student, on which he may implicitly rely."—*Edinburgh Medical Journal.*

***AN AMERICAN TEXT-BOOK OF SURGERY.** Edited by WILLIAM W. KEEN, M. D., LL.D., and J. WILLIAM WHITE, M. D., PH. D. Forming one handsome royal octavo volume of 1230 pages (10×7 inches), with 496 wood-cuts in text, and 37 colored and half-tone plates, many of them engraved from original photographs and drawings furnished by the authors. Price: Cloth, $7.00 net; Sheep or Half Morocco, $8.00 net.

THIRD EDITION. THOROUGHLY REVISED.

In the present edition, among the new topics introduced are a full consideration of serum-therapy; leucocytosis; post-operative insanity; the use of dry heat at high temperatures; Krönlein's method of locating the cerebral fissures; Hoffa's and Lorenz's operations of congenital dislocations of the hip; Allis's researches on dislocations of the hip-joint; lumbar puncture; the forcible reposition of the spine in Pott's disease; the treatment of exophthalmic goiter; the surgery of typhoid fever; gastrectomy and other operations on the stomach; new methods of operating upon the intestines; the use of Kelly's rectal specula; the surgery of the ureter; Schleich's infiltration-method and the use of eucain for local anesthesia; Krause's method of skin-grafting; the newer methods of disinfecting the hands; the use of gloves, etc. The sections on Appendicitis, on Fractures, and on Gynecological Operations have been revised and enlarged. A considerable number of new illustrations have been added, and enhance the value of the work.

The text of the entire book has been submitted to all the authors for their mutual criticism and revision—an idea in book-making that is entirely new and original. The book as a whole, therefore, expresses on all the important surgical topics of the day the consensus of opinion of the eminent surgeons who have joined in its preparation.

One of the most attractive features of the book is its illustrations. Very many of them are original and faithful reproductions of photographs taken directly from patients or from specimens.

CONTRIBUTORS:

Dr. Phineas S. Conner, Cincinnati.
Frederic S. Dennis, New York.
William W. Keen, Philadelphia.
Charles B. Nancrede, Ann Arbor, Mich.
Roswell Park, Buffalo, New York.
Lewis S. Pilcher, New York.
Dr. Nicholas Senn, Chicago.
Francis J. Shepherd, Montreal, Canada.
Lewis A. Stimson, New York.
J. Collins Warren, Boston.
J. William White, Philadelphia.

"If this text-book is a fair reflex of the present position of American surgery, we must admit it is of a very high order of merit, and that English surgeons will have to look very carefully to their laurels if they are to preserve a position in the van of surgical practice."—*London Lancet.*

Personally, I should not mind it being called THE TEXT-BOOK (instead of A TEXT-BOOK), for I know of no single volume which contains so readable and complete an account of the science and art of Surgery as this does."—EDMUND OWEN, F. R. C. S., *Member of the Board of Examiners of the Royal College of Surgeons, England.*

***AN AMERICAN TEXT-BOOK OF GYNECOLOGY, MEDICAL AND SURGICAL, for the use of Students and Practitioners.** Edited by J. M. BALDY, M. D. Forming a handsome royal-octavo volume of 718 pages, with 341 illustrations in the text and 38 colored and half-tone plates. Prices: Cloth, $6.00 net; Sheep or Half-Morocco, $7.00 net.

SECOND EDITION, THOROUGHLY REVISED.

In this volume all anatomical descriptions, excepting those essential to a clear understanding of the text, have been omitted, the illustrations being largely depended upon to elucidate the anatomy of the parts. This work, which is thoroughly practical in its teachings, is intended, as its title implies, to be a working text-book for physicians and students. A clear line of treatment has been laid down in every case, and although no attempt has been made to discuss mooted points, still the most important of these have been noted and explained. The operations recommended are fully illustrated, so that the reader, having a picture of the procedure described in the text under his eye, cannot fail to grasp the idea. All extraneous matter and discussions have been carefully excluded, the attempt being made to allow no unnecessary details to cumber the text. The subject-matter is brought up to date at every point, and the work is as nearly as possible the combined opinions of the ten specialists who figure as the authors.

In the revised edition much new material has been added, and some of the old eliminated or modified. More than forty of the old illustrations have been replaced by new ones, which add very materially to the elucidation of the text, as they picture methods, not specimens. The chapters on technique and after-treatment have been considerably enlarged, and the portions devoted to plastic work have been so greatly improved as to be practically new. Hysterectomy has been rewritten, and all the descriptions of operative procedures have been carefully revised and fully illustrated.

CONTRIBUTORS:

Dr. Henry T. Byford.
John M. Baldy.
Edwin Cragin.
J. H. Etheridge.
William Goodell.
Dr. Howard A. Kelly.
Florian Krug.
E. E. Montgomery.
William R. Pryor.
George M. Tuttle.

"The most notable contribution to gynecological literature since 1887, ... and the most complete exponent of gynecology which we have. No subject seems to have been neglected, ... and the gynecologist and surgeon, and the general practitioner who has any desire to practise diseases of women, will find it of practical value. In the matter of illustrations and plates the book surpasses anything we have seen."—*Boston Medical and Surgical Journal.*

"A thoroughly modern text-book, and gives reliable and well-tempered advice and instruction."—*Edinburgh Medical Journal.*

"The harmony of its conclusions and the homogeneity of its style give it an individuality which suggests a single rather than a multiple authorship."—*Annals of Surgery.*

"It must command attention and respect as a worthy representation of our advanced cal teaching."—*American Journal of Medical Sciences.*

***AN AMERICAN TEXT-BOOK OF THE DISEASES OF CHILDREN. By American Teachers.** Edited by LOUIS STARR, M. D., assisted by THOMPSON S. WESTCOTT, M. D. In one handsome royal-8vo volume of 1244 pages, profusely illustrated with wood-cuts, half-tone and colored plates. Net Prices: Cloth, $7.00; Sheep or Half-Morocco, $8.00.

SECOND EDITION, REVISED AND ENLARGED.

The plan of this work embraces a series of original articles written by some sixty well-known pædiatrists, representing collectively the teachings of the most prominent medical schools and colleges of America. The work is intended to be a PRACTICAL book, suitable for constant and handy reference by the practitioner and the advanced student.

Especial attention has been given to the latest accepted teachings upon the etiology, symptoms, pathology, diagnosis, and treatment of the disorders of children, with the introduction of many special formulæ and therapeutic procedures.

In this new edition the whole subject matter has been carefully revised, new articles added, some original papers emended, and a number entirely rewritten. The new articles include "Modified Milk and Percentage Milk-Mixtures," "Lithemia," and a section on "Orthopedics." Those rewritten are "Typhoid Fever," "Rubella," "Chicken-pox," "Tuberculous Meningitis," "Hydrocephalus," and "Scurvy;" while extensive revision has been made in "Infant Feeding," "Measles," "Diphtheria," and "Cretinism." The volume has thus been much increased in size by the introduction of fresh material.

CONTRIBUTORS:

Dr. S. S. Adams, Washington.
John Ashhurst, Jr., Philadelphia.
A. D. Blackader, Montreal, Canada.
David Bovaird, New York.
Dillon Brown, New York.
Edward M. Buckingham, Boston.
Charles W. Burr, Philadelphia.
W. E. Casselberry, Chicago.
Henry Dwight Chapin, New York.
W. S. Christopher, Chicago.
Archibald Church, Chicago.
Floyd M. Crandall, New York.
Andrew F. Currier, New York.
Roland G. Curtin, Philadelphia
J. M. DaCosta, Philadelphia.
I. N. Danforth, Chicago.
Edward P. Davis, Philadelphia.
John B. Deaver, Philadelphia.
G. E. de Schweinitz, Philadelphia.
John Dorning, New York.
Charles Warrington Earle, Chicago.
Wm. A. Edwards, San Diego, Cal.
F. Forchheimer, Cincinnati.
J. Henry Fruitnight, New York.
J. P. Crozer Griffith, Philadelphia.
W. A. Hardaway, St. Louis.
M. P Hatfield, Chicago.
Barton Cooke Hirst, Philadelphia.
H. Illoway, Cincinnati.
Henry Jackson, Boston.
Charles G. Jennings, Detroit.
Henry Koplik, New York.
Dr. Thomas S. Latimer, Baltimore.
Albert R. Leeds, Hoboken, N. J.
J. Hendrie Lloyd, Philadelphia.
George Roe Lockwood, New York.
Henry M. Lyman, Chicago.
Francis T. Miles, Baltimore.
Charles K Mills, Philadelphia.
James E. Moore, Minneapolis.
F. Gordon Morrill, Boston.
John H. Musser, Philadelphia.
Thomas R. Neilson, Philadelphia.
W. P. Northrup, New York.
William Osler, Baltimore.
Frederick A. Packard, Philadelphia.
William Pepper, Philadelphia.
Frederick Peterson, New York.
W. T. Plant, Syracuse, New York.
William M. Powell, Atlantic City.
B. K. Rachford, Cincinnati.
B. Alexander Randall, Philadelphia.
Edward O. Shakespeare, Philadelphia
F. C. Shattuck, Boston.
J. Lewis Smith, New York.
Louis Starr, Philadelphia.
M. Allen Starr, New York.
Charles W. Townsend, Boston.
James Tyson, Philadelphia.
W. S. Thayer, Baltimore.
Victor C. Vaughan, Ann Arbor, Mich
Thompson S. Westcott, Philadelphia.
Henry R. Wharton, Philadelphia.
J. William White, Philadelphia.
J. C. Wilson, Philadelphia.

*** AN AMERICAN TEXT-BOOK OF GENITO-URINARY AND SKIN DISEASES.** By 47 Eminent Specialists and Teachers. Edited by L. BOLTON BANGS, M. D., Professor of Genito-Urinary Surgery, University and Bellevue Hospital Medical College, New York; and W. A. HARDAWAY, M. D., Professor of Diseases of the Skin, Missouri Medical College. Imperial octavo volume of 1229 pages, with 300 engravings and 20 full-page colored plates. Cloth, $7.00 net; Sheep or Half Morocco, $8.00 net.

This addition to the series of "American Text-Books," it is confidently believed, will meet the requirements of both students and practitioners, giving, as it does, a comprehensive and detailed presentation of the Diseases of the Genito-Urinary Organs, of the Venereal Diseases, and of the Affections of the Skin.

Having secured the collaboration of well-known authorities in the branches represented in the undertaking, the editors have not restricted the contributors in regard to the particular views set forth, but have offered every facility for the free expression of their individual opinions. The work will therefore be found to be original, yet homogeneous and fully representative of the several departments of medical science with which it is concerned.

CONTRIBUTORS:

Dr. Chas. W. Allen, New York.
I. E. Atkinson, Baltimore.
L. Bolton Bangs, New York.
P. R. Bolton, New York.
Lewis C. Bosher, Richmond, Va.
John T. Bowen, Boston.
J. Abbott Cantrell, Philadelphia.
William T. Corlett, Cleveland, Ohio.
B. Farquhar Curtis, New York.
Condict W. Cutler, New York.
Isadore Dyer, New Orleans.
Christian Fenger, Chicago.
John A. Fordyce, New York.
Eugene Fuller, New York.
R. H. Greene, New York.
Joseph Grindon, St. Louis.
Graeme M. Hammond, New York.
W. A. Hardaway, St. Louis.
M. B. Hartzell, Philadelphia.
Louis Heitzmann, New York.
James S. Howe, Boston.
George T. Jackson, New York.
Abraham Jacobi, New York.
James C. Johnston, New York.
Dr. Hermann G. Klotz, New York.
J. H. Linsley, Burlington, Vt.
G. F. Lydston, Chicago.
Hartwell N. Lyon, St. Louis.
Edward Martin, Philadelphia.
D. G. Montgomery, San Francisco.
James Pedersen, New York.
S. Pollitzer, New York.
Thomas R. Pooley, New York.
A. R. Robinson, New York.
A. E. Regensburger, San Francisco.
Francis J. Shepherd, Montreal, Can.
S. C. Stanton, Chicago, Ill.
Emmanuel J. Stout, Philadelphia.
Alonzo E. Taylor Philadelphia.
Robert W. Taylor, New York.
Paul Thorndike, Boston.
H. Tuholske, St. Louis.
Arthur Van Harlingen, Philadelphia.
Francis S. Watson, Boston.
J. William White, Philadelphia.
J. McF. Winfield, Brooklyn.
Alfred C. Wood, Philadelphia.

"This voluminous work is thoroughly up to date, and the chapters on genito-urinary diseases are especially valuable. The illustrations are fine and are mostly original. The section on dermatology is concise and in every way admirable."—*Journal of the American Medical Association.*

"This volume is one of the best yet issued of the publisher's series of 'American Text-Books.' The list of contributors represents an extraordinary array of talent and extended experience. The book will easily take the place in comprehensiveness and value of the half dozen or more costly works on these subjects which have hitherto been necessary to a well-equipped library."—*New York Polyclinic.*

*** AN AMERICAN TEXT-BOOK OF DISEASES OF THE EYE, EAR, NOSE, AND THROAT.** Edited by GEORGE E. DE SCHWEINITZ, A. M., M. D., Professor of Ophthalmology, Jefferson Medical College; and B. ALEXANDER RANDALL, A. M., M. D., Clinical Professor of Diseases of the Ear, University of Pennsylvania. One handsome imperial octavo volume of 1251 pages; 766 illustrations, 59 of them colored. Prices: Cloth, $7.00 net; Sheep or Half-Morocco, $8.00 net.

Just Issued.

The present work is the only book ever published embracing diseases of the intimately related organs of the eye, ear, nose, and throat. Its special claim to favor is based on encyclopedic, authoritative, and practical treatment of the subjects.

Each section of the book has been entrusted to an author who is specially identified with the subject on which he writes, and who therefore presents his case in the manner of an expert. Uniformity is secured and overlapping prevented by careful editing and by a system of cross-references which forms a special feature of the volume, enabling the reader to come into touch with all that is said on any subject in different portions of the book.

Particular emphasis is laid on the most approved methods of treatment, so that the book shall be one to which the student and practitioner can refer for information in practical work. Anatomical and physiological problems, also, are fully discussed for the benefit of those who desire to investigate the more abstruse problems of the subject.

CONTRIBUTORS:

Dr. Henry A. Alderton, Brooklyn.
Harrison Allen, Philadelphia.
Frank Allport, Chicago.
Morris J. Asch, New York.
S. C. Ayres, Cincinnati.
R. O. Beard, Minneapolis.
Clarence J. Blake, Boston.
Arthur A. Bliss, Philadelphia.
Albert P. Brubaker, Philadelphia.
J. H. Bryan, Washington, D. C.
Albert H. Buck, New York.
F. Buller, Montreal, Can.
Swan M. Burnett, Washington, D. C.
Flemming Carrow, Ann Arbor, Mich.
W. E. Casselberry, Chicago.
Colman W. Cutler, New York.
Edward B. Dench, New York.
William S. Dennett, New York.
George E. de Schweinitz, Philadelphia.
Alexander Duane, New York.
John W. Farlow, Boston, Mass.
Walter J. Freeman, Philadelphia.
H. Gifford, Omaha, Neb.
W. C. Glasgow, St. Louis.
J. Orne Green, Boston.
Ward A. Holden, New York.
Christian R. Holmes, Cincinnati.
William E. Hopkins, San Francisco.
F. C. Hotz, Chicago.
Lucien Howe, Buffalo, N. Y.
Dr. Alvin A. Hubbell, Buffalo, N. Y.
Edward Jackson, Philadelphia.
J. Ellis Jennings, St. Louis.
Herman Knapp, New York.
Chas. W. Kollock, Charleston, S. C.
G. A. Leland, Boston.
J. A. Lippincott, Pittsburg, Pa.
G. Hudson Makuen, Philadelphia.
John H. McCollom, Boston.
H. G. Miller, Providence, R. I.
B. L. Milliken, Cleveland, Ohio.
Robert C. Myles, New York.
James E. Newcomb, New York.
R. J. Phillips, Philadelphia.
George A. Piersol, Philadelphia.
W. P. Porcher, Charleston, S. C.
B. Alex. Randall, Philadelphia.
Robert L. Randolph, Baltimore.
John O. Roe, Rochester, N. Y.
Charles E. de M. Sajous, Philadelphia.
J. E. Sheppard, Brooklyn, N. Y.
E. L. Shurly, Detroit, Mich.
William M. Sweet, Philadelphia.
Samuel Theobald, Baltimore, Md.
A. G. Thomson, Philadelphia.
Clarence A. Veasey, Philadelphia.
John E. Weeks, New York.
Casey A. Wood, Chicago, Ill.
Jonathan Wright, Brooklyn.
H. V. Würdemann, Milwaukee, Wis.

***AN AMERICAN YEAR-BOOK OF MEDICINE AND SURGERY.** A Yearly Digest of Scientific Progress and Authoritative Opinion in all branches of Medicine and Surgery, drawn from journals, monographs, and text-books of the leading American and Foreign authors and investigators. Collected and arranged, with critical editorial comments, by eminent American specialists and teachers, under the general editorial charge of GEORGE M. GOULD, M. D. Volumes for 1896, '97, '98, and '99 each a handsome imperial octavo volume of about 1200 pages. Prices: Cloth, $6.50 net; Half-Morocco, $7.50 net. Year-Book for 1900 in two octavo volumes of about 600 pages each. Prices per volume: Cloth, $3.00 net; Half-Morocco, $3.75 net.

In Two Volumes. No Increase in Price.

In response to a widespread demand from the medical profession, the publisher of the "American Year-Book of Medicine and Surgery" has decided to issue that well-known work in two volumes, Vol. I. treating of **General Medicine**, Vol. II. of **General Surgery**. Each volume is complete in itself, and the work is sold either separately or in sets.

This division is made in such a way as to appeal to physicians from a class standpoint, one volume being distinctly medical, and the other distinctly surgical. This arrangement has a two-fold advantage. To the physician who uses the entire book, it offers an increased amount of matter in the most convenient form for easy consultation, and without any increase in price; while the man who wants either the medical or the surgical section alone secures the complete consideration of his branch without the necessity of purchasing matter for which he has no use.

CONTRIBUTORS:

VOL. I.

Dr. Samuel W. Abbott, Boston.
Archibald Church, Chicago.
Louis A. Duhring, Philadelphia.
D. L. Edsall, Philadelphia.
Alfred Hand, Jr., Philadelphia.
M. B. Hartzell, Philadelphia.
Reid Hunt, Baltimore.
Wyatt Johnston, Montreal.
Walter Jones, Baltimore.
David Riesman, Philadelphia.
Louis Starr, Philadelphia.
Alfred Stengel, Philadelphia.
A. A. Stevens, Philadelphia.
G. N. Stewart, Cleveland.
Reynold W. Wilcox, New York City.

VOL. II.

Dr. J. Montgomery Baldy, Philadelphia.
Charles H. Burnett, Philadelphia.
J. Chalmers DaCosta, Philadelphia.
W. A. N. Dorland, Philadelphia.
Virgil P. Gibney, New York City.
C. H. Hamann, Cleveland.
Howard F. Hansell, Philadelphia.
Barton Cooke Hirst, Philadelphia.
E. Fletcher Ingals, Chicago.
W. W. Keen, Philadelphia.
Henry G. Ohls, Chicago.
Wendell Reber, Philadelphia.
J. Hilton Waterman, New York City.

"It is difficult to know which to admire most—the research and industry of the distinguished band of experts whom Dr. Gould has enlisted in the service of the Year-Book, or the wealth and abundance of the contributions to every department of science that have been deemed worthy of analysis. . . . It is much more than a mere compilation of abstracts, for, as each section is entrusted to experienced and able contributors, the reader has the advantage of certain critical commentaries and expositions . . . proceeding from writers fully qualified to perform these tasks. . . . It is emphatically a book which should find a place in every medical library, and is in several respects more useful than the famous 'Jahrbucher' of Germany."—*London Lancet.*

*** ANOMALIES AND CURIOSITIES OF MEDICINE.** By GEORGE M. GOULD, M.D., and WALTER L. PYLE, M.D. An encyclopedic collection of are and extraordinary cases and of the most striking instances of abnormality in all branches of Medicine and Surgery, derived from an exhaustive research of medical literature from its origin to the present day, abstracted, classified, annotated, and indexed. Handsome imperial octavo volume of 968 pages, with 295 engravings in the text, and 12 full-page plates. Cloth, $3.00 net; Half-Morocco, $4.00 net.

POPULAR EDITION REDUCED FROM $6.00 to $3.00.

In view of the great success of this magnificent work, the publisher has decided to issue a "Popular Edition" at a price so low that it may be procured by every student and practitioner of medicine. Notwithstanding the great reduction in price, there will be no depreciation in the excellence of typography, paper, and binding that characterized the earlier editions.

Several years of exhaustive research have been spent by the authors in the great medical libraries of the United States and Europe in collecting the material for this work. **Medical literature of all ages and all languages** has been carefully searched, as a glance at the Bibliographic Index will show. The facts, which will be of **extreme value to the author and lecturer,** have been arranged and annotated, and full reference footnotes given.

"One of the most valuable contributions ever made to medical literature. It is, so far as we know, absolutely unique, and every page is as fascinating as a novel. Not alone for the medical profession has this volume value: it will serve as a book of reference for all who are interested in general scientific, sociologic, or medico-legal topics."—*Brooklyn Medical Journal.*

NERVOUS AND MENTAL DISEASES. By ARCHIBALD CHURCH, M. D., Professor of Clinical Neurology, Mental Diseases, and Medical Jurisprudence, Northwestern University Medical School; and FREDERICK PETERSON, M. D., Clinical Professor of Mental Diseases, Woman's Medical College, New York. Handsome octavo volume of 843 pages, with over 300 illustrations. Prices: Cloth, $5.00 net; Half-Morocco, $6.00 net.

Second Edition.

This book is intended to furnish students and practitioners with a practical, working knowledge of nervous and mental diseases. Written by men of wide experience and authority, it presents the many recent additions to the subject. The book is not filled with an extended dissertation on anatomy and pathology, but, treating these points in connection with special conditions, it lays particular stress on methods of examination, diagnosis, and treatment. In this respect the work is unusually complete and valuable, laying down the definite courses of procedure which the authors have found to be most generally satisfactory.

"The work is an epitome of what is to-day known of nervous diseases prepared for the student and practitioner in the light of the author's experience . . . We believe that no work presents the difficult subject of insanity in such a reasonable and readable way."—*Chicago Medical Recorder.*

DISEASES OF THE NOSE AND THROAT. By D. BRADEN KYLE, M. D., Clinical Professor of Laryngology and Rhinology, Jefferson Medical College, Philadelphia; Consulting Laryngologist, Rhinologist, and Otologist, St. Agnes' Hospital. Octavo volume of 646 pages, with over 150 illustrations and 6 lithographic plates. Cloth, $4.00 net; Half-Morocco, $5.00 net.

Just Issued.

This book presents the subject of Diseases of the Nose and Throat in as concise a manner as is consistent with clearness, keeping in mind the needs of the student and general practitioner as well as those of the specialist. The arrangement and classification are based on modern pathology, and the pathological views advanced are supported by drawings of microscopical sections made in the author's own laboratory. These and the other illustrations are particularly fine, being chiefly original. With the practical purpose of the book in mind, extended consideration has been given to details of treatment, each disease being considered in full, and definite courses being laid down to meet special conditions and symptoms.

"It is a thorough, full, and systematic treatise, so classified and arranged as greatly to facilitate the teaching of laryngology and rhinology to classes, and must prove most convenient and satisfactory as a reference book, both for students and practitioners."—*International Medical Magazine.*

THE HYGIENE OF TRANSMISSIBLE DISEASES: their Causation, Modes of Dissemination, and Methods of Prevention. By A. C. ABBOTT, M. D., Professor of Hygiene in the University of Pennsylvania; Director of the Laboratory of Hygiene. Octavo volume of 311 pages, with charts and maps, and numerous illustrations. Cloth, $2.00 net.

Just Issued.

It is not the purpose of this work to present the subject of Hygiene in the comprehensive sense ordinarily implied by the word, but rather to deal directly with but a section, certainly not the least important, of the subject—viz., that embracing a knowledge of the preventable specific diseases. The book aims to furnish information concerning the detailed management of transmissible diseases. Incidentally there are discussed those numerous and varied factors that have not only a direct bearing upon the incidence and suppression of such diseases, but are of general sanitary importance as well.

"The work is admirable in conception and no less so in execution. It is a practical work, simply and lucidly written, and it should prove a most helpful aid in that department of medicine which is becoming daily of increasing importance and application—namely, prophylaxis."—*Philadelphia Medical Journal.*

"It is scientific, but not too technical; it is as complete as our present-day knowledge of hygiene and sanitation allows, and it is in harmony with the efforts of the profession, which are tending more and more to methods of prophylaxis. For the student and for the practitioner it is well nigh indispensable."—*Medical News*, New York.

A TEXT-BOOK OF EMBRYOLOGY. By JOHN C. HEISLER, M. D., Professor of Anatomy in the Medico-Chirurgical College, Philadelphia. Octavo volume of 405 pages, with 190 illustrations, 26 in colors. Cloth, $2.50 net.

Just Issued.

The facts of embryology having acquired in recent years such great interest in connection with the teaching and with the proper comprehension of human anatomy, it is of first importance to the student of medicine that a concise and yet sufficiently full text-book upon the subject be available. It was with the aim of presenting such a book that this volume was written, the author, in his experience as a teacher of anatomy, having been impressed with the fact that students were seriously handicapped in their study of the subject of embryology by the lack of a text-book full enough to be intelligible, and yet without that minuteness of detail which characterizes the larger treatises, and which so often serves only to confuse and discourage the beginner.

"In short, the book is written to fill a want which has distinctly existed and which it definitely meets; commendation greater than this it is not possible to give to anything."—*Medical News*, New York.

A MANUAL OF DISEASES OF THE EYE. By EDWARD JACKSON, A. M., M. D., sometime Professor of Diseases of the Eye in the Philadelphia Polyclinic and College for Graduates in Medicine. 12mo, 604 pages, with 178 illustrations from drawings by the author. Cloth, $2.50 net.

Just Issued.

This book is intended to meet the needs of the general practitioner of medicine and the beginner in ophthalmology. More attention is given to the conditions that must be met and dealt with early in ophthalmic practice than to the rarer diseases and more difficult operations that may come later.

It is designed to furnish efficient aid in the actual work of dealing with disease, and therefore gives the place of first importance to the recognition and management of the conditions that present themselves in actual clinical work.

LECTURES ON THE PRINCIPLES OF SURGERY. By CHARLES B. NANCREDE, M. D., LL.D., Professor of Surgery and of Clinical Surgery, University of Michigan, Ann Arbor. Handsome octavo, 398 pages, illustrated. Cloth, $2.50 net.

Just Issued.

The present book is based on the lectures delivered by Dr. Nancrede to his undergraduate classes, and is intended as a text-book for students and a practical help for teachers. By the careful elimination of unnecessary details of pathology, bacteriology, etc., which are amply provided for in other courses of study, space is gained for a more extended consideration of the Principles of Surgery in themselves, and of the application of these principles to methods of practice.

A TEXT-BOOK OF PATHOLOGY. By ALFRED STENGEL, M.D., Professor of Clinical Medicine in the University of Pennsylvania; Physician to the Philadelphia Hospital; Physician to the Children's Hospital, Philadelphia. Handsome octavo volume of 848 pages, with 362 illustrations, many of which are in colors. Prices: Cloth, $4.00 net; Half-Morocco, $5.00 net.

Second Edition.

In this work the practical application of pathological facts to clinical medicine is considered more fully than is customary in works on pathology. While the subject of pathology is treated in the broadest way consistent with the size of the book, an effort has been made to present the subject from the point of view of the clinician. The general relations of bacteriology to pathology are discussed at considerable length, as the importance of these branches deserves. It will be found that the recent knowledge is fully considered, as well as older and more widely-known facts.

"I consider the work abreast of modern pathology, and useful to both students and practitioners. It presents in a concise and well-considered form the essential facts of general and special pathological anatomy, with more than usual emphasis upon pathological physiology."—WILLIAM H. WELCH, *Professor of Pathology, Johns Hopkins University, Baltimore, Md.*

"I regard it as the most serviceable text-book for students on this subject yet written by an American author."—L. HEKTOEN, *Professor of Pathology, Rush Medical College, Chicago, Ill.*

A TEXT-BOOK OF OBSTETRICS. By BARTON COOKE HIRST, M.D., Professor of Obstetrics in the University of Pennsylvania. Handsome octavo volume of 846 pages, with 618 illustrations and seven colored plates. Prices: Cloth, $5.00 net; Half-Morocco, $6.00 net.

Second Edition.

This work, which has been in course of preparation for several years, is intended as an ideal text-book for the student no less than an advanced treatise for the obstetrician and for general practitioners. It represents the very latest teaching in the practice of obstetrics by a man of extended experience and recognized authority. The book emphasizes especially, as a work on obstetrics should, the practical side of the subject, and to this end presents an unusually large collection of illustrations. A great number of these are new and original, and the whole collection will form a complete atlas of obstetrical practice. An extremely valuable feature of the book is the large number of references to cases, authorities, sources, etc., forming, as it does, a valuable bibliography of the most recent and authoritative literature on the subject of obstetrics. As already stated, this work records the wide practical experience of the author, which fact, combined with the brilliant presentation of the subject, will doubtless render this one of the most notable books on obstetrics that has yet appeared.

"The illustrations are numerous and are works of art, many of them appearing for the first time. The arrangement of the subject-matter, the foot-notes, and index are beyond criticism. The author's style, though condensed, is singularly clear, so that it is never necessary to re-read a sentence in order to grasp its meaning. As a true model of what a modern text-book in obstetrics should be, we feel justified in affirming that Dr. Hirst's book is without a rival."—*New York Medical Record.*

A TEXT-BOOK OF THE PRACTICE OF MEDICINE. By JAMES M. ANDERS, M.D., PH.D., LL.D., Professor of the Practice of Medicine and of Clinical Medicine, Medico-Chirurgical College, Philadelphia. In one handsome octavo volume of 1292 pages, fully illustrated. Cloth, $5.50 net; Sheep or Half-Morocco, $6.50 net.

THIRD EDITION, THOROUGHLY REVISED.

The present edition is the result of a careful and thorough revision. A few new subjects have been introduced: Glandular Fever, Ether-pneumonia, Splenic Anemia, Meralgia Paresthetica, and Periodic Paralysis. The affections that have been substantially rewritten are: Plague, Malta Fever, Diseases of the Thymus Gland, Liver Cirrhoses, and Progressive Spinal Muscular Atrophy. The following articles have been extensively revised: Typhoid Fever, Yellow Fever, Lobar Pneumonia, Dengue, Tuberculosis, Diabetes Mellitus, Gout, Arthritis Deformans, Autumnal Catarrh, Diseases of the Circulatory System, more particularly Hypertrophy and Dilatation of the Heart, Arteriosclerosis and Thoracic Aneurysm, Pancreatic Hemorrhage, Jaundice, Acute Peritonitis, Acute Yellow Atrophy, Hematoma of Dura Mater, and Scleroses of the Brain. The preliminary chapter on Nervous Diseases is new, and deals with the subject of localization and the various methods of investigating nervous affections.

"It is an excellent book—concise, comprehensive, thorough, and up to date. It is a credit to you; but, more than that, it is a credit to the profession of Philadelphia—to us." —JAMES C. WILSON, *Professor of the Practice of Medicine and Clinical Medicine, Jefferson Medical College, Philadelphia.*

"The book can be unreservedly recommended to students and practitioners as a safe, full compendium of the knowledge of internal medicine of the present day . . . It is a work thoroughly modern in every sense."—*Medical News*, New York.

DISEASES OF THE STOMACH. By WILLIAM W. VAN VALZAH, M. D., Professor of General Medicine and Diseases of the Digestive System and the Blood, New York Polyclinic; and J. DOUGLAS NISBET, M. D., Adjunct Professor of General Medicine and Diseases of the Digestive System and the Blood, New York Polyclinic. Octavo volume of 674 pages, illustrated. Cloth, $3.50 net.

An eminently practical book, intended as a guide to the student, an aid to the physician, and a contribution to scientific medicine. It aims to give a complete description of the modern methods of diagnosis and treatment of diseases of the stomach, and to reconstruct the pathology of the stomach in keeping with the revelations of scientific research. The book is clear, practical, and complete, and contains the results of the authors' investigations and of their extensive experience as specialists. Particular attention is given to the important subject of dietetic treatment. The diet-lists are very complete, and are so arranged that selections can readily be made to suit individual cases.

"This is the most satisfactory work on the subject in the English language."—*Chicago Medical Recorder.*

"The article on diet and general medication is one of the most valuable in the book, and should be read by every practising physician."—*New York Medical Journal.*

SURGICAL DIAGNOSIS AND TREATMENT. By J. W. MACDONALD, M. D., Edin., F. R. C. S., Edin., Professor of the Practice of Surgery and of Clinical Surgery in Hamline University; Visiting Surgeon to St. Barnabas' Hospital, Minneapolis, etc. Handsome octavo volume of 800 pages, profusely illustrated. Cloth, $5.00 net; Half-Morocco, $6.00 net.

This work aims in a comprehensive manner to furnish a guide in matters of surgical diagnosis. It sets forth in a systematic way the necessities of examinations and the proper methods of making them. The various portions of the body are then taken up in order and the diseases and injuries thereof succinctly considered and the treatment briefly indicated. Practically all the modern and approved operations are described with thoroughness and clearness. The work concludes with a chapter on the use of the Röntgen rays in surgery.

"The work is brimful of just the kind of practical information that is useful alike to students and practitioners. It is a pleasure to commend the book because of its intrinsic value to the medical practitioner."—*Cincinnati Lancet-Clinic.*

PATHOLOGICAL TECHNIQUE. A Practical Manual for Laboratory Work in Pathology, Bacteriology, and Morbid Anatomy, with chapters on Post-Mortem Technique and the Performance of Autopsies. By FRANK B. MALLORY, A. M., M. D., Assistant Professor of Pathology, Harvard University Medical School, Boston; and JAMES H. WRIGHT, A. M., M. D., Instructor in Pathology, Harvard University Medical School, Boston. Octavo volume of 396 pages, handsomely illustrated. Cloth, $2.50 net.

This book is designed especially for practical use in pathological laboratories, both as a guide to beginners and as a source of reference for the advanced. The book will also meet the wants of practitioners who have opportunity to do general pathological work. Besides the methods of post-mortem examinations and of bacteriological and histological investigations connected with autopsies, the special methods employed in clinical bacteriology and pathology have been fully discussed.

"One of the most complete works on the subject, and one which should be in the library of every physician who hopes to keep pace with the great advances made in pathology."—*Journal of American Medical Association.*

THE SURGICAL COMPLICATIONS AND SEQUELS OF TYPHOID FEVER. By WM. W. KEEN, M. D., LL.D., Professor of the Principles of Surgery and of Clinical Surgery, Jefferson Medical College, Philadelphia. Octavo volume of 386 pages, illustrated. Cloth, $3.00 net.

This monograph is the only one in any language covering the entire subject of the Surgical Complications and Sequels of Typhoid Fever. The work will prove to be of importance and interest not only to the general surgeon and physician, but also to many specialists—laryngologists, ophthalmologists, gynecologists, pathologists, and bacteriologists—as the subject has an important bearing upon each one of their spheres. The author's conclusions are based on reports of over 1700 cases, including practically all those recorded in the last fifty years. Reports of cases have been brought down to date, many having been added while the work was in press.

"This is probably the first and only work in the English language that gives the reader a clear view of what typhoid fever really is, and what it does and can do to the human organism. This book should be in the possession of every medical man in America."—*American Medico-Surgical Bulletin.*

MODERN SURGERY, GENERAL AND OPERATIVE. By JOHN CHALMERS DACOSTA, M.D., Clinical Professor of Surgery, Jefferson Medical College, Philadelphia; Surgeon to the Philadelphia Hospital, etc. Handsome octavo volume of 911 pages, profusely illustrated. Cloth, $4.00 net; Half-Morocco, $5.00 net.

Second Edition, Rewritten and Greatly Enlarged.

The remarkable success attending DaCosta's Manual of Surgery, and the general favor with which it has been received, have led the author in this revision to produce a complete treatise on modern surgery along the same lines that made the former edition so successful. The book has been entirely rewritten and very much enlarged. The old edition has long been a favorite not only with students and teachers, but also with practising physicians and surgeons, and it is believed that the present work will find an even wider field of usefulness.

"We know of no small work on surgery in the English language which so well fulfils the requirements of the modern student."—*Medico-Chirurgical Journal*, Bristol, England.

"The author has presented concisely and accurately the principles of modern surgery. The book is a valuable one which can be recommended to students and is of great value to the general practitioner."—*American Journal of the Medical Sciences.*

A MANUAL OF ORTHOPEDIC SURGERY. By JAMES E. MOORE, M.D., Professor of Orthopedics and Adjunct Professor of Clinical Surgery, University of Minnesota, College of Medicine and Surgery. Octavo volume of 356 pages, with 177 beautiful illustrations from photographs made specially for this work. Cloth, $2.50 net.

A practical book based upon the author's experience, in which special stress is laid upon early diagnosis and treatment such as can be carried out by the general practitioner. The teachings of the author are in accordance with his belief that true conservatism is to be found in the middle course between the surgeon who operates too frequently and the orthopedist who seldom operates.

"A very demonstrative work, every illustration of which conveys a lesson. The work is a most excellent and commendable one, which we can certainly endorse with pleasure."—*St. Louis Medical and Surgical Journal.*

ELEMENTARY BANDAGING AND SURGICAL DRESSING. With Directions concerning the Immediate Treatment of Cases of Emergency. For the use of Dressers and Nurses. By WALTER PYE, F.R.C.S., late Surgeon to St. Mary's Hospital, London. Small 12mo, with over 80 illustrations. Cloth, flexible covers, 75 cents net.

This little book is chiefly a condensation of those portions of Pye's "Surgical Handicraft" which deal with bandaging, splinting, etc., and of those which treat of the management in the first instance of cases of emergency. The directions given are thoroughly practical, and the book will prove extremely useful to students, surgical nurses, and dressers.

"The author writes well, the diagrams are clear, and the book itself is small and portable, although the paper and type are good."—*British Medical Journal.*

A TEXT-BOOK OF MATERIA MEDICA, THERAPEUTICS AND PHARMACOLOGY. By GEORGE F. BUTLER, PH.G., M.D., Professor of Materia Medica and of Clinical Medicine in the College of Physicians and Surgeons, Chicago; Professor of Materia Medica and Therapeutics, Northwestern University, Woman's Medical School, etc. Octavo, 874 pages, illustrated. Cloth, $4.00 net; Sheep, $5.00 net.

Third Edition, Thoroughly Revised.

A clear, concise, and practical text-book, adapted for permanent reference no less than for the requirements of the class-room.

The recent important additions made to our knowledge of the physiological action of drugs are fully discussed in the present edition. The book has been thoroughly revised and many additions have been made.

"Taken as a whole, the book may fairly be considered as one of the most satisfactory of any single-volume works on materia medica in the market."—*Journal of the American Medical Association.*

TUBERCULOSIS OF THE GENITO-URINARY ORGANS, MALE AND FEMALE. By NICHOLAS SENN, M.D., PH.D., LL.D., Professor of the Practice of Surgery and of Clinical Surgery, Rush Medical College, Chicago. Handsome octavo volume of 320 pages, illustrated. Cloth, $3.00 net.

Tuberculosis of the male and female genito-urinary organs is such a frequent, distressing, and fatal affection that a special treatise on the subject appears to fill a gap in medical literature. In the present work the bacteriology of the subject has received due attention, the modern resources employed in the differential diagnosis between tubercular and other inflammatory affections are fully described, and the medical and surgical therapeutics are discussed in detail.

"An important book upon an important subject, and written by a man of mature judgment and wide experience. The author has given us an instructive book upon one of the most important subjects of the day."—*Clinical Reporter.*

"A work which adds another to the many obligations the profession owes the talented author."—*Chicago Medical Recorder.*

A TEXT-BOOK OF DISEASES OF WOMEN. By CHARLES B. PENROSE, M.D., PH.D., Professor of Gynecology in the University of Pennsylvania; Surgeon to the Gynecean Hospital, Philadelphia. Octavo volume of 531 pages, with 217 illustrations, nearly all from drawings made for this work. Cloth, $3.75 net.

Third Edition, Revised.

In this work, which has been written for both the student of gynecology and the general practitioner, the author presents the best teaching of modern gynecology untrammelled by antiquated theories or methods of treatment. In most instances but one plan of treatment is recommended, to avoid confusing the student or the physician who consults the book for practical guidance.

"I shall value very highly the copy of Penrose's 'Diseases of Women' received. I have already recommended it to my class as THE BEST book."—HOWARD A. KELLY, *Professor of Gynecology and Obstetrics, Johns Hopkins University, Baltimore, Md.*

"The book is to be commended without reserve, not only to the student but to the general practitioner who wishes to have the latest and best modes of treatment explained with absolute clearness."—*Therapeutic Gazette.*

SURGICAL PATHOLOGY AND THERAPEUTICS. By JOHN COLLINS WARREN, M. D., LL.D., Professor of Surgery, Medical Department Harvard University. Handsome octavo, 832 pages, with 136 relief and lithographic illustrations, 33 of which are printed in colors.

Second Edition,

with an Appendix devoted to the Scientific Aids to Surgical Diagnosis, and a series of articles on Regional Bacteriology. Cloth, $5.00 net; Half-Morocco, $6.00 net.

Without Exception, the Illustrations are the Best ever Seen in a Work of this Kind.

"A most striking and very excellent feature of this book is its illustrations. Without exception, from the point of accuracy and artistic merit, they are the best ever seen in a work of this kind. * * * Many of those representing microscopic pictures are so perfect in their coloring and detail as almost to give the beholder the impression that he is looking down the barrel of a microscope at a well-mounted section."—*Annals of Surgery*, Philadelphia.

"It is the handsomest specimen of book-making * * * that has ever been issued from the American medical press."—*American Journal of the Medical Sciences*, Philadelphia.

PATHOLOGY AND SURGICAL TREATMENT OF TUMORS. By N. SENN, M. D., Ph. D., LL. D., Professor of Practice of Surgery and of Clinical Surgery, Rush Medical College; Professor of Surgery, Chicago Polyclinic; Attending Surgeon to Presbyterian Hospital; Surgeon-in-Chief, St. Joseph's Hospital, Chicago. One volume of 710 pages, with 515 engravings, including full-page colored plates. New and enlarged Edition in Preparation.

Books specially devoted to this subject are few, and in our text-books and systems of surgery this part of surgical pathology is usually condensed to a degree incompatible with its scientific and clinical importance. The author spent many years in collecting the material for this work, and has taken great pains to present it in a manner that should prove useful as a text-book for the student, a work of reference for the practitioner, and a reliable guide for the surgeon.

"The most exhaustive of any recent book in English on this subject. It is well illustrated, and will doubtless remain as the principal monograph on the subject in our language for some years. The book is handsomely illustrated and printed, ... and the author has given a notable and lasting contribution to surgery."—*Journal of the American Medical Association*, Chicago.

LECTURES ON RENAL AND URINARY DISEASES. By ROBERT SAUNDBY, M. D., Edin., Fellow of the Royal College of Physicians, London, and of the Royal Medico-Chirurgical Society; Physician to the General Hospital. Octavo volume of 434 pages, with numerous illustrations and 4 colored plates. Cloth, $2.50 net.

"The volume makes a favorable impression at once. The style is clear and succinct. We cannot find any part of the subject in which the views expressed are not carefully thought out and fortified by evidence drawn from the most recent sources. The book may be cordially recommended."—*British Medical Journal.*

A HANDBOOK FOR NURSES. By J. K. WATSON, M. D., Edin., Assistant House-Surgeon, Sheffield Royal Hospital. American Edition, under the supervision of A. A. STEVENS, A. M., M. D., Professor of Pathology, Woman's Medical College, Philadelphia. 12mo, 413 pages, 73 illustrations. Cloth, $1.50 net.

This work aims to supply in one volume that information which so many nurses at the present time are trying to extract from various medical works, and to present that information in a suitable form. Nurses must necessarily acquire a certain amount of medical knowledge, and the author of this book has aimed judiciously to cater to this need with the object of directing the nurses' pursuit of medical information in proper and legitimate channels. The book represents an entirely new departure in nursing literature, insomuch as it contains useful information on medical and surgical matters hitherto only to be obtained from expensive works written expressly for medical men.

A NEW PRONOUNCING DICTIONARY OF MEDICINE, with Phonetic Pronunciation, Accentuation, Etymology, etc. By JOHN M. KEATING, M. D., LL.D., Fellow of the College of Physicians of Philadelphia; Editor "Cyclopædia of the Diseases of Children," etc.; and HENRY HAMILTON, with the Collaboration of J. CHALMERS DACOSTA, M. D., and FREDERICK A. PACKARD, M. D. One very attractive volume of over 800 pages. Second Revised Edition. Prices: Cloth, $5.00 net; Sheep or Half-Morocco, $6.00 net; with Denison's Patent Ready-Reference Index; without patent index, Cloth, $4.00 net; Sheep or Half-Morocco, $5.00 net.

PROFESSIONAL OPINIONS.

"I am much pleased with Keating's Dictionary, and shall take pleasure in recommending it to my classes."

HENRY M. LYMAN, M. D.,
Professor of Principles and Practice of Medicine, Rush Medical College, Chicago, Ill.

"I am convinced that it will be a very valuable adjunct to my study-table, convenient in size and sufficiently full for ordinary use."

C. A. LINDSLEY, M. D.,
Professor of Theory and Practice of Medicine, Medical Dept. Yale University: Secretary Connecticut State Board of Health, New Haven, Conn.

AUTOBIOGRAPHY OF SAMUEL D. GROSS, M. D., Emeritus Professor of Surgery in the Jefferson Medical College of Philadelphia, with Reminiscences of His Times and Contemporaries. Edited by his sons, SAMUEL W. GROSS, M. D., LL.D., and A. HALLER GROSS, A. M., of the Philadelphia Bar. Preceded by a Memoir of Dr. Gross, by the late Austin Flint, M. D., LL.D. In two handsome volumes, each containing over 400 pages, demy 8vo, extra cloth, gilt tops, with fine Frontispiece engraved on steel. Price per Volume, $2.50 net.

PRACTICAL POINTS IN NURSING. For Nurses in Private Practice. By EMILY A. M. STONEY, Graduate of the Training-School for Nurses, Lawrence, Mass.; Superintendent of the Training-School for Nurses, Carney Hospital, South Boston, Mass. 456 pages, handsomely illustrated with 73 engravings in the text, and 9 colored and half-tone plates. Cloth. Price, $1.75 net.

SECOND EDITION, THOROUGHLY REVISED.

In this volume the author explains, in popular language and in the shortest possible form, the entire range of *private* nursing as distinguished from *hospital* nursing, and the nurse is instructed how best to meet the various emergencies of medical and surgical cases when distant from medical or surgical aid or when thrown on her own resources.

An especially valuable feature of the work will be found in the directions to the nurse how to *improvise* everything ordinarily needed in the sick-room, where the embarrassment of the nurse, owing to the want of proper appliances, is frequently extreme.

The work has been logically divided into the following sections:

I. The Nurse: her responsibilities, qualifications, equipment, etc.
II. The Sick-Room: its selection, preparation, and management.
III. The Patient: duties of the nurse in medical, surgical, obstetric, and gynecologic cases.
IV. Nursing in Accidents and Emergencies.
V. Nursing in Special Medical Cases.
VI. Nursing of the New-born and Sick Children.
VII. Physiology and Descriptive Anatomy.

The APPENDIX contains much information in compact form that will be found of great value to the nurse, including Rules for Feeding the Sick; Recipes for Invalid Foods and Beverages; Tables of Weights and Measures; Table for Computing the Date of Labor; List of Abbreviations; Dose-List; and a full and complete Glossary of Medical Terms and Nursing Treatment.

"This is a well-written, eminently practical volume, which covers the entire range of private nursing as distinguished from hospital nursing, and instructs the nurse how best to meet the various emergencies which may arise and how to prepare everything ordinarily needed in the illness of her patient."—*American Journal of Obstetrics and Diseases of Women and Children*, Aug., 1896.

A TEXT-BOOK OF BACTERIOLOGY, including the Etiology and Prevention of Infective Diseases and an account of Yeasts and Moulds, Hæmatozoa, and Psorosperms. By EDGAR M. CROOKSHANK, M. B., Professor of Comparative Pathology and Bacteriology, King's College, London. A handsome octavo volume of 700 pages, with 273 engravings in the text, and 22 original and colored plates. Price, $6.50 net.

This book, though nominally a Fourth Edition of Professor Crookshank's "MANUAL OF BACTERIOLOGY," is practically a new work, the old one having been reconstructed, greatly enlarged, revised throughout, and largely rewritten, forming a text-book for the Bacteriological Laboratory, for Medical Officers of Health, and for Veterinary Inspectors.

MEDICAL DIAGNOSIS. By Dr. OSWALD VIERORDT, Professor of Medicine at the University of Heidelberg. Translated, with additions, from the Fifth Enlarged German Edition, with the author's permission, by FRANCIS H. STUART, A. M., M. D. In one handsome royal-octavo volume of 600 pages. 194 fine wood-cuts in the text, many of them in colors. Prices: Cloth, $4.00 net; Sheep or Half-Morocco, $5.00 net.

FOURTH AMERICAN EDITION, FROM THE FIFTH REVISED AND ENLARGED GERMAN EDITION.

In this work, as in no other hitherto published, are given full and accurate explanations of the phenomena observed at the bedside. It is distinctly a clinical work by a master teacher, characterized by thoroughness, fulness, and accuracy. It is a mine of information upon the points that are so often passed over without explanation. Especial attention has been given to the germ-theory as a factor in the origin of disease.

The present edition of this highly successful work has been translated from the fifth German edition. Many alterations have been made throughout the book, but especially in the sections on Gastric Digestion and the Nervous System.

It will be found that all the qualities which served to make the earlier editions so acceptable have been developed with the evolution of the work to its present form.

THE PICTORIAL ATLAS OF SKIN DISEASES AND SYPHILITIC AFFECTIONS. (American Edition.) Translation from the French. Edited by J. J. PRINGLE, M. B., F. R. C. P., Assistant Physician to, and Physician to the department for Diseases of the Skin at, the Middlesex Hospital, London. Photo-lithochromes from the famous models of dermatological and syphilitic cases in the Museum of the Saint-Louis Hospital, Paris, with explanatory wood-cuts and letter-press. In 12 Parts, at $3.00 per Part.

"Of all the atlases of skin diseases which have been published in recent years, the present one promises to be of greatest interest and value, especially from the standpoint of the general practitioner."—*American Medico-Surgical Bulletin*, Feb. 22, 1896.

"The introduction of explanatory wood-cuts in the text is a novel and most important feature which greatly furthers the easier understanding of the excellent plates, than which nothing, we venture to say, has been seen better in point of correctness, beauty, and general merit."—*New York Medical Journal*, Feb. 15, 1896.

"An interesting feature of the Atlas is the descriptive text, which is written for each picture by the physician who treated the case or at whose instigation the models have been made. We predict for this truly beautiful work a large circulation in all parts of the medical world where the names *St. Louis* and *Baretta* have preceded it."—*Medical Record*, N. Y., Feb. 1, 1896.

A TEXT-BOOK OF MECHANO-THERAPY (MASSAGE AND MEDICAL GYMNASTICS). By AXEL V. GRAFSTROM, B. Sc., M. D., late Lieutenant in the Royal Swedish Army; late House Physician, City Hospital, Blackwell's Island, New York. 12mo, 139 pages, illustrated. Cloth, $1.00 net.

DISEASES OF THE EYE. A Hand-Book of Ophthalmic Practice. By G. E. DE SCHWEINITZ, M. D., Professor of Ophthalmology in the Jefferson Medical College, Philadelphia, etc. A handsome royal-octavo volume of 696 pages, with 255 fine illustrations, many of which are original, and 2 chromo-lithographic plates. Prices: Cloth, $4.00 net; Sheep or Half-Morocco, $5.00 net.

THIRD EDITION, THOROUGHLY REVISED.

In the third edition of this text-book, destined, it is hoped, to meet the favorable reception which has been accorded to its predecessors, the work has been revised thoroughly, and much new matter has been introduced. Particular attention has been given to the important relations which micro-organisms bear to many ocular diseases. A number of special paragraphs on new subjects have been introduced, and certain articles, including a portion of the chapter on Operations, have been largely rewritten, or at least materially changed. A number of new illustrations have been added. The Appendix contains a full description of the method of determining the corneal astigmatism with the ophthalmometer of Javal and Schiötz, and the rotation of the eyes with the tropometer of Stevens.

"A work that will meet the requirements not only of the specialist, but of the general practitioner in a rare degree. I am satisfied that unusual success awaits it."

WILLIAM PEPPER, M. D.

Provost and Professor of Theory and Practice of Medicine and Clinical Medicine in the University of Pennsylvania.

"A clearly written, comprehensive manual. . . . One which we can commend to students as a reliable text-book, written with an evident knowledge of the wants of those entering upon the study of this special branch of medical science."—*British Medical Journal.*

"It is hardly too much to say that for the student and practitioner beginning the study of Ophthalmology, it is the best single volume at present published."—*Medical News.*

"It is a very useful, satisfactory, and safe guide for the student and the practitioner, and one of the best works of this scope in the English language."—*Annals of Ophthalmology.*

DISEASES OF WOMEN. By J. BLAND SUTTON, F. R. C. S., Assistant Surgeon to Middlesex Hospital, and Surgeon to Chelsea Hospital, London; and ARTHUR E. GILES, M. D., B. Sc., Lond., F. R. C. S., Edin., Assistant Surgeon to Chelsea Hospital, London. 436 pages, handsomely illustrated. Cloth, $2.50 net.

The authors have placed in the hands of the physician and student a concise yet comprehensive guide to the study of gynecology in its most modern development. It has been their aim to relate facts and describe methods belonging to the science and art of gynecology in a way that will prove useful to students for examination purposes, and which will also enable the general physician to practice this important department of surgery with advantage to his patients and with satisfaction to himself.

"The book is very well prepared, and is certain to be well received by the medical public."—*British Medical Journal.*

"The text has been carefully prepared. Nothing essential has been omitted, and its teachings are those recommended by the leading authorities of the day."—*Journal of the American Medical Association.*

TEXT-BOOK UPON THE PATHOGENIC BACTERIA. Specially written for Students of Medicine. By JOSEPH MCFARLAND, M. D., Professor of Pathology and Bacteriology in the Medico-Chirurgical College of Philadelphia, etc. 497 pages, finely illustrated. **Price, Cloth, $2.50 net.**

SECOND EDITION, REVISED AND GREATLY ENLARGED.

The work is intended to be a text-book for the medical student and for the practitioner who has had no recent laboratory training in this department of medical science. The instructions given as to needed apparatus, cultures, stainings, microscopic examinations, etc. are ample for the student's needs, and will afford to the physician much information that will interest and profit him relative to a subject which modern science shows to go far in explaining the etiology of many diseased conditions.

In this second edition the work has been brought up to date in all departments of the subject, and numerous additions have been made to the technique in the endeavor to make the book fulfil the double purpose of a systematic work upon bacteria and a laboratory guide.

"It is excellently adapted for the medical students and practitioners for whom it is avowedly written. . . . The descriptions given are accurate and readable, and the book should prove useful to those for whom it is written.—*London Lancet*, Aug. 29, 1896.

"The author has succeded admirably in presenting the essential details of bacteriological technics, together with a judiciously chosen summary of our present knowledge of pathogenic bacteria. . . . The work, we think, should have a wide circulation among English-speaking students of medicine."—*N. Y. Medical Journal*, April 4, 1896.

"The book will be found of considerable use by medical men who have not had a special bacteriological training, and who desire to understand this important branch of medical science."—*Edinburgh Medical Journal*, July, 1896.

LABORATORY GUIDE FOR THE BACTERIOLOGIST. By LANGDON FROTHINGHAM, M. D. V., Assistant in Bacteriology and Veterinary Science, Sheffield Scientific School, Yale University. Illustrated. Price, Cloth, 75 cents.

The technical methods involved in bacteria-culture, methods of staining, and microscopical study are fully described and arranged as simply and concisely as possible. The book is especially intended for use in laboratory work.

"It is a convenient and useful little work, and will more than repay the outlay necessary for its purchase in the saving of time which would otherwise be consumed in looking up the various points of technique so clearly and concisely laid down in its pages."—*American Med.-Surg. Bulletin.*

FEEDING IN EARLY INFANCY. By ARTHUR V. MEIGS, M. D. Bound in limp cloth, flush edges. Price, 25 cents net.

SYNOPSIS: Analyses of Milk—Importance of the Subject of Feeding in Early Infancy—Proportion of Casein and Sugar in Human Milk—Time to Begin Artificial Feeding of Infants—Amount of Food to be Administered at Each Feeding—Intervals between Feedings—Increase in Amount of Food at Different Periods of Infant Development—Unsuitableness of Condensed Milk as a Substitute for Mother's Milk—Objections to Sterilization or "Pasteurization" of Milk—Advances made in the Method of Artificial Feeding of Infants.

MATERIA MEDICA FOR NURSES. By EMILY A. M. STONEY, Graduate of the Training-school for Nurses, Lawrence, Mass.; late Superintendent of the Training-school for Nurses, Carney Hospital, South Boston, Mass. Handsome octavo, 300 pages. Cloth, $1.50 net.

The present book differs from other similar works in several features, all of which are introduced to render it more practical and generally useful. The general plan of contents follows the lines laid down in training-schools for nurses, but the book contains much useful matter not usually included in works of this character, such as Poison-emergencies, Ready Dose-list, Weights and Measures, etc., as well as a Glossary, defining all the terms in Materia Medica, and describing all the latest drugs and remedies, which have been generally neglected by other books of the kind.

ESSENTIALS OF ANATOMY AND MANUAL OF PRACTICAL DISSECTION, containing "Hints on Dissection." By CHARLES B. NANCREDE, M. D., Professor of Surgery and Clinical Surgery in the University of Michigan, Ann Arbor; Corresponding Member of the Royal Academy of Medicine, Rome, Italy; late Surgeon Jefferson Medical College, etc. Fourth and revised edition. Post 8vo, over 500 pages, with handsome full-page lithographic plates in colors, and over 200 illustrations. Price: Extra Cloth or Oilcloth for the dissection-room, $2.00 net.

Neither pains nor expense has been spared to make this work the most exhaustive yet concise Student's Manual of Anatomy and Dissection ever published, either in America or in Europe.

The colored plates are designed to aid the student in dissecting the muscles, arteries, veins, and nerves. The wood-cuts have all been specially drawn and engraved, and an Appendix added containing 60 illustrations representing the structure of the entire human skeleton, the whole being based on the eleventh edition of Gray's *Anatomy*.

A MANUAL OF PRACTICE OF MEDICINE. By A. A. STEVENS, A. M., M. D., Instructor in Physical Diagnosis in the University of Pennsylvania, and Professor of Pathology in the Woman's Medical College of Pennsylvania. Specially intended for students preparing for graduation and hospital examinations. Post 8vo, 519 pages. Numerous illustrations and selected formulæ. Price, bound in flexible leather, $2.00 net.

FIFTH EDITION, REVISED AND ENLARGED.

Contributions to the science of medicine have poured in so rapidly during the last quarter of a century that it is well-nigh impossible for the student, with the limited time at his disposal, to master elaborate treatises or to cull from them that knowledge which is absolutely essential. From an extended experience in teaching, the author has been enabled, by classification, to group allied symptoms, and by the judicious elimination of theories and redundant explanations to bring within a comparatively small compass a complete outline of the practice of medicine.

MANUAL OF MATERIA MEDICA AND THERAPEUTICS. By A. A. STEVENS, A. M., M. D., Instructor of Physical Diagnosis in the University of Pennsylvania, and Professor of Pathology in the Woman's Medical College of Pennsylvania. 445 pages. Price, bound in flexible leather, $2.25.

SECOND EDITION, REVISED.

This wholly new volume, which is based on the last edition of the *Pharmacopœia*, comprehends the following sections: Physiological Action of Drugs; Drugs; Remedial Measures other than Drugs; Applied Therapeutics; Incompatibility in Prescriptions; Table of Doses; Index of Drugs; and Index of Diseases; the treatment being elucidated by more than two hundred formulæ.

"The author is to be congratulated upon having presented the medical student with as accurate a manual of therapeutics as it is possible to prepare."—*Therapeutic Gazette.*

"Far superior to most of its class; in fact, it is very good. Moreover, the book is reliable and accurate."—*New York Medical Journal.*

"The author has faithfully presented modern therapeutics in a comprehensive work, . . . and it will be found a reliable guide."—*University Medical Magazine.*

NOTES ON THE NEWER REMEDIES: their Therapeutic Applications and Modes of Administration. By DAVID CERNA, M. D., PH. D., Demonstrator of and Lecturer on Experimental Therapeutics in the University of Pennsylvania. Post-octavo, 253 pages. Price, $1.25.

SECOND EDITION, RE-WRITTEN AND GREATLY ENLARGED.

The work takes up in alphabetical order all the newer remedies, giving their physical properties, solubility, therapeutic applications, administration, and chemical formula.

It thus forms a very valuable addition to the various works on therapeutics now in existence.

Chemists are so multiplying compounds, that, if each compound is to be thoroughly studied, investigations must be carried far enough to determine the practical importance of the new agents.

"Especially valuable because of its completeness, its accuracy, its systematic consideration of the properties and therapy of many remedies of which doctors generally know but little, expressed in a brief yet terse manner."—*Chicago Clinical Review.*

TEMPERATURE CHART. Prepared by D. T. LAINÉ, M. D. Size 8×13½ inches. Price, per pad of 25 charts, 50 cents.

A conveniently arranged chart for recording Temperature, with columns for daily amounts of Urinary and Fecal Excretions, Food, Remarks, etc. On the back of each chart is given in full the method of Brand in the treatment of Typhoid Fever.

A TEXT-BOOK OF HISTOLOGY, DESCRIPTIVE AND PRACTICAL. For the Use of Students. By ARTHUR CLARKSON, M. B., C. M., Edin., formerly Demonstrator of Physiology in the Owen's College, Manchester; late Demonstrator of Physiology in the Yorkshire College, Leeds. Large 8vo, 554 pages, with 22 engravings in the text, and 174 beautifully colored original illustrations. Price, strongly bound in Cloth, $4.00 net.

The purpose of the writer in this work has been to furnish the student of Histology, in one volume, with both the descriptive and the practical part of the science. The first two chapters are devoted to the consideration of the general methods of Histology; subsequently, in each chapter, the structure of the tissue or organ is first systematically described, the student is then taken tutorially over the specimens illustrating it, and, finally, an appendix affords a short note of the methods of preparation.

"The work must be considered a valuable addition to the list of available text-books, and is to be highly recommended."—*New York Medical Journal.*

"One of the best works for students we have ever noticed. We predict that the book will attain a well-deserved popularity among our students."—*Chicago Medical Recorder.*

THE PATHOLOGY AND TREATMENT OF SEXUAL IMPOTENCE. By VICTOR G. VECKI, M. D. From the second German edition, revised and rewritten. Demi-octavo, about 300 pages. Cloth, $2.00 net.

The subject of impotence has but seldom been treated in this country in the truly scientific spirit that it deserves, and this volume will come to many as a revelation of the possibilities of therapeusis in this important field. Dr. Vecki's work has long been favorably known, and the German book has received the highest consideration. This edition is more than a mere translation, for, although based on the German edition, it has been entirely rewritten by the author in English.

"The work can be recommended as a scholarly treatise on its subject, and it can be read with advantage by many practitioners."—*Journal of the American Medical Association.*

THE TREATMENT OF PELVIC INFLAMMATIONS THROUGH THE VAGINA. By W. R. PRYOR, M. D., Professor of Gynecology in the New York Polyclinic. 12mo, 248 pages, handsomely illustrated. Cloth, $2.00 net.

In this book the author directs the attention of the general practitioner to a surgical treatment of the pelvic diseases of women. There exists the utmost confusion in the profession regarding the most successful methods of treating pelvic inflammations; and inasmuch as inflammatory lesions constitute the majority of all pelvic diseases, the subject is an important one. It has been the endeavor of the author to put down every little detail, no matter how insignificant, which might be of service.

DISEASES OF WOMEN. By HENRY J. GARRIGUES, A. M., M. D., Professor of Gynecology in the New York School of Clinical Medicine; Gynecologist to St. Mark's Hospital and to the German Dispensary, New York City. In one handsome octavo volume of 728 pages, illustrated by 335 engravings and colored plates. Prices: Cloth, $4.00 net; Sheep or Half-Morocco, $5.00 net.

A PRACTICAL work on gynecology for the use of students and practitioners, written in a terse and concise manner. The importance of a thorough knowledge of the anatomy of the female pelvic organs has been fully recognized by the author, and considerable space has been devoted to the subject. The chapters on Operations and on Treatment are thoroughly modern, and are based upon the large hospital and private practice of the author. The text is elucidated by a large number of illustrations and colored plates, many of them being original, and forming a complete atlas for studying *embryology* and the *anatomy* of the *female genitalia*, besides exemplifying, whenever needed, morbid conditions, instruments, apparatus, and operations.

Second Edition, Thoroughly Revised.

The first edition of this work met with a most appreciative reception by the medical press and profession both in this country and abroad, and was adopted as a text-book or recommended as a book of reference by nearly *one hundred* colleges in the United States and Canada. The author has availed himself of the opportunity afforded by this revision to embody the latest approved advances in the treatment employed in this important branch of Medicine. He has also more extensively expressed his own opinion on the comparative value of the different methods of treatment employed.

"One of the best text-books for students and practitioners which has been published in the English language; it is condensed, clear, and comprehensive. The profound learning and great clinical experience of the distinguished author find expression in this book in a most attractive and instructive form. Young practitioners, to whom experienced consultants may not be available, will find in this book invaluable counsel and help."

THAD. A. REAMY, M. D., LL.D.,
Professor of Clinical Gynecology, Medical College of Ohio; Gynecologist to the Good Samaritan and Cincinnati Hospitals.

A SYLLABUS OF GYNECOLOGY, arranged in conformity with "An American Text-Book of Gynecology." By J. W. LONG, M. D., Professor of Diseases of Women and Children, Medical College of Virginia, etc. Price, Cloth (interleaved), $1.00 net.

Based upon the teaching and methods laid down in the larger work, this will not only be useful as a supplementary volume, but to those who do not already possess the text-book it will also have an independent value as an aid to the practitioner in gynecological work, and to the student as a guide in the lecture-room, as the subject is presented in a manner at once systematic, clear, succinct, and practical.

THE AMERICAN POCKET MEDICAL DICTIONARY. Edited by W. A. NEWMAN DORLAND, M. D., Assistant Obstetrician to the Hospital of the University of Pennsylvania; Fellow of the American Academy of Medicine. Containing the pronunciation and definition of all the principal words used in medicine and the kindred sciences, with 64 extensive tables. Handsomely bound in flexible leather, limp, with gold edges and patent thumb index. Price, $1.00 net; with thumb index, $1.25 net.

SECOND EDITION, REVISED.

This is the ideal pocket lexicon. It is an absolutely new book, and not a revision of any old work. It is complete, defining all the terms of modern medicine and forming an unusually complete vocabulary. It gives the pronunciation of all the terms. It makes a special feature of the newer words neglected by other dictionaries. It contains a wealth of anatomical tables of special value to students. It forms a handy volume, indispensable to every medical man.

SAUNDERS' POCKET MEDICAL FORMULARY. By WILLIAM M. POWELL, M. D., Attending Physician to the Mercer House for Invalid Women at Atlantic City. Containing 1800 Formulæ, selected from several hundred of the best-known authorities. Forming a handsome and convenient pocket companion of nearly 300 printed pages, with blank leaves for Additions; with an Appendix containing Posological Table, Formulæ and Doses for Hypodermatic Medication, Poisons and their Antidotes, Diameters of the Pemale Pelvis and Fœtal Head, Obstetrical Table, Diet List for Various Diseases, Materials and Drugs used in Antiseptic Surgery, Treatment of Asphyxia from Drowning, Surgical Remembrancer, Tables of Incompatibles, Eruptive Fevers, Weights and Measures, etc. Handsomely bound in morocco, with side index, wallet, and flap. Price, $1.75 net.

FIFTH EDITION, THOROUGHLY REVISED.

"This little book, that can be conveniently carried in the pocket, contains an immense amount of material. It is very useful, and as the name of the author of each prescription is given, is unusually reliable."—*New York Medical Record.*

A COMPENDIUM OF INSANITY. By JOHN B. CHAPIN, M.D., LL.D., Physician-in-Chief, Pennsylvania Hospital for the Insane; late Physician-Superintendent of the Willard State Hospital, New York; Honorary Member of the Medico-Psychological Society of Great Britain, of the Society of Mental Medicine of Belgium. 12mo, 234 pages, illust. Cloth, $1.25 net.

The author has given, in a condensed and concise form, a compendium of Diseases of the Mind, for the convenient use and aid of physicians and students. It contains a clear, concise statement of the clinical aspects of the various abnormal mental conditions, with directions as to the most approved methods of managing and treating the insane.

"The practical parts of Dr. Chapin's book are what constitute its distinctive merit. We desire especially, however, to call attention to the fact that in the subject of the therapeutics of insanity the work is exceedingly valuable. The author has made a distinct addition to the literature of his specialty."—*Philadelphia Medical Journal.*

AN OPERATION BLANK, with Lists of Instruments, etc. required in Various Operations. Prepared by W. W. KEEN, M. D., LL.D., Professor of Principles of Surgery in the Jefferson Medical College, Philadelphia. Price per Pad, containing Blanks for fifty operations, 50 cents net.

SECOND EDITION, REVISED FORM.

A convenient blank, suitable for all operations, giving complete instructions regarding necessary preparation of patient, etc., with a full list of dressings and medicines to be employed.

On the back of each blank is a list of instruments used—viz. general instruments, etc., required for all operations; and special instruments for surgery of the brain and spine, mouth and throat, abdomen, rectum, male and female genito-urinary organs, the bones, etc.

The whole forming a neat pad, arranged for hanging on the wall of a surgeon's office or in the hospital operating-room.

"Will serve a useful purpose for the surgeon in reminding him of the details of preparation for the patient and the room as well as for the instruments, dressings, and antiseptics needed."—*New York Medical Record*

"Covers about all that can be needed in any operation."—*American Lancet.*

"The plan is a capital one."—*Boston Medical and Surgical Journal.*

LABORATORY EXERCISES IN BOTANY. By EDSON S. BASTIN, M. A., Professor of Materia Medica and Botany in the Philadelphia College of Pharmacy. Octavo volume of 536 pages, 87 full-page plates. Price, Cloth, $2.50.

This work is intended for the beginner and the advanced student, and it fully covers the structure of flowering plants, roots, ordinary stems, rhizomes, tubers, bulbs, leaves, flowers, fruits, and seeds. Particular attention is given to the gross and microscopical structure of plants, and to those used in medicine. Illustrations have freely been used to elucidate the text, and a complete index to facilitate reference has been added.

"There is no work like it in the pharmaceutical or botanical literature of this country, and we predict for it a wide circulation."—*American Journal of Pharmacy.*

DIET IN SICKNESS AND IN HEALTH. By MRS. ERNEST HART, formerly Student of the Faculty of Medicine of Paris and of the London School of Medicine for Women; with an INTRODUCTION by Sir Henry Thompson, F. R. C. S., M. D., London. 220 pages; illustrated. Price, Cloth, $1.50.

Useful to those who have to nurse, feed, and prescribe for the sick. In each case the accepted causation of the disease and the reasons for the special diet prescribed are briefly described. Medical men will find the dietaries and recipes practically useful, and likely to save them trouble in directing the dietetic treatment of patients.

A MANUAL OF PHYSIOLOGY, with Practical Exercises. For Students and Practitioners. By G. N. STEWART, M. A., M. D., D. Sc., lately Examiner in Physiology, University of Aberdeen, and of the New Museums, Cambridge University; Professor of Physiology in the Western Reserve University, Cleveland, Ohio. Handsome octavo volume of 848 pages, with 300 illustrations in the text, and 5 colored plates. Price, Cloth, $3.75 net.

THIRD EDITION, REVISED.

"It will make its way by sheer force of merit, and *amply deserves to do so. It is one of the very best English text-books on the subject.*"—*London Lancet.*

"Of the many text-books of physiology published, we do not know of one that so nearly comes up to the ideal as does Professor Stewart's volume."—*British Medical Journal.*

ESSENTIALS OF PHYSICAL DIAGNOSIS OF THE THORAX. By ARTHUR M. CORWIN, A. M., M. D., Demonstrator of Physical Diagnosis in the Rush Medical College, Chicago; Attending Physician to the Central Free Dispensary, Department of Rhinology, Laryngology, and Diseases of the Chest. 219 pages. Illustrated. Cloth, flexible covers. Price, $1.25 net.

THIRD EDITION, THOROUGHLY REVISED AND ENLARGED.

SYLLABUS OF OBSTETRICAL LECTURES in the Medical Department, University of Pennsylvania. By RICHARD C. NORRIS, A. M., M. D., Lecturer on Clinical and Operative Obstetrics, University of Pennsylvania. Third edition, thoroughly revised and enlarged. Crown 8vo. Price, Cloth, interleaved for notes, $2.00 net.

"This work is so far superior to others on the same subject that we take pleasure in calling attention briefly to its excellent features. It covers the subject thoroughly, and will prove invaluable both to the student and the practitioner. The author has introduced a number of valuable hints which would only occur to one who was himself an experienced teacher of obstetrics. The subject-matter is clear, forcible, and modern. We are especially pleased with the portion devoted to the practical duties of the accoucheur, care of the child, etc. The paragraphs on antiseptics are admirable; there is no doubtful tone in the directions given. No details are regarded as unimportant; no minor matters omitted. We venture to say that even the old practitioner will find useful hints in this direction which he cannot afford to despise."—*New York Medical Record.*

A SYLLABUS OF LECTURES ON THE PRACTICE OF SURGERY, arranged in conformity with "An American Text-Book of Surgery." By N. SENN, M. D., PH. D., Professor of Surgery in Rush Medical College, Chicago, and in the Chicago Polyclinic. Price, $2.00.

This work by so eminent an author, himself one of the contributors to "An American Text-Book of Surgery," will prove of exceptional value to the advanced student who has adopted that work as his text-book. It is not only the syllabus of an unrivalled course of surgical practice, but it is also an epitome of or supplement to the larger work.

"The author has evidently spared no pains in making his Syllabus thoroughly comprehensive, and has added new matter and alluded to the most recent authors and operations. Full references are also given to all requisite details of surgical anatomy and pathology."—*British Medical Journal*, London.

THE CARE OF THE BABY. By J. P. CROZER GRIFFITH, M. D., Clinical Professor of Diseases of Children, University of Pennsylvania; Physician to the Children's Hospital, Philadelphia, etc. 404 pages, with 67 illustrations in the text, and 5 plates. 12mo. Price, $1.50.

SECOND EDITION, REVISED.

A reliable guide not only for mothers, but also for medical students and practitioners whose opportunities for observing children have been limited.

"The whole book is characterized by rare good sense, and is evidently written by a master hand. It can be read with benefit not only by mothers, but by medical students and by any practitioners who have not had large opportunities for observing children."—*American Journal of Obstetrics.*

THE NURSE'S DICTIONARY of Medical Terms and Nursing Treatment, containing Definitions of the Principal Medical and Nursing Terms, Abbreviations, and Physiological Names, and Descriptions of the Instruments, Drugs, Diseases, Accidents, Treatments, Operations, Foods, Appliances, etc. encountered in the ward or the sick-room. By HONNOR MORTEN, author of "How to Become a Nurse," "Sketches of Hospital Life," etc. 16mo, 140 pages. Price, Cloth, $1.00.

This little volume is intended for use merely as a small reference-book which can be consulted at the bedside or in the ward. It gives sufficient explanation to the nurse to enable her to comprehend a case until she has leisure to look up larger and fuller works on the subject.

DIET LISTS AND SICK-ROOM DIETARY. By JEROME B. THOMAS, M. D., Visiting Physician to the Home for Friendless Women and Children and to the Newsboys' Home; Assistant Visiting Physician to the Kings County Hospital; Assistant Bacteriologist, Brooklyn Health Department. Price, Cloth, $1.50 (Send for specimen List.)

One hundred and sixty detachable (perforated) diet lists for Albuminuria, Anæmia and Debility, Constipation, Diabetes, Diarrhœa, Dyspepsia, Fevers, Gout or Uric-Acid Diathesis, Obesity, and Tuberculosis. Also forty detachable sheets of Sick-Room Dietary, containing full instructions for preparation of easily-digested foods necessary for invalids. Each list is *numbered only*, the disease for which it is to be used in no case being mentioned, an index key being reserved for the physician's private use.

DIETS FOR INFANTS AND CHILDREN IN HEALTH AND IN DISEASE. By LOUIS STARR, M. D., Editor of "An American Text-Book of the Diseases of Children." 230 blanks (pocket-book size), perforated and neatly bound in flexible morocco. Price, $1.25 net.

The first series of blanks are prepared for the first seven months of infant life; each blank indicates the ingredients, but not the *quantities*, of the food, the latter directions being left for the physician. After the seventh month, modifications being less necessary, the diet lists are printed in full. *Formula* for the preparation of diluents and foods are appended.

HOW TO EXAMINE FOR LIFE INSURANCE. By JOHN M. KEATING, M. D., Fellow of the College of Physicians and Surgeons of Philadelphia; Vice-President of the American Pædiatric Society; Ex-President of the Association of Life Insurance Medical Directors. Royal 8vo, 211 pages, with two large half-tone illustrations, and a plate prepared by Dr. McClellan from special dissections; also, numerous cuts to elucidate the text. Third edition. Price, Cloth, $2.00 net.

"This is by far the most useful book which has yet appeared on insurance examination, a subject of growing interest and importance. Not the least valuable portion of the volume is Part II., which consists of instructions issued to their examining physicians by twenty-four representative companies of this country. As the proofs of these instructions were corrected by the directors of the companies, they form the latest instructions obtainable. If for these alone, the book should be at the right hand of every physician interested in this special branch of medical science."—*The Medical News*, Philadelphia.

NURSING: ITS PRINCIPLES AND PRACTICE. By ISABEL ADAMS HAMPTON, Graduate of the New York Training School for Nurses attached to Bellevue Hospital; Superintendent of Nurses and Principal of the Training School for Nurses, Johns Hopkins Hospital, Baltimore, Md.; late Superintendent of Nurses, Illinois Training School for Nurses, Chicago, Ill. In one very handsome 12mo volume of 512 pages, illustrated. Price, Cloth, $2.00 net.

SECOND EDITION, REVISED AND ENLARGED.

This original work on the important subject of nursing is at once comprehensive and systematic. It is written in a clear, accurate, and readable style, suitable alike to the student and the lay reader. Such a work has long been a desideratum with those entrusted with the management of hospitals and the instruction of nurses in training-schools. It is also of especial value to the graduated nurse who desires to acquire a practical working knowledge of the care of the sick and the hygiene of the sick-room.

OBSTETRIC ACCIDENTS, EMERGENCIES, AND OPERATIONS. By L. CH. BOISLINIERE, M. D., late Emeritus Professor of Obstetrics in the St. Louis Medical College. 381 pages, handsomely illustrated. Price, $2.00 net.

"For the use of the practitioner who, when away from home, has not the opportunity of consulting a library or of calling a friend in consultation. He then, being thrown upon his own resources, will find this book of benefit in guiding and assisting him in emergencies."

INFANT'S WEIGHT CHART. Designed by J. P. CROZER GRIFFITH, M. D., Clinical Professor of Diseases of Children in the University of Pennsylvania. 25 charts in each pad. Price per pad, 50 cents net.

A convenient blank for keeping a record of the child's weight during the first two years of life. Printed on each chart is a curve representing the average weight of a healthy infant, so that any deviation from the normal can readily be detected.

SAUNDERS' NEW SERIES OF MANUALS

for Students and Practitioners.

THAT there exists a need for thoroughly reliable hand-books on the leading branches of Medicine and Surgery is a fact amply demonstrated by the favor with which the SAUNDERS NEW SERIES OF MANUALS have been received by medical students and practitioners and by the Medical Press. These manuals are not merely condensations from present literature, but are ably written by well-known authors and practitioners, most of them being teachers in representative American colleges. Each volume is concisely and authoritatively written and exhaustive in detail, without being encumbered with the introduction of "cases," which so largely expand the ordinary text-book. These manuals will therefore form an admirable collection of advanced lectures, useful alike to the medical student and the practitioner: to the latter, too busy to search through page after page of elaborate treatises for what he wants to know, they will prove of inestimable value; to the former they will afford safe guides to the essential points of study.

The SAUNDERS NEW SERIES OF MANUALS are conceded to be superior to any similar books now on the market. No other manuals afford so much information in such a concise and available form. A liberal expenditure has enabled the publisher to render the mechanical portion of the work worthy of the high literary standard attained by these books.

Any of these Manuals will be mailed on receipt of price (see next page *for List*).

SAUNDERS' NEW SERIES OF MANUALS.

VOLUMES PUBLISHED.

PHYSIOLOGY. By JOSEPH HOWARD RAYMOND, A. M., M. D., Professor of Physiology and Hygiene and Lecturer on Gynecology in the Long Island College Hospital, etc. Price, $1.25 net.

SURGERY, General and Operative. By JOHN CHALMERS DACOSTA, M. D., Professor of Clinical Surgery, Jefferson Medical College, Philadelphia. Second edition, revised and greatly enlarged. Octavo, 911 pages, 386 illustrations. Cloth, $4.00 net; Half-Morocco, $5.00 net.

DOSE-BOOK AND MANUAL OF PRESCRIPTION-WRITING. By E. Q. THORNTON, M. D., Demonstrator of Therapeutics, Jefferson Medical College, Philadelphia. Price, $1.25 net.

MEDICAL JURISPRUDENCE. By HENRY C. CHAPMAN, M. D., Professor of Institutes of Medicine and Medical Jurisprudence in the Jefferson Medical College of Philadelphia, etc. Price, $1.50 net.

SURGICAL ASEPSIS. By CARL BECK, M. D., Surgeon to St. Mark's Hospital and to the German Poliklinik; Instructor in Surgery, New York Post-Graduate Medical School, etc. Price, $1.25 net.

MANUAL OF ANATOMY. By IRVING S. HAYNES, M. D., Adjunct Professor of Anatomy and Demonstrator of Anatomy, Medical Department of the New York University, etc. Price, $2.50 net.

SYPHILIS AND THE VENEREAL DISEASES. By JAMES NEVINS HYDE, M. D., Professor of Skin and Venereal Diseases, and FRANK H. MONTGOMERY, M. D., Lecturer on Dermatology and Genito-urinary Diseases in Rush Medical College, Chicago. Price, $2.50 net.

PRACTICE OF MEDICINE. By GEORGE ROE LOCKWOOD, M. D., Professor of Practice in the Woman's Medical College of the New York Infirmary, etc. Price, $2.50 net.

OBSTETRICS. By W. A. NEWMAN DORLAND, M. D., Assistant Demonstrator of Obstetrics, University of Pennsylvania; Chief of Gynecological Dispensary, Pennsylvania Hospital. Price, $2.50 net.

DISEASES OF WOMEN. By J. BLAND SUTTON, F. R. C. S., Assistant Surgeon to the Middlesex Hospital, and Surgeon to the Chelsea Hospital for Women, London; and ARTHUR E. GILES, M. D., B. Sc. Lond., F. R. C. S. Edin., Assistant Surgeon to the Chelsea Hospital for Women, London. 436 pages, handsomely illustrated. Price, $2.50 net.

IN PREPARATION.

NERVOUS DISEASES. By CHARLES W. BURR, M. D., Clinical Professor of Nervous Diseases, Medico-Chirurgical College, Philadelphia, etc.

*** There will be published in the same series, at short intervals, carefully prepared works on various subjects, by prominent specialists.

SAUNDERS' QUESTION COMPENDS.

Arranged in Question and Answer Form.

THE LATEST, MOST COMPLETE, and BEST ILLUSTRATED SERIES OF COMPENDS EVER ISSUED.

Now the Standard Authorities in Medical Literature

WITH

Students and Practitioners in every City of the United States and Canada.

THE REASON WHY.

They are the advance guard of "Student's Helps"—that DO HELP; they are the leaders in their special line, *well and authoritatively written by able men, who, as teachers in the large colleges, know exactly what is wanted by a student preparing for his examinations.* The judgment exercised in the selection of authors is fully demonstrated by their professional elevation. Chosen from the ranks of Demonstrators, Quiz-masters, and Assistants, most of them have become Professors and Lecturers in their respective colleges.

Each book is of convenient size (5 × 7 inches), containing on an average 250 pages, profusely illustrated, and elegantly printed in clear, readable type, on fine paper.

The entire series, numbering twenty-four subjects, has been kept thoroughly revised and enlarged when necessary, many of them being in their fourth and fifth editions.

TO SUM UP.

Although there are numerous other Quizzes, Manuals, Aids, etc. in the market, none of them approach the "Blue Series of Question Compends;" and the claim is made for the following points of excellence:

1. Professional distinction and reputation of authors.
2. Conciseness, clearness, and soundness of treatment.
3. Size of type and quality of paper and binding.

***** Any of these Compends will be mailed on receipt of price (see next page for List).**

SAUNDERS' QUESTION-COMPEND SERIES.

Price, Cloth, $1.00 per copy, except when otherwise noted.

1. **ESSENTIALS OF PHYSIOLOGY.** 4th edition. Illustrated. Revised and enlarged. By H. A. HARE, M. D. (Price, $1.00 net.)

2. **ESSENTIALS OF SURGERY.** 7th edition, with a chapter on Appendicitis. 90 illustrations. By EDWARD MARTIN, M. D. (Price, $1.00 net.)

3. **ESSENTIALS OF ANATOMY.** 6th edition, thoroughly revised. 151 illustrations. By CHARLES B. NANCREDE, M. D. (Price, $1.00 net.)

4. **ESSENTIALS OF MEDICAL CHEMISTRY, ORGANIC AND INORGANIC.** 5th edition, revised, with an Appendix. By LAWRENCE WOLFF, M. D. ($1.00 net.)

5. **ESSENTIALS OF OBSTETRICS.** 4th edition, revised and enlarged. 75 illustrations. By W. EASTERLY ASHTON, M. D.

6. **ESSENTIALS OF PATHOLOGY AND MORBID ANATOMY.** 7th thousand. 46 illustrations. By C. E. ARMAND SEMPLE, M. D.

7. **ESSENTIALS OF MATERIA MEDICA, THERAPEUTICS, AND PRESCRIPTION-WRITING.** 5th edition. By HENRY MORRIS, M. D.

8, 9. **ESSENTIALS OF PRACTICE OF MEDICINE.** By HENRY MORRIS, M. D. An Appendix on URINE EXAMIN ATION. Illustrated. By LAWRENCE WOLFF, M. D. 3d edition, enlarged by some 300 Essential Formulæ, selected from eminent authorities, by WM. M. POWELL, M. D. (Double number, price $2.00.)

10. **ESSENTIALS OF GYNÆCOLOGY.** 4th edition, revised. With 62 illustrations. By EDWIN B. CRAGIN, M. D.

11. **ESSENTIALS OF DISEASES OF THE SKIN.** 4th edition. revised and enlarged. 71 letter-press cuts and 15 half-tone illustrations. By HENRY W. STELWAGON, M.D. (Price, $1.00 net.)

12. **ESSENTIALS OF MINOR SURGERY, BANDAGING, AND VENEREAL DISEASES.** 2d edition, revised and enlarged. 78 illustrations. By EDWARD MARTIN, M. D.

13. **ESSENTIALS OF LEGAL MEDICINE, TOXICOLOGY, AND HYGIENE.** 130 illustrations. By C. E. ARMAND SEMPLE, M. D.

14. **ESSENTIALS OF DISEASES OF THE EYE, NOSE, AND THROAT.** 124 illustrations. 2d edition, revised. By EDWARD JACKSON, M. D., and E. BALDWIN GLEASON, M. D.

15. **ESSENTIALS OF DISEASES OF CHILDREN.** 2d edition. By WILLIAM M. POWELL, M. D.

16. **ESSENTIALS OF EXAMINATION OF URINE.** Colored "VOGEL SCALE," and numerous illustrations. By LAWRENCE WOLFF, M. D. (Price, 75 cents.)

17. **ESSENTIALS OF DIAGNOSIS.** 2d edition, thoroughly revised. 60 illustrations. By S. SOLIS-COHEN, M. D., and A. A. ESHNER, M. D. (Price, $1.00 net.)

18. **ESSENTIALS OF PRACTICE OF PHARMACY.** 2d edition, revised. By L. E. SAYRE.

20. **ESSENTIALS OF BACTERIOLOGY.** 3d edition. 82 illustrations. By M. V. BALL, M. D.

21. **ESSENTIALS OF NERVOUS DISEASES AND INSANITY.** 48 illustrations. 3d edition, revised. By JOHN C. SHAW, M. D.

22. **ESSENTIALS OF MEDICAL PHYSICS.** 155 illustrations. 2d edition, revised. By FRED J. BROCKWAY, M. D. (Price, $1.00 net.)

23. **ESSENTIALS OF MEDICAL ELECTRICITY.** 65 illustrations. By DAVID D. STEWART, M. D., and EDWARD S. LAWRANCE, M. D.

24. **ESSENTIALS OF DISEASES OF THE EAR.** 114 illustrations. 2d edition, revised and enlarged. By E. BALDWIN GLEASON, M. D.

Some of the Books in Preparation for Publication during 1900.

AMERICAN Text-Book of Pathology.

Edited by LUDVIG HEKTOEN, M.D., Professor of Pathology, Rush Medical College, Chicago; and DAVID RIESMAN, M.D., Demonstrator of Pathological Histology, University of Pennsylvania.

AMERICAN Text-Book of Legal Medicine and Toxicology.

Edited by FREDERICK PETERSON, M.D., Chief of Clinic, Nervous Department, College of Physicians and Surgeons, New York City; and WALTER S. HAINES, M.D., Professor of Chemistry, Pharmacy, and Toxicology, Rush Medical College, Chicago.

BECK—Fractures.

By CARL BECK, M.D., Professor of Surgery in the N. Y. School of Clinical Medicine.

BÖHM, DAVIDOFF, and HUBER—A Text-Book of Human Histology.

Including Microscopic Technic. By DR. A. A. BOHM and DR. M. VON DAVIDOFF, of the Anatomical Institute of Munich, and G. C. HUBER, M.D., Junior Professor of Anatomy and Histology, University of Michigan, Ann Arbor.

EICHHORST—A Text-Book of the Practice of Medicine.

By DR. HERMAN EICHHORST, Professor of Special Pathology and Therapeutics and Director of the Medical Clinic, University of Zurich. Translated and edited by AUGUSTUS A. ESHNER, M.D., Professor of Clinical Medicine in the Philadelphia Polyclinic.

FRIEDRICH — Rhinology, Laryngology, and Otology in their Relations to General Medicine.

By DR. E. P. FRIEDRICH, of the University of Leipsig.

LEVY AND KLEMPERER — The Elements of Clinical Bacteriology.

By DR. ERNST LEVY, Professor in the University of Strassburg, and DR. FELIX KLEMPERER, Privat-Docent in the University of Strassburg. Translated and edited by AUGUSTUS A. ESHNER, M.D., Professor of Clinical Medicine in the Philadelphia Polyclinic. *Just Ready.* Cloth, $2 50 net.

McFARLAND—A Text-Book of Pathology.

By JOSEPH MCFARLAND, M.D., Professor of Pathology and Bacteriology, Medico-Chirurgical College, Philadelphia.

OGDEN — Clinical Examination of the Urine.

By J. BERGEN OGDEN, M.D., Assistant in Chemistry, Harvard Medical School.

PYLE—A Manual of Personal Hygiene.

Edited by WALTER L. PYLE, M.D., Assistant Surgeon to Wills' Eye Hospital, Philada.

SCUDDER—The Treatment of Fractures.

By CHARLES L. SCUDDER, M.D., Assistant in Clinical and Operative Surgery, Harvard University.

SENN—Practical Surgery.

By NICHOLAS SENN, M.D., PH.D., LL.D., Professor of the Practice of Surgery and of Clinical Surgery, Rush Medical College, Chicago. Octavo volume of about 800 pages, profusely illustrated.

The Pathology and Treatment of Tumors.

By NICHOLAS SENN, M.D., PH.D., LL.D., Professor of the Practice of Surgery and of Clinical Surgery, Rush Medical College, Chicago. A New and Thoroughly Revised Edition in preparation.

STENGEL AND WHITE — The Blood in its Clinical and Pathological Relations.

By ALFRED STENGEL, M.D., Professor of Clinical Medicine, University of Pennsylvania; and C. Y. WHITE, M.D., Instructor in Clinical Medicine, University of Pennsylvania.

STEVENS—The Physical Diagnosis of Diseases of the Chest.

By A. A. STEVENS, A.M., M.D., Lecturer on Terminology, and Instructor in Physical Diagnosis, University of Pennsylvania.

STONEY — Surgical Technique for Nurses.

By EMILY A. M. STONEY, late Superintendent of the Training Schools for Nurses, Carney Hospital, South Boston, Mass.

VOLUMES NOW READY.

Atlas of Internal Medicine and Clinical Diagnosis. By Dr. Chr. Jakob, of Erlangen. Edited by Augustus A. Eshner, M.D., Professor of Clinical Medicine in the Philadelphia Polyclinic; Attending Physician to the Philadelphia Hospital. 68 colored plates. Cloth, $3.00 net.

Atlas of Legal Medicine. By Dr. E. von Hofmann, o
Vienna. Edited by Frederick Peterson, M.D., Clinica
Professo w
York; (is
and Sur 6
plates, a

Atlas of
of Mun
turer o
Pennsyl
ment, H
figures o

Atlas of
Vienna.
Professo
Surgeon
and 217

Atlas of
Dr. Fr
Bangs,
Diseases
pital.
A. Schn

Atlas of
of Zuri
sor of (
phia.
$3.00 n

Atlas of
Vienna.
Professo
delphia,
illustrat

Atlas of
Atlas of Orth
Atlas of Ge